INFANT AND PEDIATRIC HIP

CHAPTER 28

OBJECTIVES:

- Upon completion of this presentation, Students will be able to:
  - ✓ Describe the embryology and anatomy of the neonatal hip.
  - ✓ Identify the normal hip movements.
  - ✓ Demonstrate the normal protocol and sonographic appearances of ultrasound evaluation of the neonatal hip.
  - ✓ Discuss the maneuvers used in evaluating neonatal/pediatric hips.
  - ✓ Differentiate between normal and abnormal neonatal/pediatric hips.

INDICATIONS FOR SONOGRAPHY

- Rule out developmental displacement of the hip
- Septic arthritis/joint effusion
- Proximal focal femoral deficiency

ANATOMY

- Upper leg composed of many parts to include bones and joints, nerves, arteries, superficial veins, and muscles
- Anterior surface of thigh is continuous with inguinal region of abdomen
- Posterior surface of thigh is inferior to the gluteal region
  - Back of the pelvis and hip joint

BONES AND JOINTS

- Sacroiliac joints unite two hip bones with sacral part of vertebral column
- Pubic symphysis is where two hip bones unite with each other anteriorly
- Hip bones are fusion of three separate bone
  - Ilium, ischium, and pubis

    - together these form pelvic girdle

HIP JOINT

- Articulation of head of femur with acetabulum of hip bone
- Joint is not directly palpable because it is surrounded and protected by muscles of upper thigh
- Greater trochanter of femur forms a palpable knob at side

HIP JOINT (CONT'D)

- Psoas tendon crosses center hip joint just inferior to inguinal ligament at top of femoral triangle
- Pectineus muscle is medial to tendon
- Lateral to tendon is iliacus muscle
- Gluteus minimus muscle is immediate cover for upper part of hip joint
- Piriformis muscle is immediately posterior to joint

BONES

- Rounded shape of femur and cup shape of acetabulum form "ball-and-socket" hip joint
- Acetabulum is made deeper by a rim of fibrocartilage
  - "acetabular labrum"
- Bony deficiency at lower part of acetabulum (acetabular notch) covered by band of fibrous tissue
  - "transverse ligament"

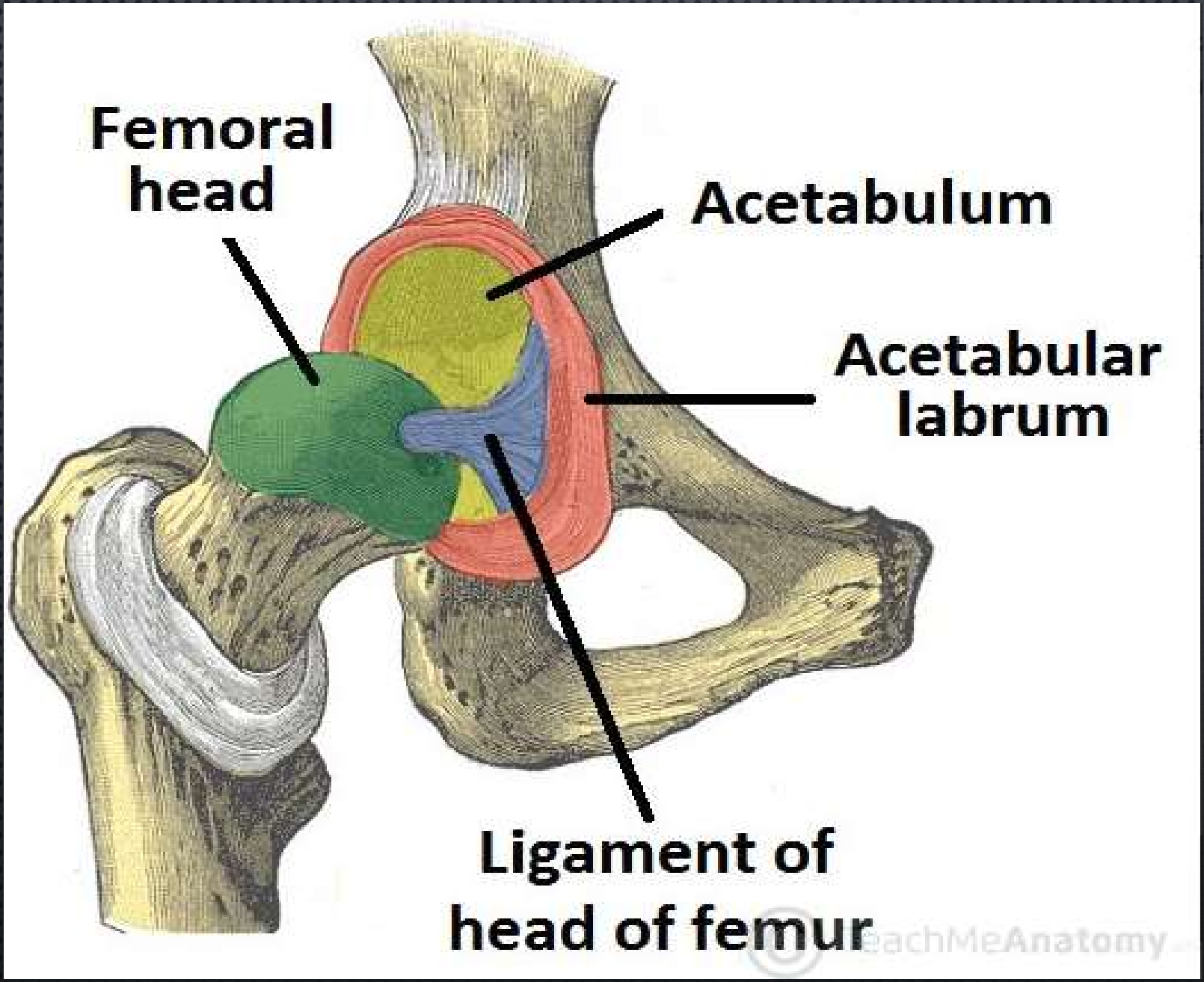
Femoral head
Acetabulum
Acetabular labrum
Ligament of head of femur
TeachMeAnatomy

MOVEMENTS OF HIP

- Somewhat limited in range from tight fit between femur and acetabulum and hip bone is immobile
- Functions/movements:
  - Flexion: bending forward
  - Extension: bending backward
  - Abduction: moving sideways outward
  - Adduction: moving sideways inward
  - Medial rotation
  - Lateral rotation

MANEUVERS

- Barlow: Hip flexed, and adducted, downward and outward pressure applied
  - If DDH- Hip "pops" out
- Ortolani: Hip flexed and abducted
  - If DDH- Hip "clunks" back in


BARLOW
MANEUVERS FOR DEVELOPMENTAL DYSPLASIA OF THE HIP
ORTOLANI
HE DID IT AGAIN. CALL DR. O.
Dr. B
IT'S-A BACK IN!
BRAVO!
Dr. O
EXAMINER ADDUCTS THE HIP WHILE APPLYING A POSTERIOR FORCE ON THE KNEE TO PROMOTE DISLOCATION
EXAMINER ABDUCTS THE HIP WHILE APPLYING AN ANTERIOR FORCE ON THE FEMUR TO REDUCE THE HIP JOINT

SONOGRAPHIC EVALUATION

- Sonography has advantage over conventional radiography to image fine detail of neonatal hip
  - Cartilaginous femoral head
  - Cartilaginous acetabular rim
  - Labrum

- Size, shape, and position of femoral head can be assessed sonographically well before bones are ossified enough to be seen on radiography
- Motion of femoral head in acetabulum under stress also can be tested
- Shape of acetabulum can be evaluated

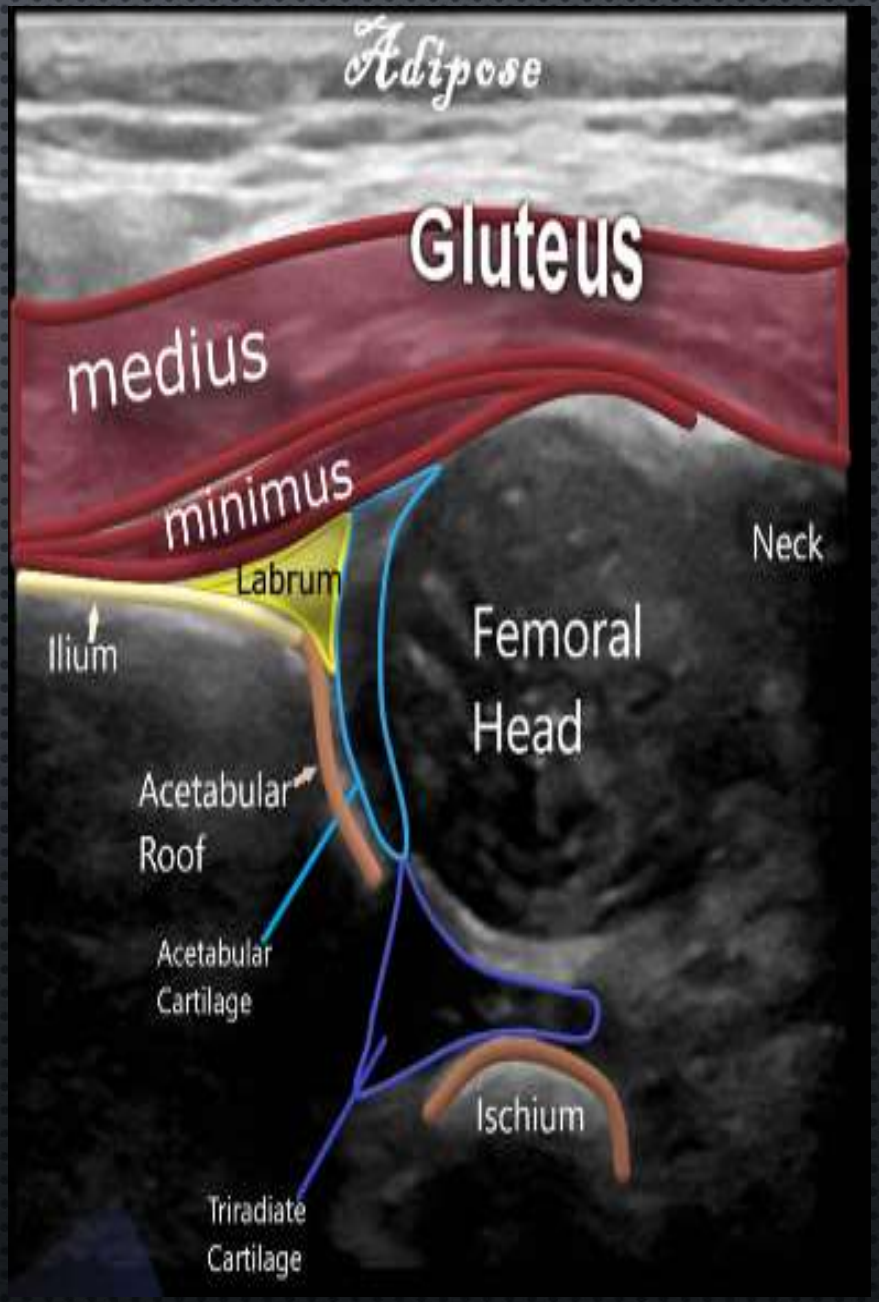
Adipose
Gluteus
medius
minimus
Neck
Labrum
Ilium
Femoral
Head
Acetabular
Roof
Acetabular
Cartilage
Ischium
Triradiate
Cartilage

- Sonography can be performed until femoral head ossifies
- Ossification of femoral head begins between 2 and 8 months
  - Occurs earlier in girls than boys
  - Often complete by 1 year
- Once femoral head is completely ossified
  - Difficult to obtain adequate sonographic images - artifact

Coronal

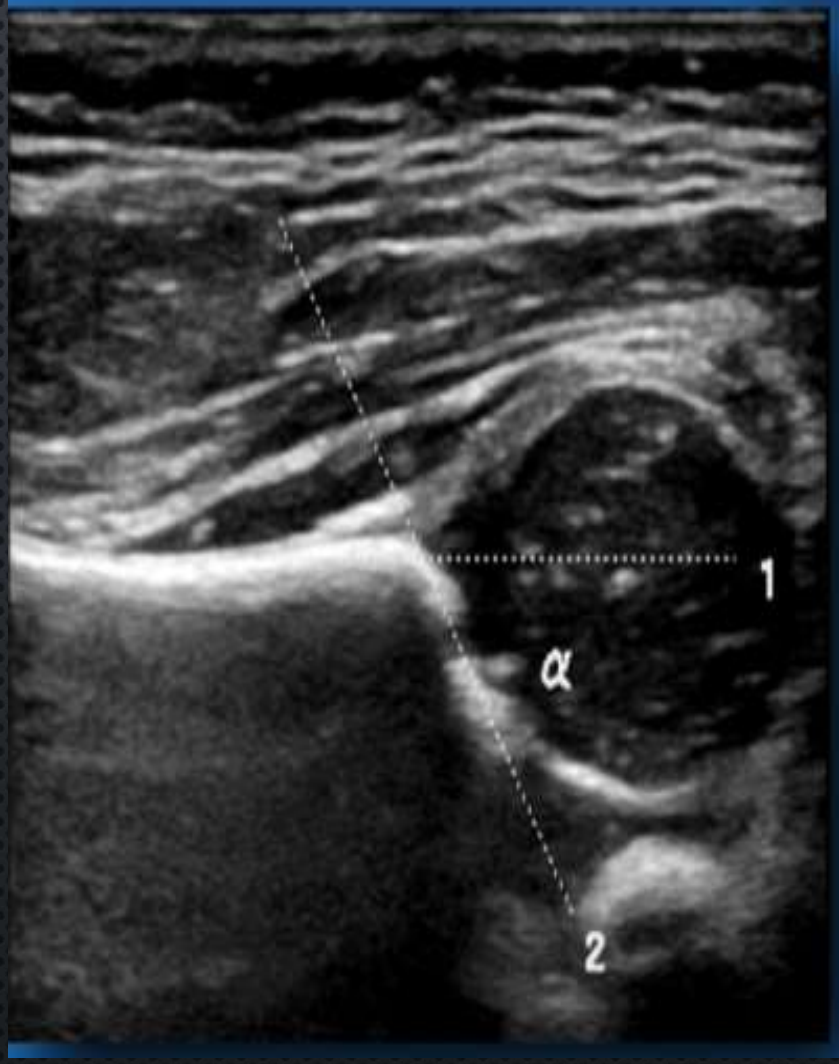

Transverse

Adduction

Abduction

CENTRAL OSSIFICATION POINT

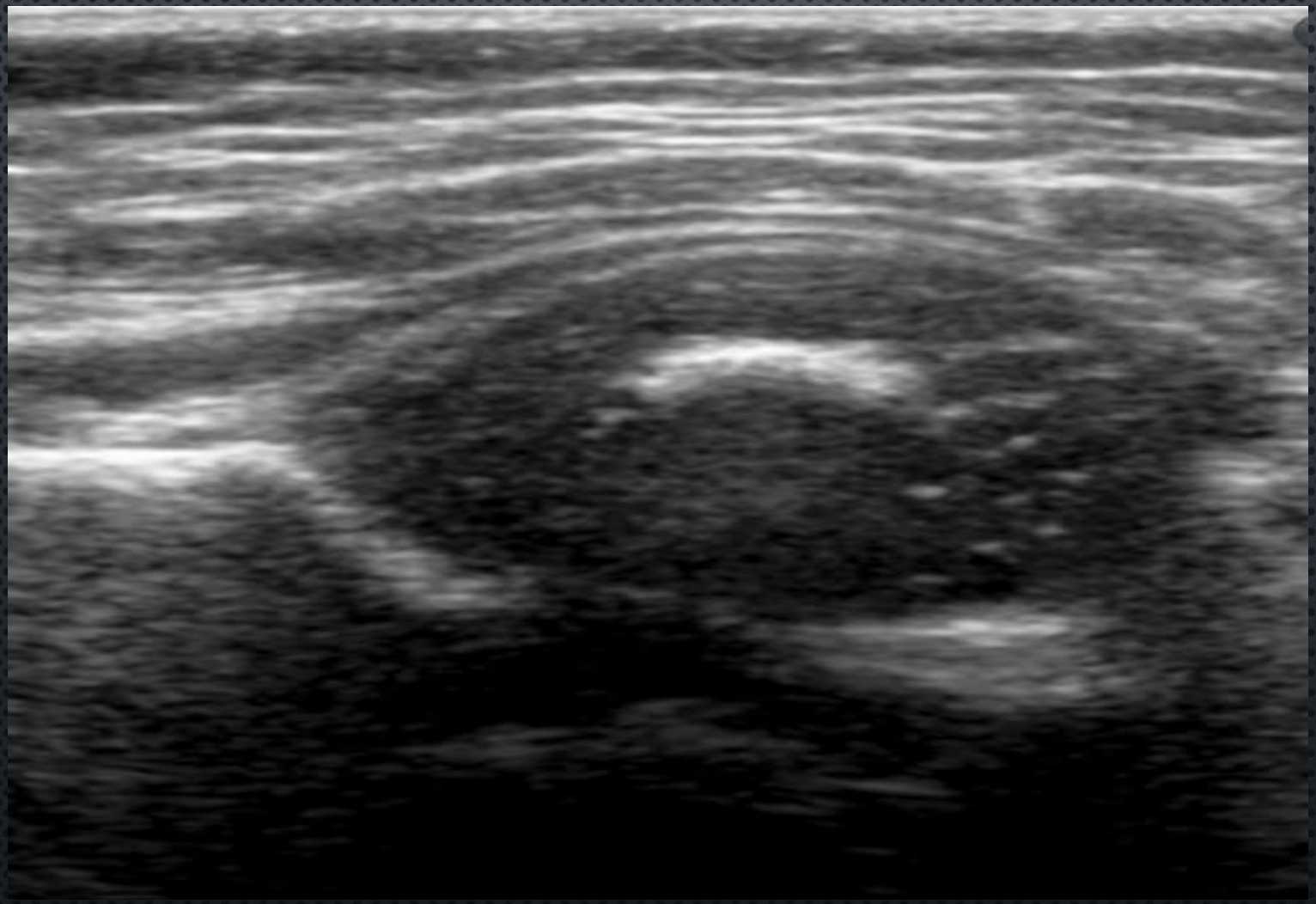

SONOGRAPHIC TECHNIQUE

- Linear array transducer
- For average weight neonates up to three months
  - 7.5 - 9.0 MHz transducer
- Infants to age 7 months
  - 5 – 7.5 MHz transducer
- After 7 months
  - 3-MHz transducer
- Premature infant
  - 12 – 15 MHz transducer

SONOGRAPHIC PROTOCOL

- Basic hip anatomy is imaged in four different views:
  1. coronal/neutral
  2. coronal/flexion
  3. transverse/flexion
  4. transverse/neutral

GRAF'S ALPHA AND BETA ANGLES

- Graf used a series of lines and angle measurements to evaluate morphology of acetabulum:
  - Baseline connects osseous acetabular convexity to point where joint capsule and perichondrium unite
  - Inclination line connects osseous acetabular convexity to labrum
  - Acetabular roof line connects lower edge of medially acetabular roof to osseous acetabular convexity

- Alpha and beta angles are measured based on preceding lines
- Alpha angle is angle between baseline and acetabular roof line and represents osseous acetabulum
- Alpha angle is normally greater than 60 degrees
- Beta angle is angle between baseline and inclination line

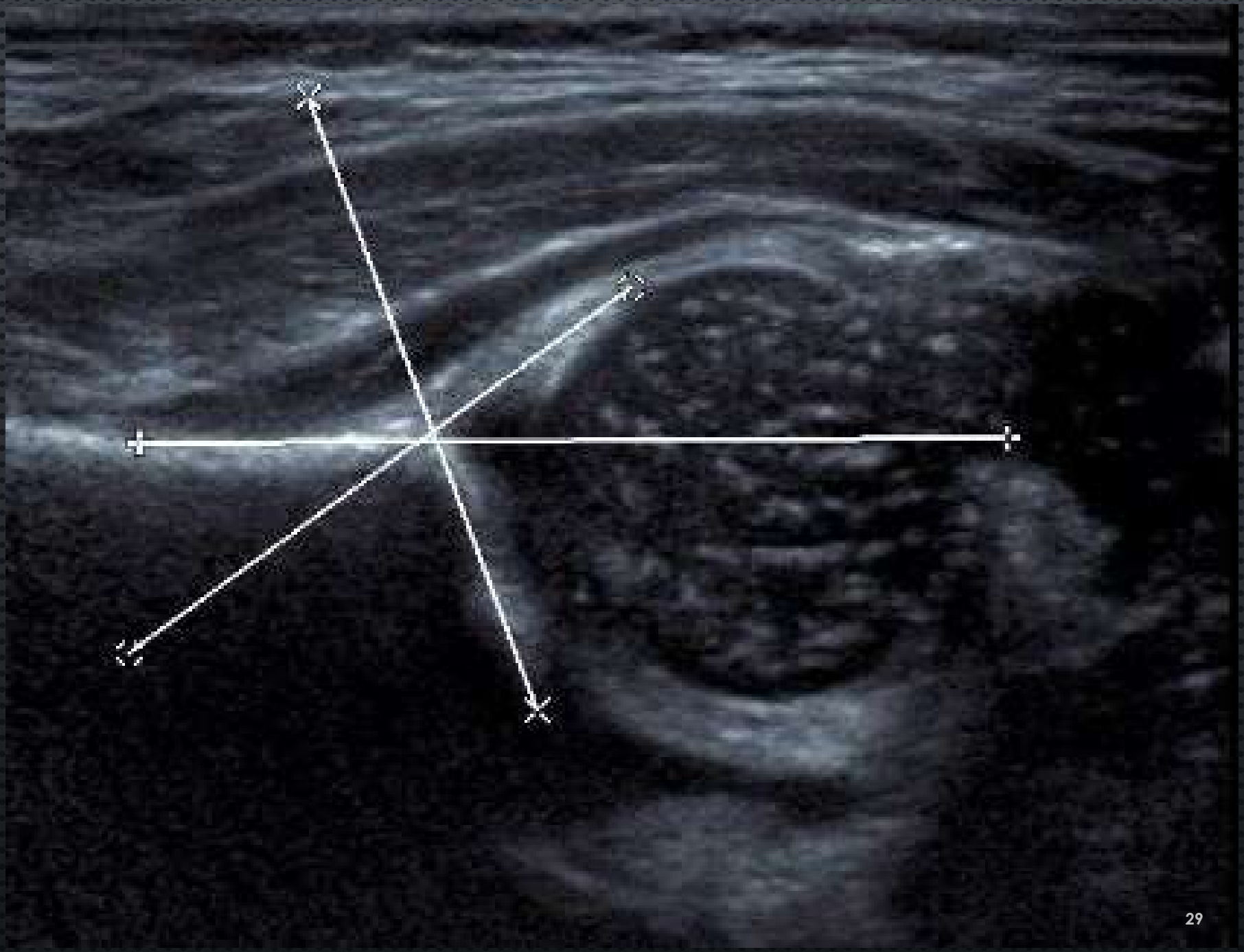

- Beta angle evaluates formation and size of cartilaginous acetabulum
  - Normally less than 55 degrees
- Alpha angle reflects changes in osseous portion of acetabulum
  - Occurs gradually
- Beta angle reflects changes in cartilaginous acetabulum
  - Occurs more quickly than changes in osseous acetabulum
  - May be more sensitive than alpha angle

CORONAL/NEUTRAL VIEW

- Performed with infant in supine position from lateral aspect of hip joint
  - ❖ Plane of transducer oriented coronally with respect to hip joint
- Femur is stabilized with a flexion
- Alpha and beta angles may be measured from this view
- A stability test can be performed in this view by gently pushing and pulling the infant's leg

CORONAL/NEUTRAL VIEW (CONT'D)

- Normal coronal/neutral view
  - Femoral head is resting against bony acetabulum
- When hip becomes subluxed or dislocated
  - Femoral head gradually migrates laterally and superiorly with progressively decreased coverage of femoral head

HIP DYSPLASIA

- Acetabular roof is irregular and angled
- Labrum is defected superiorly and becomes echogenic and thickened
- Hip is frankly dislocated
  - Labrum may be deformed
- Combination of deformed labrum and fibrofatty tissue prevents hip from being reduced

Coronal/Flexion View

- Transducer maintained in lateral position while hip is moved into a 90-degree angle of flexion
- Curvilinear margin of femoral shaft body is identified anterior to femoral head
- In midportion of acetabulum, Femoral head is surrounded by echoes from bony acetabular components

CORONAL/FLEXION VIEW (CONT'D)

- Superiorly lateral margin of iliac bone is seen and transducer position should be adjusted so that it becomes a straight horizontal line on monitor
- Normal hip gives appearance of a ball-on-a-spoon in the mid acetabulum
  - Femoral head is the ball
  - Acetabulum forms the spoon
  - Iliac line is handle

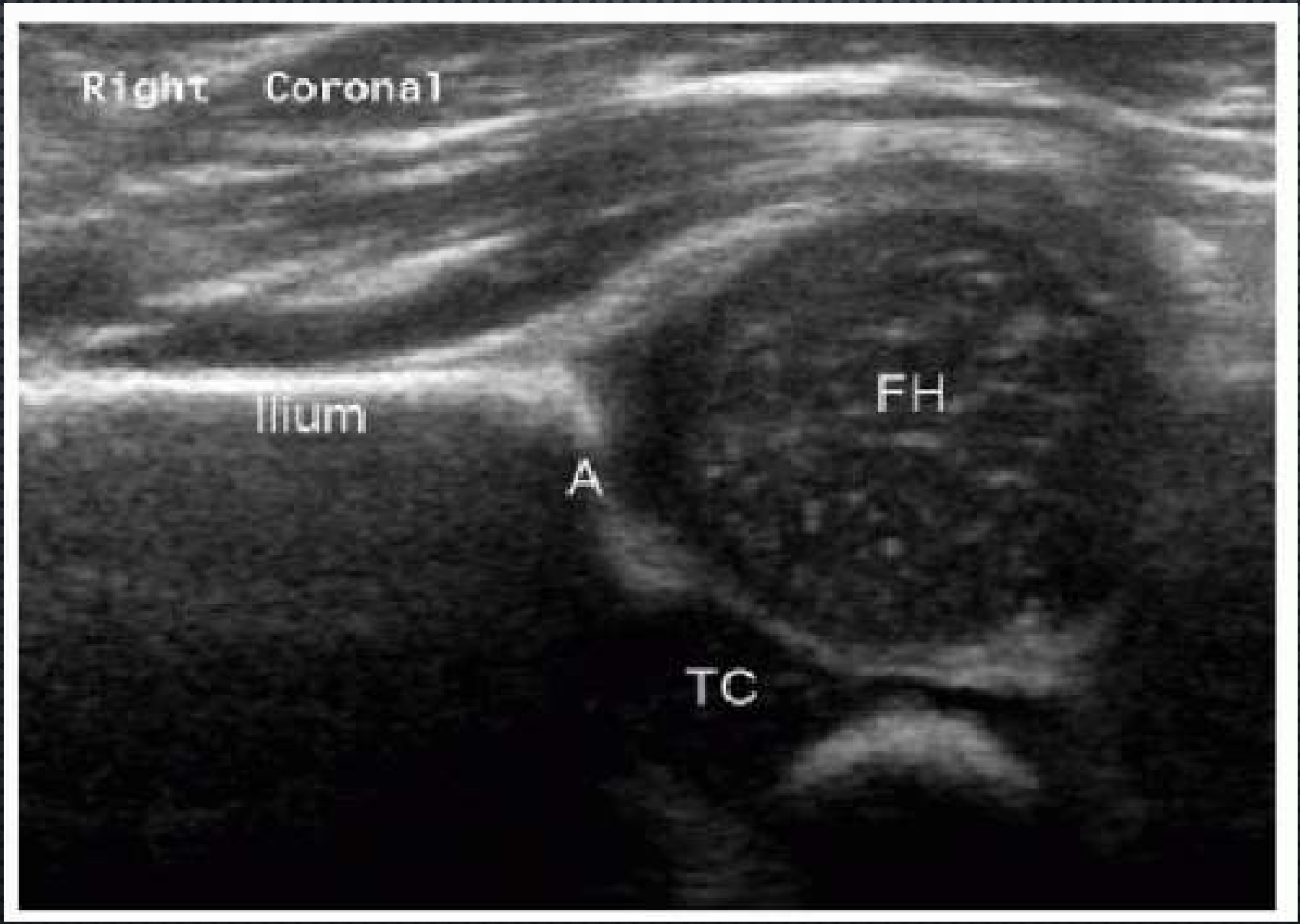
Right Coronal
Ilium
A
FH
TC

TRANSVERSE/FLEXION VIEW

- Transverse is rotated 90 degrees and moved posteriorly into a posterolateral position over hip
- Echoes from bony acetabulum appear posteriorly to femoral head
- Normal hip
  - U configuration is produced

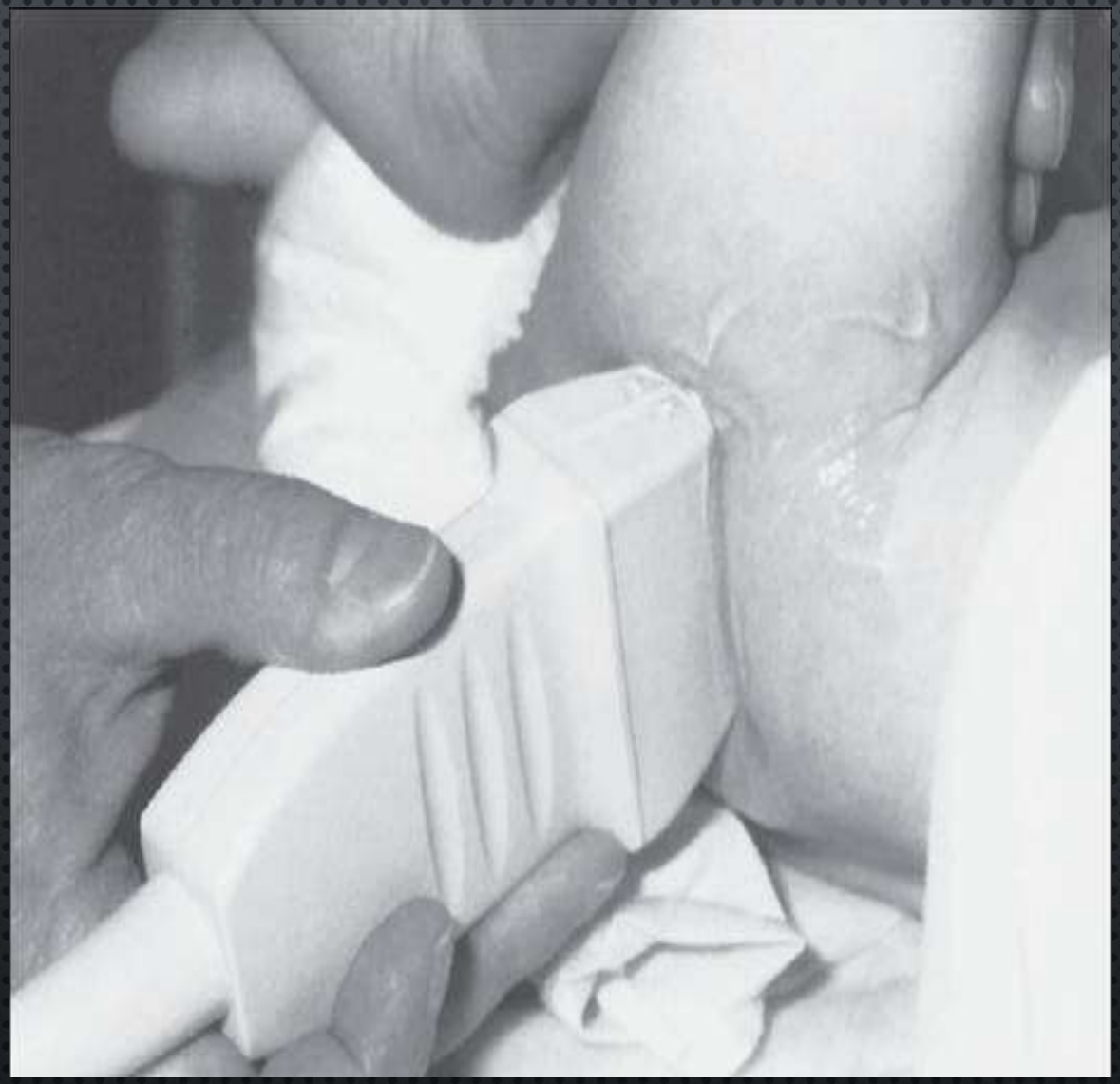

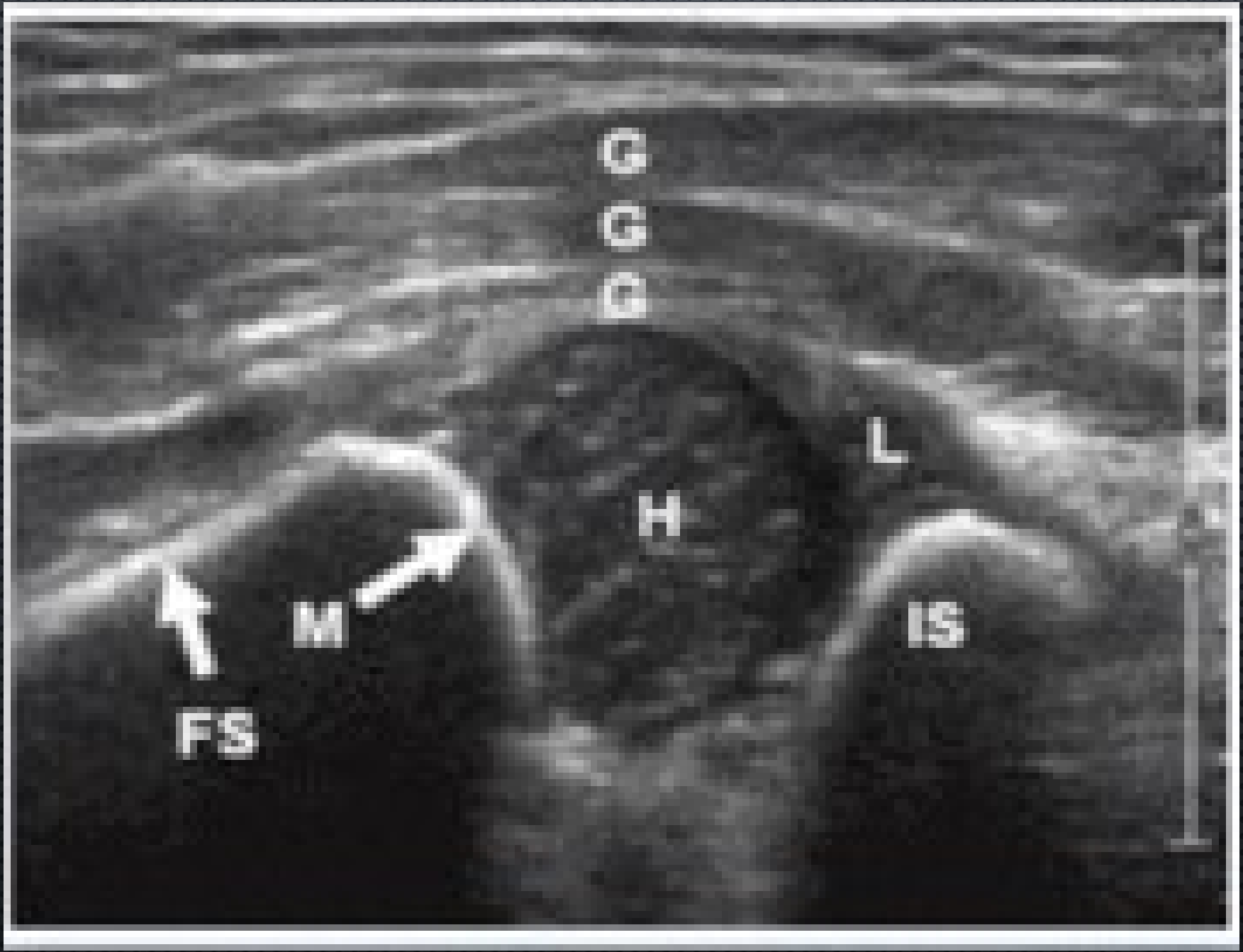
C
C
C
L
H
M
IS
FS

TRANSVERSE/NEUTRAL VIEW

- Leg in a neutral position
- Transducer is now horizontal to acetabulum from lateral aspect of hip
- Plane passes through femoral head into acetabulum at center of cartilage

TRANSVERSE/NEUTRAL VIEW (CONT'D)

- Images represent parts of a flower:
  - Femoral head – flower
  - Echoes from ischium posteriorly and pubis anteriorly – leaves at its base
  - Echoes that pass through cartilage into area of acoustic shadowing created by osseous structures - stem

- https://www.youtube.com/watch?v=T57sN3SGAes

PATHOLOGY OF HIP

DEVELOPMENTAL DYSPLASIA OF THE HIP (DDH)

- AKA. DEVELOPMENTAL DISPLACEMENT OF THE HIP
- ENCOMPASSES A SPECTRUM OF PATHOLOGIES:
  - SUBLUXATED
  - DYSPLASTIC
  - DISLOCATABLE
  - DISLOCATED HIPS

Dislocation of the hip

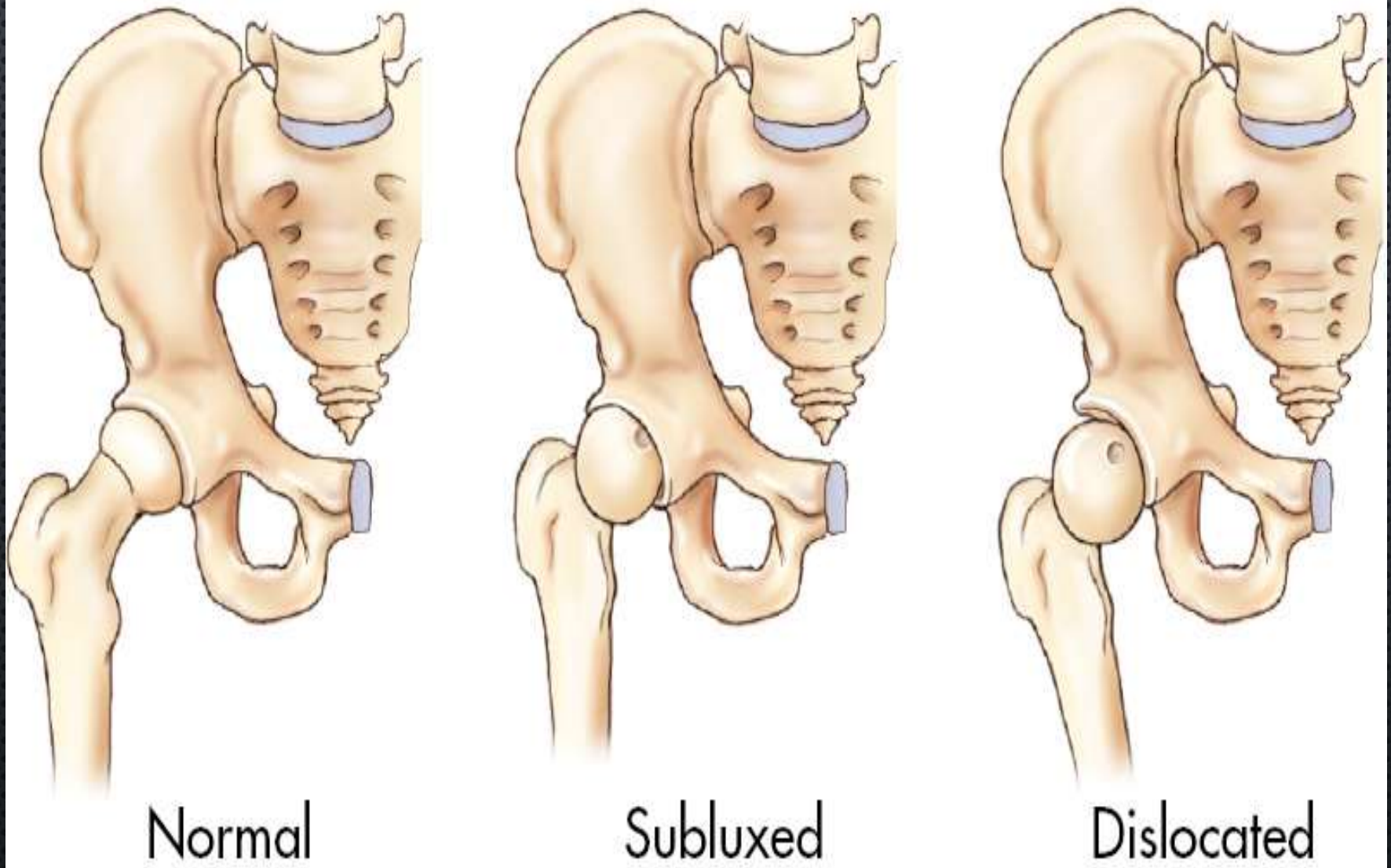

Copyright © 2012, 2006, 2001, 1995, 1989, 1983, 1978 by Mosby, an imprint of Elsevier Inc.

CLINICAL EXAMINATION

- With visual inspection, the dislocated hip shows asymmetric skin folds and shortening of the affected thigh.
- The knee is lower in position on the affected side when the patient is supine and the knees are flexed, known as the **Galeazzi sign**.

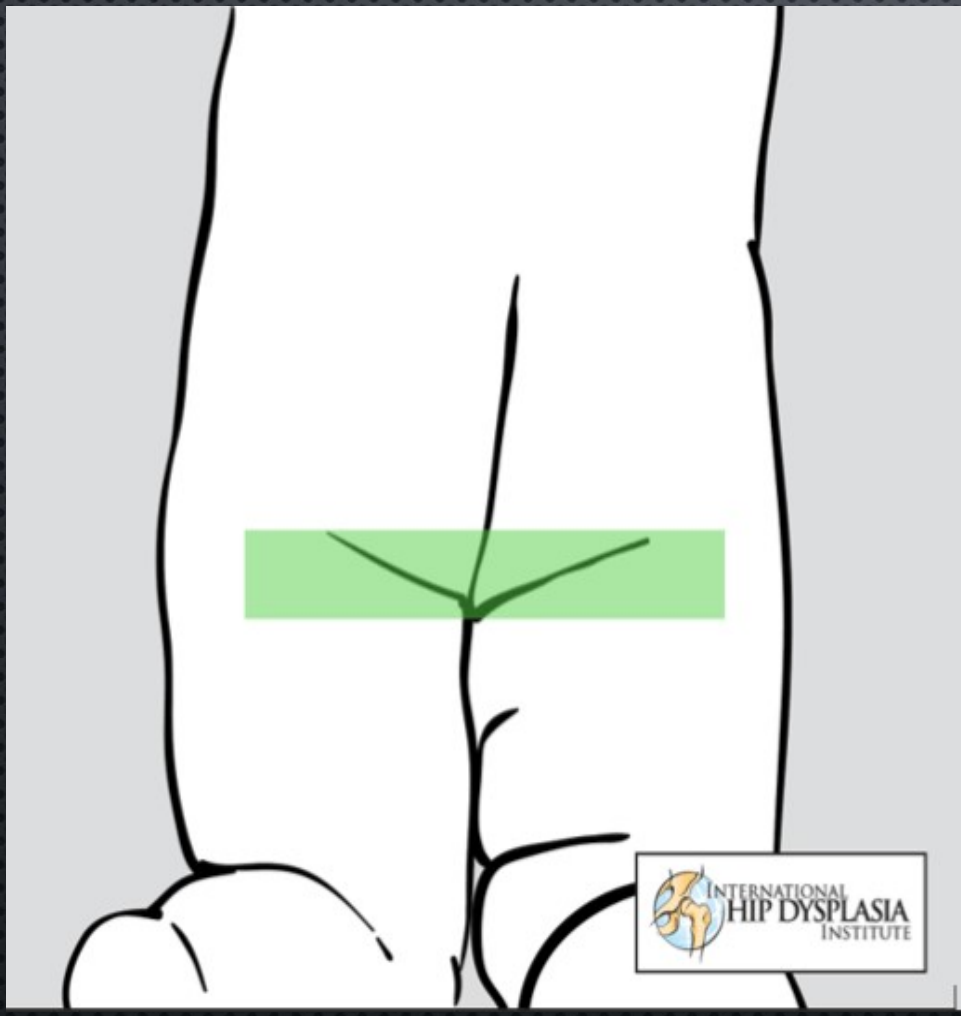
INTERNATIONAL
HIP DYSPLASIA
INSTITUTE

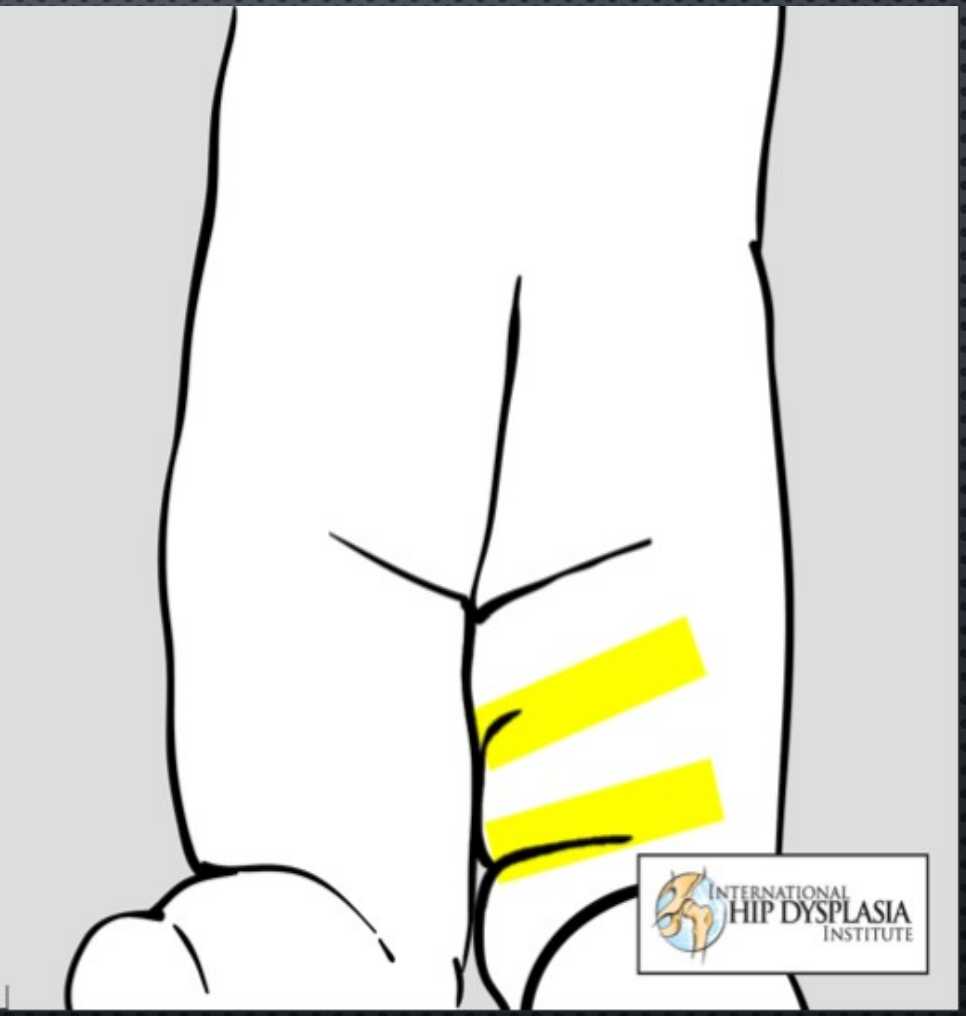
INTERNATIONAL
HIP DYSPLASIA
INSTITUTE

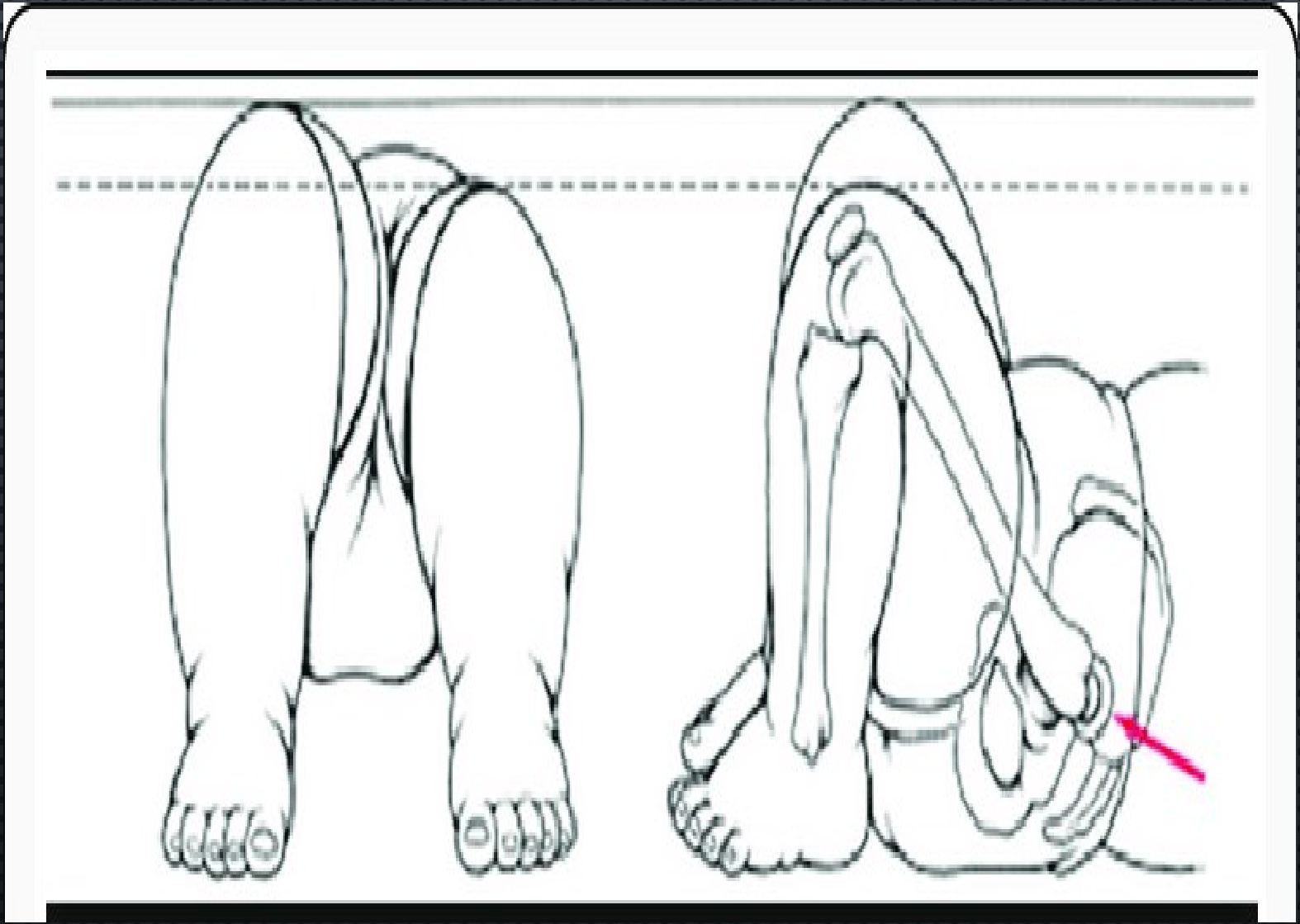

CLINICAL EXAMINATION (CONT'D)

- Hip instability may resolve after 4-6 weeks, due to waning maternal hormones.

- Neonates with a slightly positive or inconclusive physical exam, and newborns with a risk factor for DDH should be examined with sonography after this period to reduce false-positive results.

DISLOCATION

- Neonatal hip dislocation can be due to:
  - Acquired
  - Trauma
  - Neuromuscular diseases
  - Teratogenic
    - ❖ Occur in utero – associated with neuromuscular disorders
  - Developmental
    - ❖ Was formerly known as congenital hip dysplasia
    - ❖ Replaced by developmental displacement of the hip (DDH)

DISPLACEMENT

- Relatively common congenital abnormality
- Before sonography, Plain film radiographs were used to confirm diagnosis of a dysplastic hip
- Sonography has now replaced radiography in that it:
  - Does not require neonate to be sedated
  - Ionizing radiation is not used
  - Soft tissues are well defined

DISPLACEMENT - DDH (CONT'D)

- Multiple risk factors may contribute
  - firstborn child (females > males)
  - Left hip most commonly affected
  - Breech birth
  - Low birth weight
  - Family history
  - Intrauterine conditions

DISPLACEMENT- DDH (CONT'D)

- Other risk factors:
  - Maternal hypertension
  - Fetal growth restriction
  - Oligohydramnios
  - Premature rupture of membranes
  - Prolonged gestation
  - Increased birth weight
  - Potter's syndrome
  - Neonatal intensive care

SONOGRAPHIC TECHNIQUE FOR DEVELOPMENTAL DISPLACEMENT OF HIP

- Two sonographic techniques:
  1. Static (morphologic)
  2. Dynamic
     - More commonly used and preferred
- Static or morphologic technique:
  - Image is acquired in coronal plane at mid acetabular level

    - Includes femoral head, acetabulum, labrum, and iliac bone as it meets triradiate cartilage

    - Produces a coronal image which has a configuration of a lazy Y

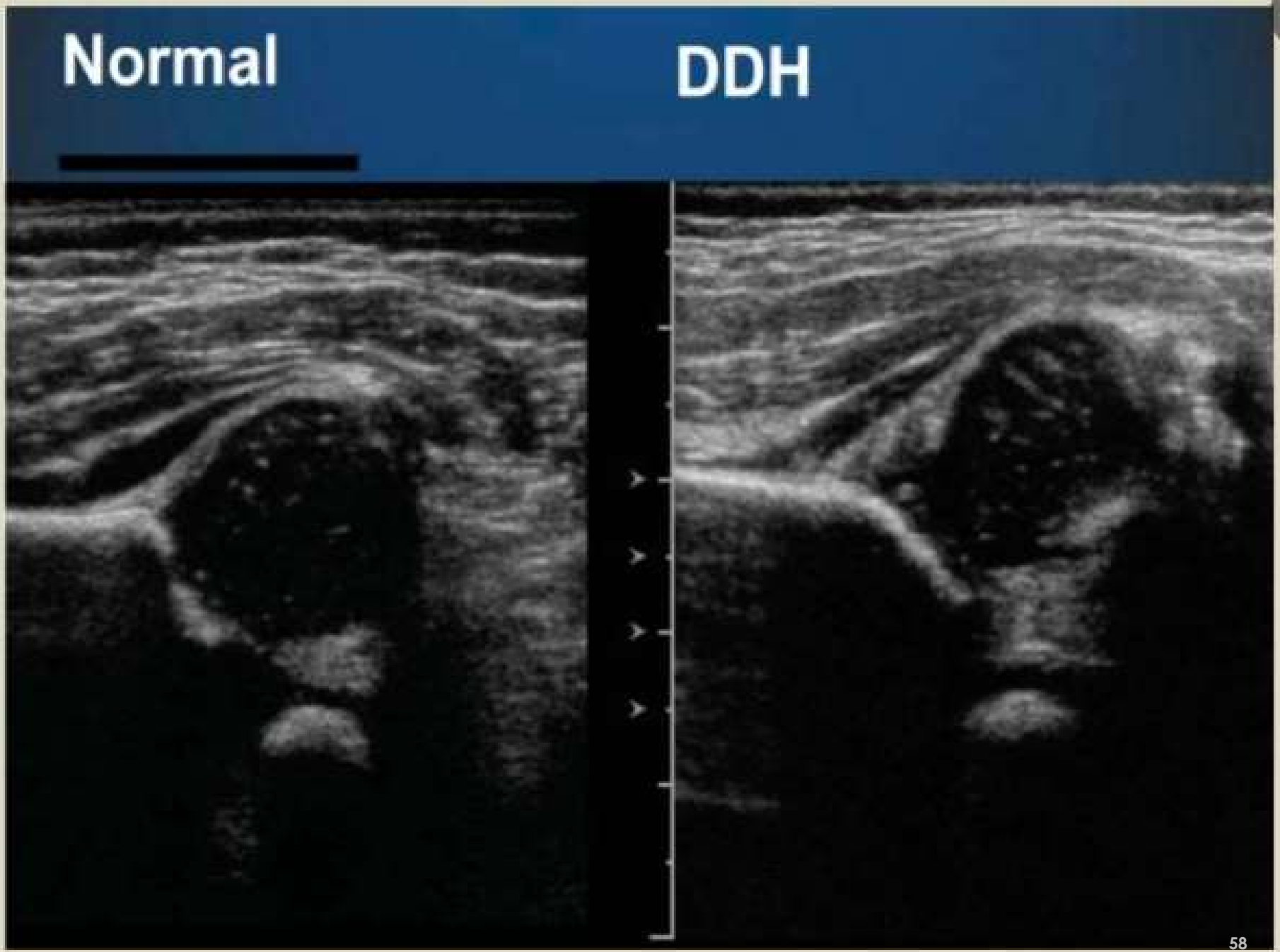
Normal
DDH

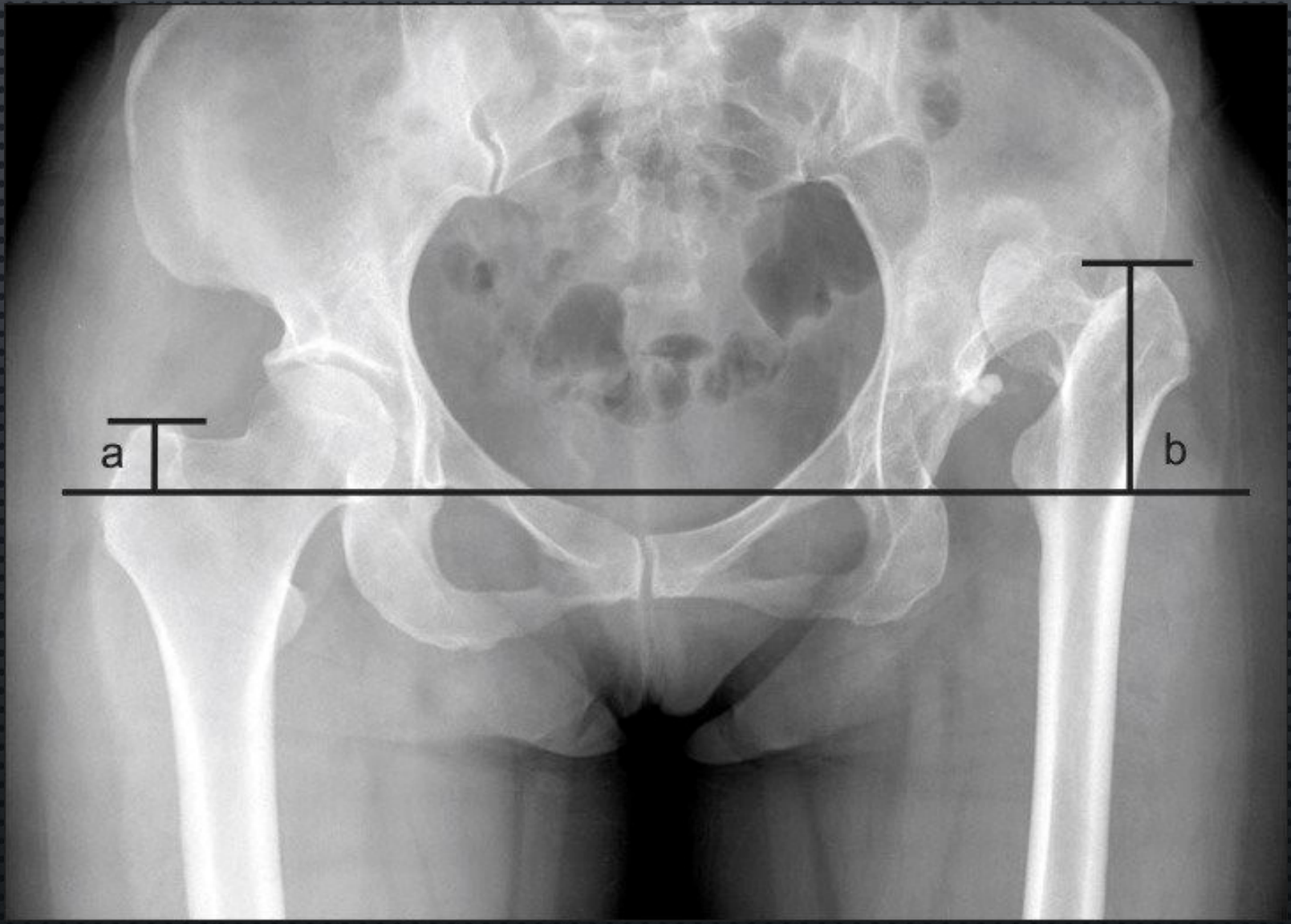

https://www.researchgate.net/figure/In-cases-of-unilateral-developmental-dysplasia-of-the-hip-leg-length-discrepancy-was_fig4_256453009

Graf's Classification of Neonatal Hips

- According to Graf (four types of displacements)
- Classified according to its alpha and beta angles:
  - Type I hip
    - Normal hip
    - has an alpha angle of greater than 60 degrees
  - Type II hip
    - Has an alpha angle between 43 and 60 degrees
  - Type III hip
    - Has an alpha angle of < 43 degrees and a beta angle >77 degrees
  - Type IV hip
    - Has an alpha angle < 43 degrees and the beta angle is immeasurable

DYNAMIC TECHNIQUE

- Currently used in most clinical situations today
- All scanning is performed from lateral or posterolateral aspect of hip
- Hip is imaged in orthogonal planes:
  - Coronal (longitudinal)
  - Transverse (axial)
- With the hip flexed, the femur is moved through a range of abduction and adduction, with stress views performed in the flexed position

TREATMENT OF DDH

- The initial treatment of uncomplicated DDH is closed reduction
  - ❖ accomplished either by placing two diapers on the neonate or by using a spica cast, brace, or Pavlik harness.
- The hip should be positioned in flexion, with abduction and external rotation.

PAVLIK HARNESS

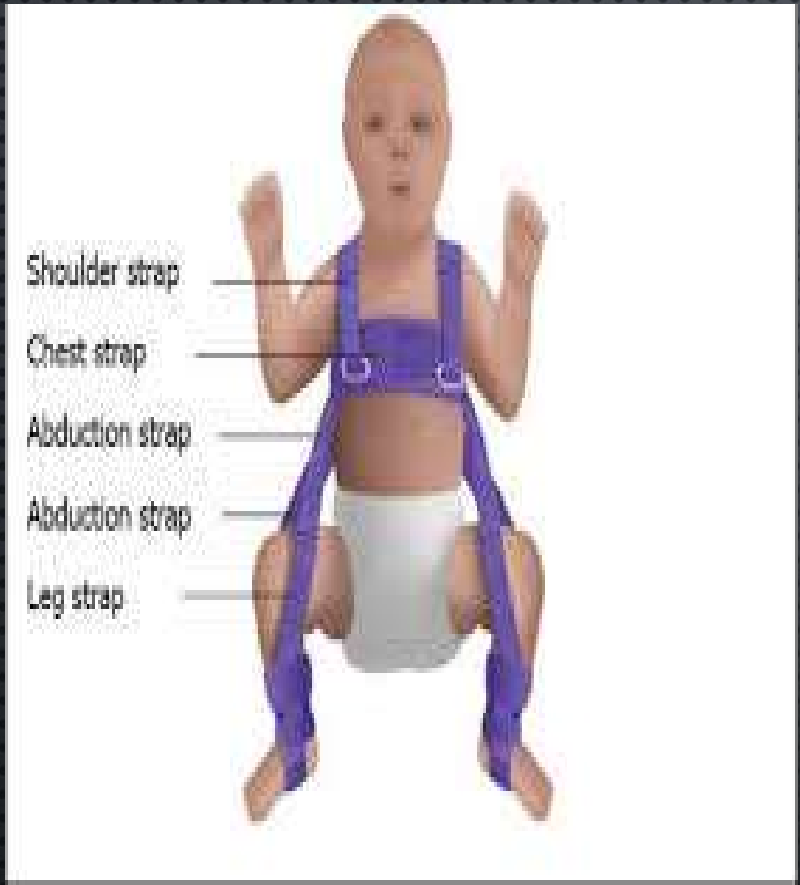

https://thediyplaybook.com/infant-hip-dysplasia/

ANY QUESTIONS???

REVIEW

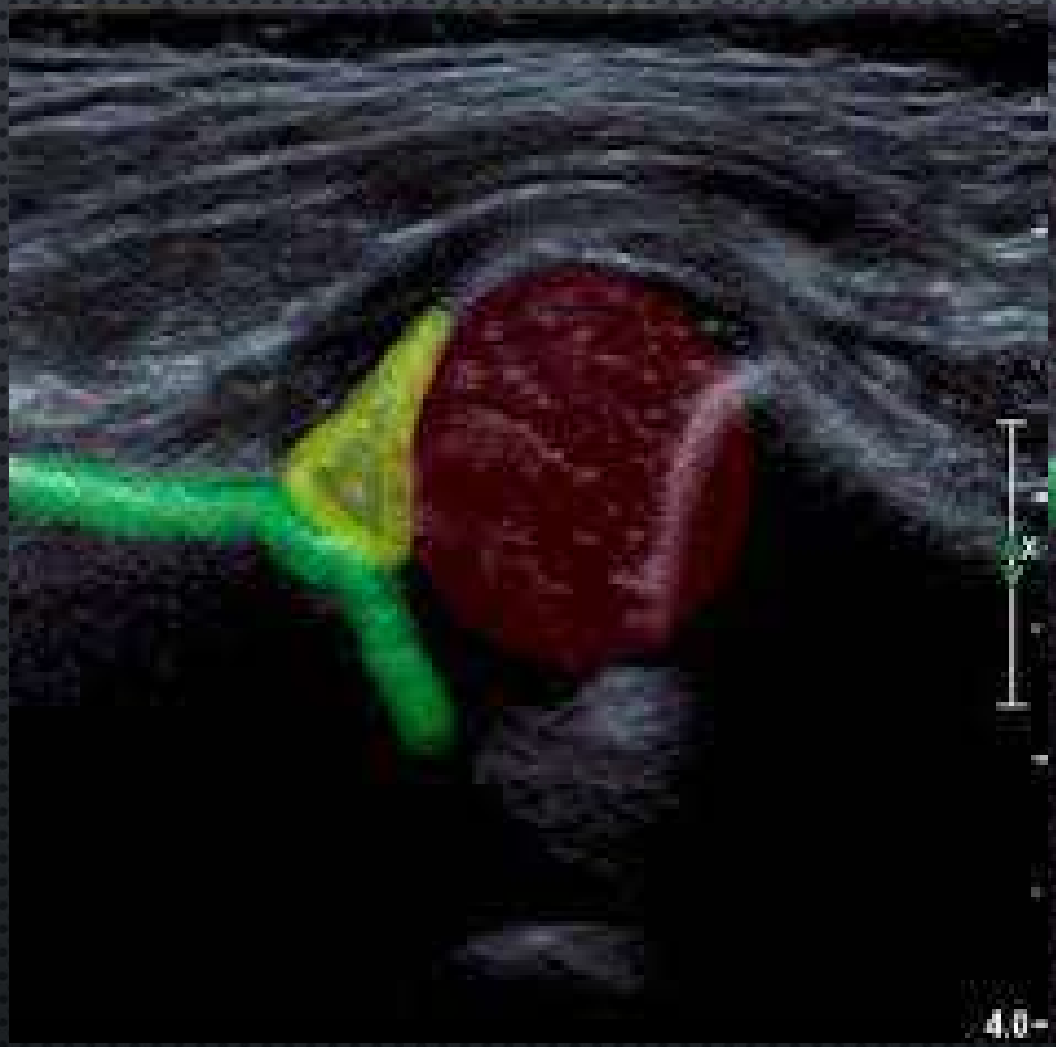
4.0

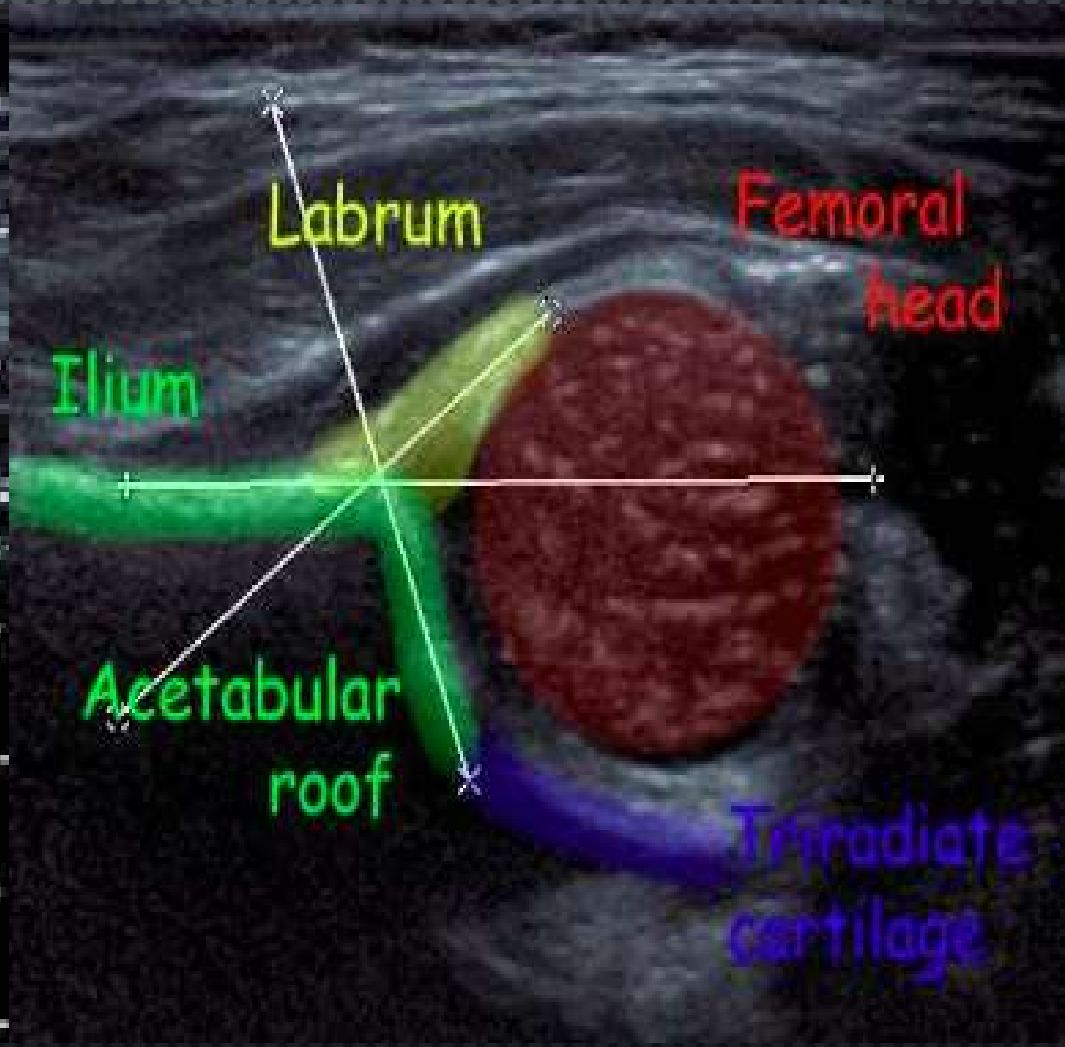
Labrum
Femoral head
Ilium
Acetabular roof
Triradiate cartilage

https://youtu.be/SoUWHKbBHzQ?si=Wk8ITJ8XoDGrBxJR