Reading Hospital
School of Health Sciences
Medical Imaging Program

Fall 2021

Abdomen Radiography

Merrill's Volume 1 Page 129

1

Abdominal Pelvic Cavity

Consists of:

- Abdominal Cavity
  - Large, Superior portion
- Pelvic Cavity
  - Smaller, inferior portion

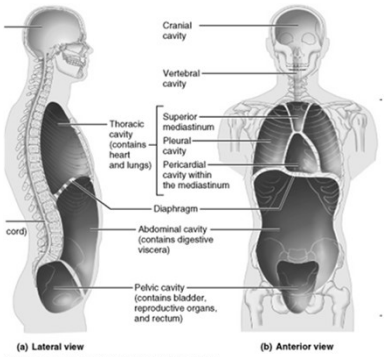

Cummings, an imprint of Addison Wesley Longman, Inc.

2

Abdominal Cavity

Abdominal Cavity:

- Diaphragm to superior aspect of bony pelvis
- Consists of:
  - Stomach
  - Small and large intestines
  - Liver
  - Gallbladder
  - Spleen
  - Pancreas
  - Kidneys

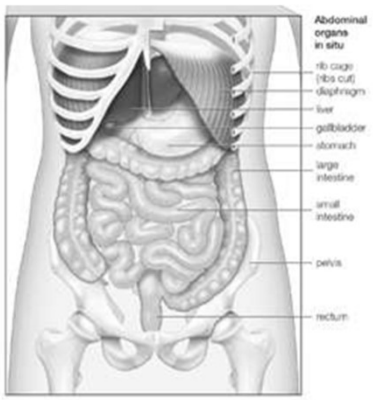

3

Pelvic Cavity

Pelvic Cavity:

- Lies within margins of bony pelvis
- Contains:
  - Rectum and sigmoid regions of colon
  - Urinary bladder
  - Reproductive organs

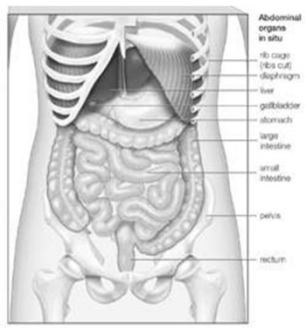

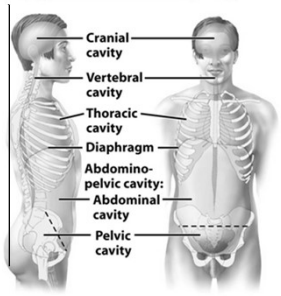

(a) Right lateral view (b) Anterior view

Figure 1-9 part 1 Anatomy and Physiology: From Science to Life
© 2006 John Wiley & Sons

4

Pelvic Cavity

Notes of interest for abdomen positioning:

- Iliac Crest
- ASIS
- Pubic symphysis

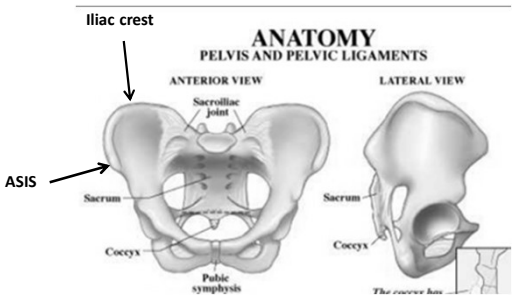

5

Abdominal Peritoneum

- Encloses abdominopelvic cavity
- Double walled membrane:
  - Parietal Peritoneum - Outer portion (lines cavity)
  - Visceral Peritoneum - Inner portion (surrounds organs)
- Peritoneal cavity – In between; contains fluid.

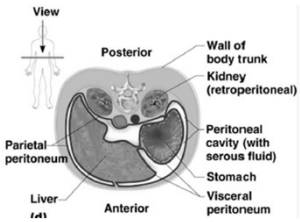

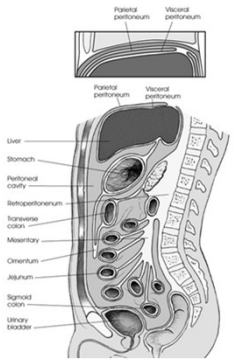

6

Abdominal Peritoneum

Mesentery and Omenta – folds which support the organs in position

- Mesentery - Assist in attachment of the organs to the posterior abdominal wall
- Omenta – Protective 'drape' (part of mesentery) hangs from the stomach and attaches to the colon

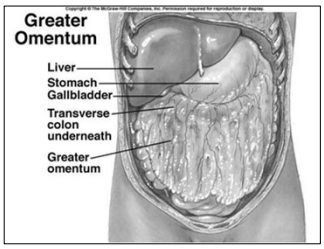

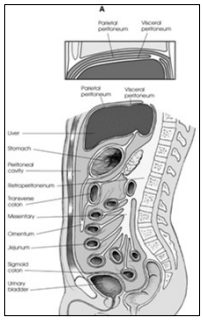

7

Abdominal Peritoneum

Retroperitoneum – Cavity behind the peritoneum which includes:

- Kidneys
- Pancreas

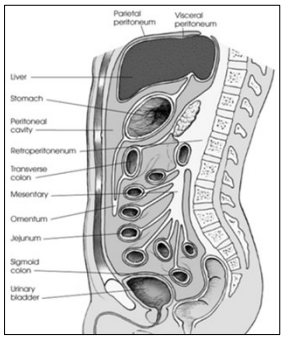

Retroperitoneum – kidneys and pancreas

8

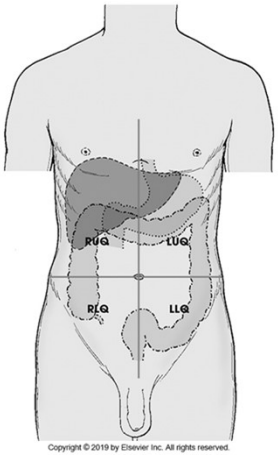

Abdominal Quadrants

9

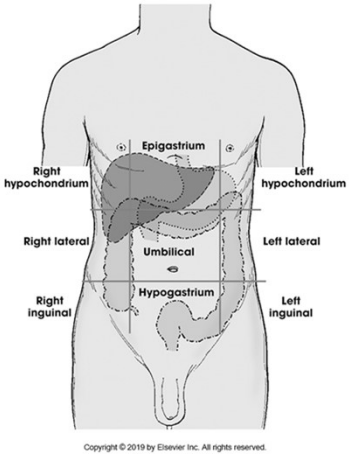

Abdominal Regions

10

Organ Locations

- Right kidney usually lies lower than left kidney.
- Right flexure of colon usually lies lower than left flexure.
- The liver pushes down the organs on the right side.

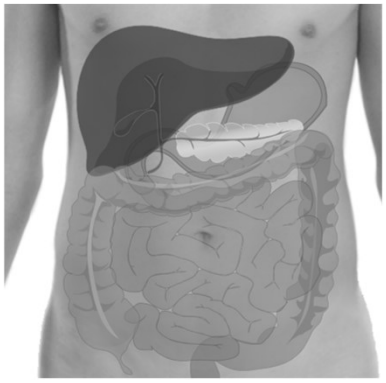

11

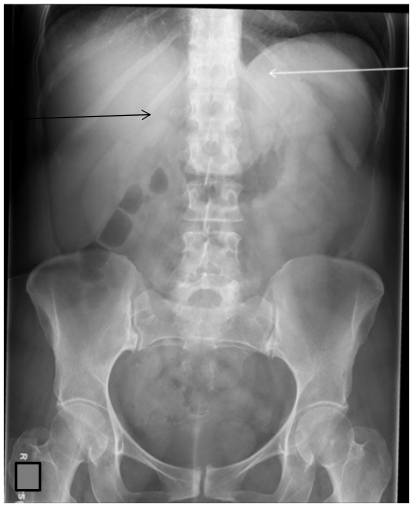

12

13

Organ Locations

- The liver pushes up on the diaphragm on the right side

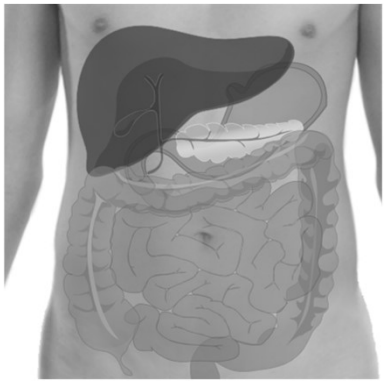

14

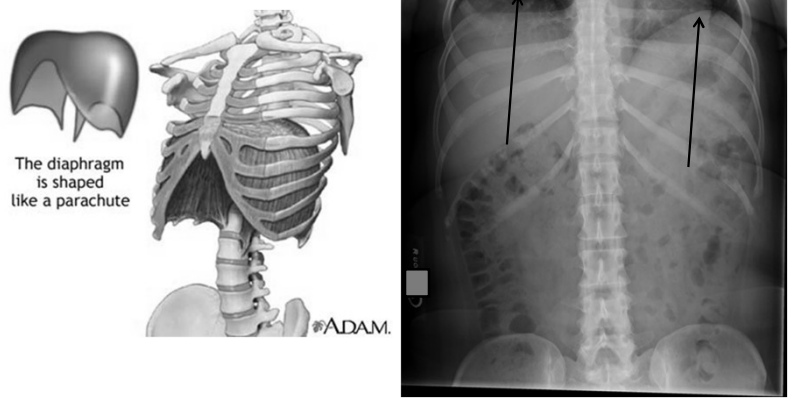

15

Psoas Muscles

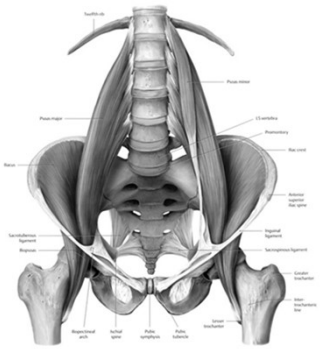

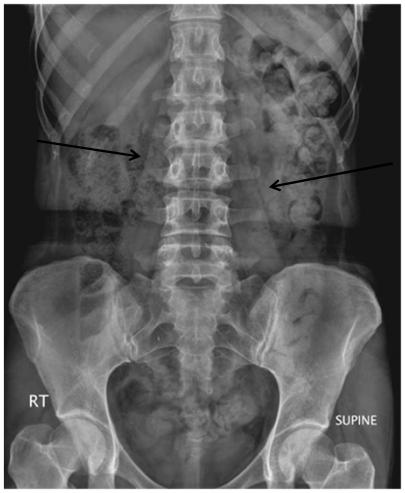

16