Reading Hospital School of Health Sciences
Medical Imaging Program

MI 133: Clinical Seminar II
Ankle & Tibia/Fibula

Merrill's Volume 1, Chapter 7
2021

1

Ankle

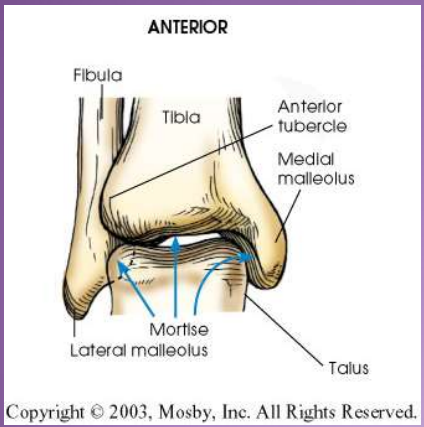

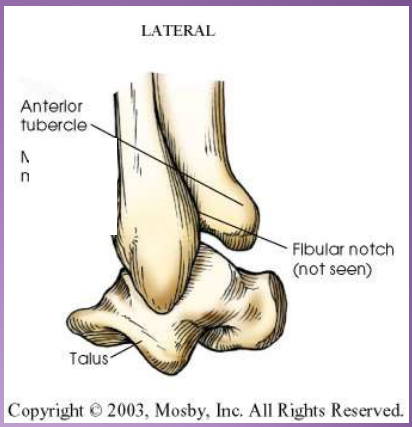

2

Bone Types and Joint Classifications

Joint	Tissue	Type	Movement
Ankle Mortise			
Talofibular	Synovial	Hinge	Freely movable
Tibiotalar	Synovial	Hinge	Freely movable
Tibiofibular			
Proximal	Synovial	Gliding	Freely movable
Distal	Fibrous	Syndesmosis	Slightly movable
Knee			
Femorotibial	Synovial	Hinge modified	Freely movable

Talus = irregular bone type
Tibia and Fibula = long bone type

Merrills Volume I, page 282

3

Tibiotalar Joint

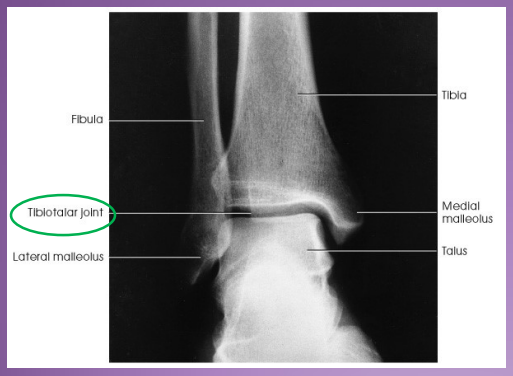

4

Talofibular Joint

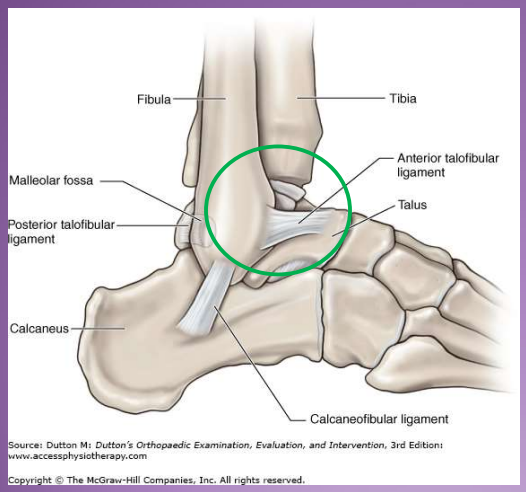

5

Tibia/Fibula

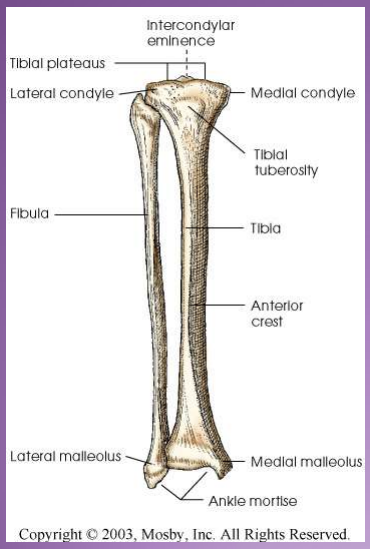

Anterior

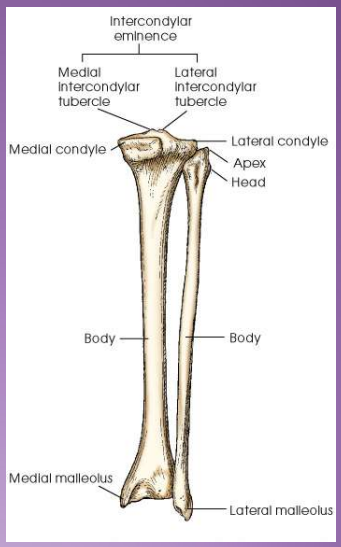

Posterior

6

Tibia/Fibula

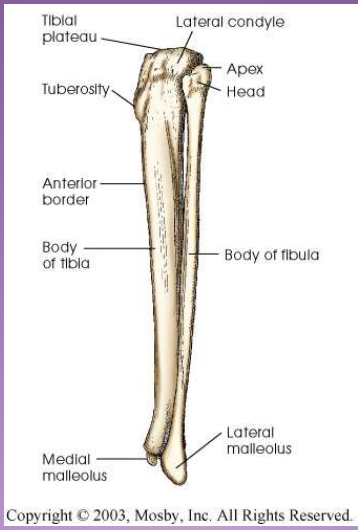

Lateral

7

Tibiofibular Joints

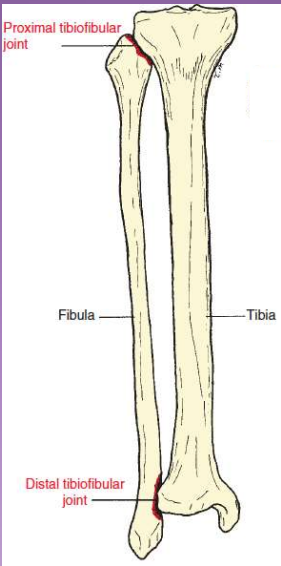

8

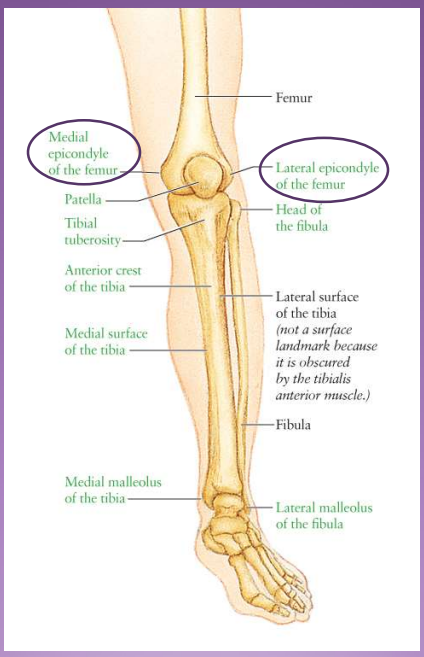
Femur
Medial epicondyle of the femur
Lateral epicondyle of the femur
Patella
Head of the fibula
Tibial tuberosity
Anterior crest of the tibia
Lateral surface of the tibia (not a surface landmark because it is obscured by the tibialis anterior muscle.)
Medial surface of the tibia
Fibula
Medial malleolus of the tibia
Lateral malleolus of the fibula

9

B
R
Copyright © 2003, Mosby, Inc. All Rights Reserved.

Patella
Femoral condyles
Tibia
Fibula
R
Medial malleolus

10