MATERNAL911®

Operative Vaginal Delivery

Click the next button to continue...

Copyright © 2020 Shelly Betancourt and Michelle Becher

All rights reserved. No part of this publication may be reproduced, distributed, or transmitted in any form or by any means, including photocopying, recording, or other electronic or mechanical methods, without the prior written permission of the publisher, except in the case of brief quotations embodied in critical reviews and certain other noncommercial uses permitted by copyright law. For permission requests, write to the publisher at the address below.

Maternal 911 Education Systems, LLC
475 West Center St.
Ithaca, MI 48847
www.maternal911.com

Maternal 911 and Maternal 911 in Action contains information designed as an educational resource to aid practitioners in providing obstetric care and the use of this information is voluntary. This information should not be considered as inclusive of all proper treatments or methods of care or as a statement of the standard of care. It is not intended to substitute for the independent professional judgement. Maternal 911 reviews the publication regularly, but may not reflect the most recent evidence.

Maternal 911 makes every effort to present accurate and reliable information. The Maternal 911 and Maternal 911 in Action are publications provided 'as is' without any warranty of accuracy, reliability or otherwise, either express or implied. Maternal 911 does not guarantee, warrant, or endorse the products or services of any firm, organization, or person. Neither co-founder nor any officers, directors, members, employees, participants or agents will be liable for any loss, damage or claim with respect to liabilities, including direct, special, indirect, or consequential damages, incurred in connection with this publication or reliance on the information presented.

Data from completing the modules may be used in research and publications with privacy maintained.

Course Description:

Operative vaginal birth is the use of forceps or a vacuum device to assist with a vaginal delivery. The laboring woman may or may not push during the assistance. The health care provider will learn when an operative device is used and how it will be selected. The health care provider will be aware of the risks and benefits of use and complications that may occur to mother and fetus. This education course will keep maternal and fetal safety a priority.

Approximate Time to Complete: 55 minutes

Click here to download a print version of this course.

By the end of the module, knowledge gained will:

- Help the participant develop sound clinical judgment in the delivery of health care in a setting when an operative vaginal birth occurs.
- Enable the participant to develop, implement, and evaluate health care delivery in a practice setting prior to an actual event. This will allow for early recognition of an actual event.
- Enhance the participant's ability to put knowledge into active health care delivery. This will allow for rapid implementation of the necessary steps needed to assist with an operative vaginal birth.
- Prepare the participant to address issues and implement changes in the health care setting as necessary to ensure a safe environment. Equipment and supplies needed when an operative vaginal birth occurs will be available.

MATERNAL911®

- Table of Contents
- Introduction
  - Definition
  - Occurrence
  - Risk Factors
  - Risk Factors Cont'd
  - Vacuum Assisted Birth Risks - Maternal
  - Vacuum Assisted Birth Risks - Fetal
  - Forceps Assisted Birth Risks - Maternal
  - Forceps Assisted Birth Risks - Fetal
- Planning and Prevention
  - Planning and Prevention
  - Planning and Prevention
  - Planning and Prevention
- Vacuum or Forceps Use
  - Indications for Vacuum of Forceps Use
  - Informed Consent
  - Vacuum Cups
  - Types of Vacuums
  - Contraindications
  - First Steps
  - Forceps
- Management and Treatment
  - Forceps Delivery
  - Vacuum Delivery
  - Repeat Assessment
  - Guidelines from Professional Organizations
- Complications
  - Complications

Risk Factors Cont'd
Vacuum Assisted Birth Risks - Maternal
Vacuum Assisted Birth Risks - Fetal
Forceps Assisted Birth Risks - Maternal
Forceps Assisted Birth Risks - Fetal
Planning and Prevention
Planning and Prevention
Planning and Prevention
Planning and Prevention
Vacuum or Forceps Use
Indications for Vacuum of Forceps Use
Informed Consent
Vacuum Cups
Types of Vacuums
Contraindications
First Steps
Forceps
Management and Treatment
Forceps Delivery
Vacuum Delivery
Repeat Assessment
Guidelines from Professional Organizations
Complications
Complications
Maternal Complications
Complications with Vacuum
Complications with Forceps
Fetal Complications
Summary

Operative Vaginal Delivery

To expedite or achieve a safe vaginal delivery, for maternal or fetal indications, an operative vaginal delivery may be considered [11].

The health care provider uses the instrument to extract the fetus, using traction, during a contraction with or without maternal pushing efforts.

The provider is not pulling the fetus but guiding with this traction to assist the woman.

- In 2017, 3.1% of all deliveries in the United States were operative vaginal births [2].
- The rate of vacuum assisted births is 2.6% of vaginal births and forceps deliveries 0.5% of vaginal births [4]. Overall, 80% of operative vaginal deliveries in the United States are vacuum extraction [2].
- In another review, evaluation of operative delivery rates declined from 1.6 to 0.3% while the cesarean rate doubled to reach 14.4% in the prospective study of low and middle income countries [37].
- Overall, the rates vary worldwide and are associated with local practice and availability of trained professionals [1].

- In a systematic review of randomized trials, nine percent of forceps deliveries and 14% of vacuum deliveries failed [14].
- There is however, suggestion that evidence-based guidelines (EBG) are inadequate or randomly applied or techniques in use of vacuum or forceps are declining in some regions [4].
- In the United States, the lowest vacuum rate is in the South, the lowest forceps rate is in the Northeast, and the highest rates for both forceps and vacuum-assisted deliveries is in the Midwest [4].

- An assessment of the pelvis is necessary to evaluate for cephalopelvic disproportion (CPD) in every pregnant woman. Instrumental vaginal delivery is contraindicated when fetal-pelvic disproportion is suspected.
  - With this exam the position or attitude of the fetal head and station must be assessed.
  - This can be accomplished abdominally and with a pelvic exam.
- Variables associated with failure rates include occiput posterior (OP) presentation and macrosomia, so the pelvic exam is important for decision making regarding delivery [5, 38-44].
- Other situations considered to have an association with operative vaginal delivery failure rate include:
  - Nulliparity
  - Higher station
  - Extreme molding of the fetal head
  - Maternal obesity
  - Abnormal labor progress



- In every situation, prior to initiation, risks and benefits related to the use of either instrument over the other for mother and fetus and risk of not using the instrument and her having a cesarean section (c/s) delivery must be considered and explained.
- The success or failure of the operative vaginal birth cannot exactly be predicted by pre-procedural risk factors [6].
- The skilled provider must select ONE instrument to facilitate a successful vaginal birth to prevent complications [6].
  - The American College of Obstetricians and Gynecologists (ACOG) recommends against performing sequential attempts at operative vaginal delivery using different instruments because of increased risk for maternal and/or fetal injury [11].

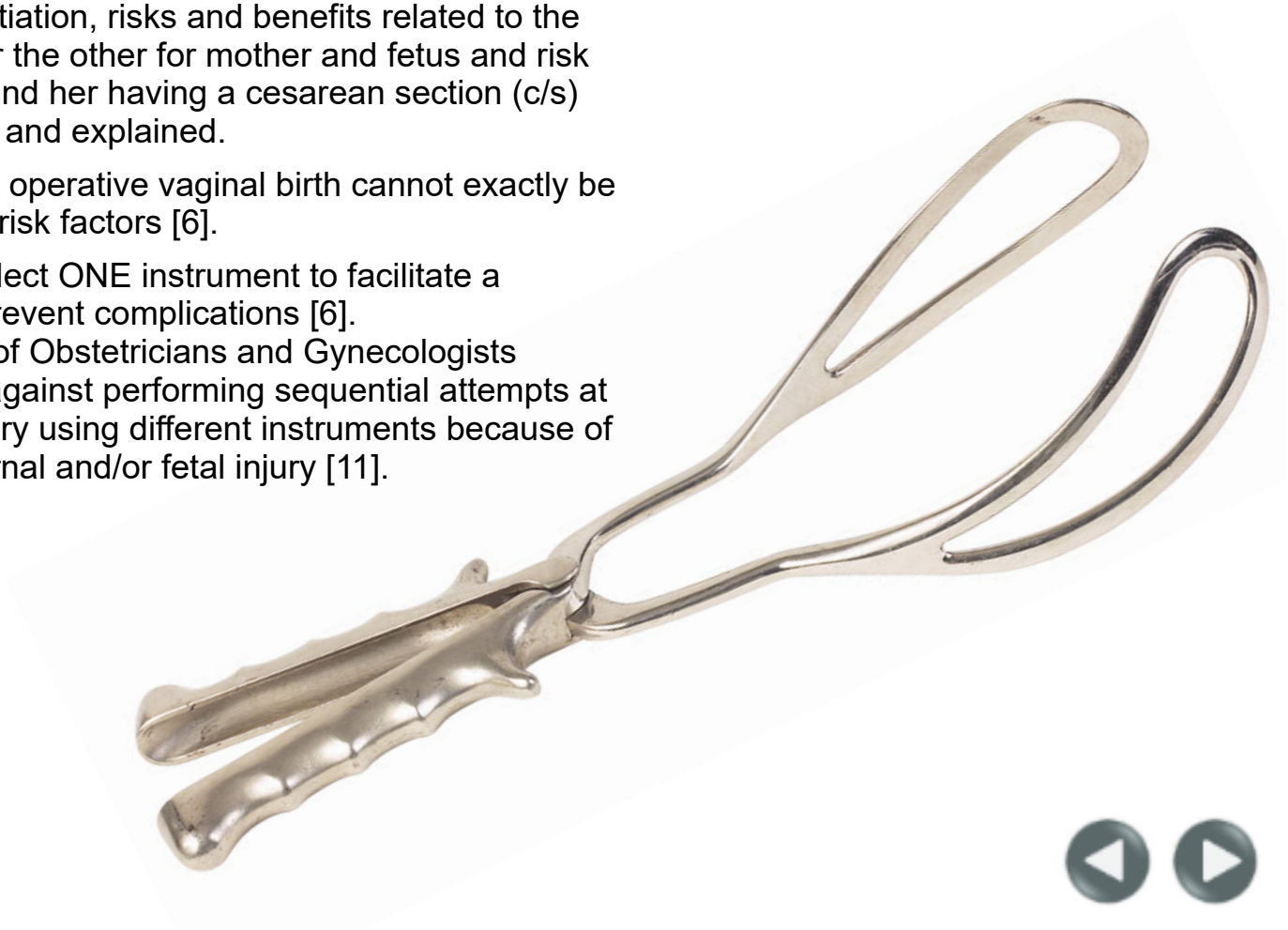

- Hematoma of the vulva and vagina, lower genital tract lacerations, urinary tract injury, and injury to the anal sphincter can occur [17-22, 45-48].
  - Hematoma and/or lacerations can be prevented by verifying the placement of the vacuum cup, ensuring the instrument does not entrap maternal soft tissue, using proper technique to prevent pop off of the cup, controlling descent of the fetal head, and controlling delivery over the perineum.
- There is increased risk of maternal trauma when the fetus is in OP position when operative vaginal delivery is performed [50-52].
  - OP position especially increases the risk for third or fourth-degree perineal lacerations [46, 49].

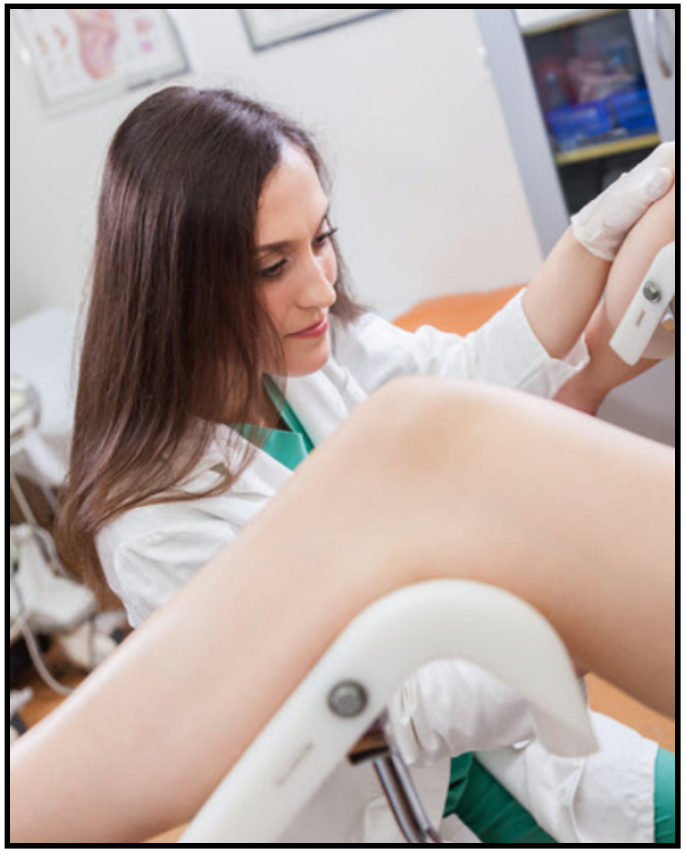

- Life-threatening complications can occur with vacuum-assisted deliveries when there is torsion or traction by the vacuum cup [53].
- Hematoma and/or lacerations can occur to the fetal scalp.
  - This can be prevented by verifying correct placement of the vacuum cup, avoiding excessive pressure or rotating motions, and monitoring traction time.
  - Some experts suggest abandoning the procedure if delivery has not occurred within 15 to 20 minutes or after three pulls. Another review indicates durations greater than 12 minutes had the strongest association with both adverse neonatal outcomes and failed operative deliveries.
- Fetal subgaleal hemorrhage, intracranial bleeding, and other cerebral injuries are a focus in studies when assisted vaginal birth (AVB) has been performed.
- Fetal lacerations, cephalohematoma, retinal hemorrhage, and in rare cases, even death can occur with use of a vacuum to assist with birth [9].
  - Continued fetal evaluation following birth is necessary to monitor for symptoms associated with these conditions, including enlargement of the head circumference, hypovolemia, hyperbilirubinemia, and retinal hemorrhage [7, 8].

- Forceps delivery has a higher risk of maternal injury. There is uncertainty which procedure is safer for the fetus [14].
- Higher risk of maternal genital trauma has been noted in randomized trials when comparing forceps versus vacuum extraction [14].
- Mid-forceps and rotational operations are associated with major risk factors for serious maternal trauma including bladder injury, ureteral lacerations, ureteral transections, and uterine rupture [54].
- Mid-pelvic deliveries carrier a higher risk of maternal morbidity and mortality compared to a cesarean delivery [55].
- It is important for the provider to evaluate case-by-case the risks and benefits of mid-pelvic operative delivery versus cesarean delivery.

- Fetal complications with a forceps delivery may include any of the following: skull fracture, facial nerve injury, lipoid necrosis, retinal hemorrhage, subgaleal hemorrhage, intracranial hemorrhage, external ocular trauma, skin markings and lacerations and, in rare cases, death [9, 10, 26, 36].
- Facial injuries, including palsies, and depressed skull fractures are more common with use of forceps than the vacuum extractor [10, 29].
  - Facial injury was five times more likely to occur with forceps than vacuum use in a meta-analysis of randomized trial review [14].

- An operative vaginal birth may be considered when the likelihood of success is present. If safety is a concern, cesarean delivery is the better option.
- The health care provider must have the appropriate training, experience, and ability to use the selected instrument.
- Appropriately skilled personnel are in attendance to provide ongoing care to the mother during the procedure and personnel should be present to provide neonatal resuscitation to the fetus following delivery.

Advantages to using forceps by the skilled provider [9];

- Less likely to become detached from the fetal head
- Has a higher success rate than a vacuum
- Can be used on premature fetuses less than 34 weeks gestation
- Can be used for rotation
- With proper placement causes less trauma to the fetal head in regards to cephalohematoma, retinal hemorrhage, and does not cause bleeding from scalp sampling or fetal scale electrode (FSE) sites.

Advantages to the use of the vacuum by a skilled provider

- Easy to apply
- Less force of the fetal head
- Decreased analgesia for the woman
- Less soft tissue trauma for the woman

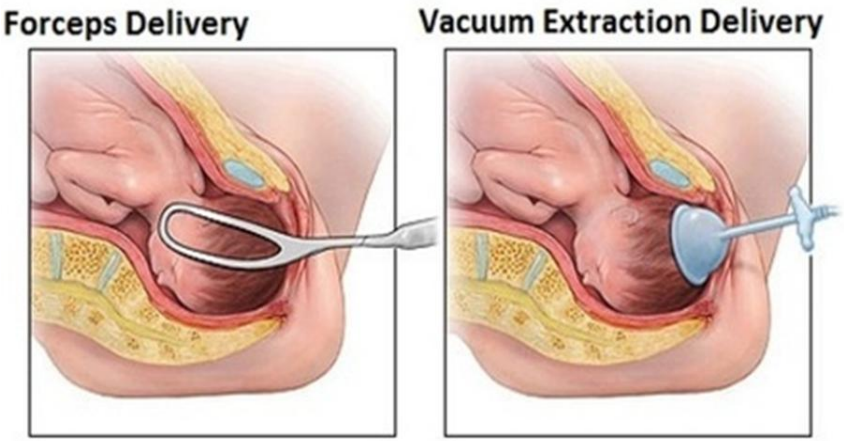

- Criteria for use of a vacuum or forceps must be well thought prior to initiation.
- ACOG practice bulletin identified indications for operative vaginal delivery; vacuum and forceps, is not absolute and c/s delivery is an appropriate option in certain situations [11].

Indications for Vacuum or Forceps Use

- Nonreassuring fetal status, per fetal heart rate (FHR) tracing, that is suspicious of immediate or potential fetal compromise.
  - This may be present with a placenta abruption. Operative vaginal delivery may expedite the delivery if criteria are appropriate for vacuum or forceps use; otherwise, a c/s delivery may be more effective and safer.
- Maternal cerebral vascular disease (CVD), cardiac or neurological, or cystic lung disease where Valsalva maneuver is contraindicated.
- Inadequate progress of labor or lack of effective pushing technique by the mother.
- A prolonged second stage of labor for a nulliparous woman with epidural anesthesia is defined as no descent or rotation following > 4 hours. Prolonged second stage for a nulliparous woman without an epidural is > 3 hours [12, 56].
- A multiparous woman is considered to have a prolonged second stage of labor if no descent or rotation after > 3 hours with epidural anesthesia and without epidural anesthesia > 2 hours [12, 56].

- It is very important to have informed consent prior to using an instrument to facilitate a vaginal birth.
- This must include the risks and benefits of the instruments use and the understanding that an immediate c/s may be necessary if complications to mother and/or fetus arise.
- Following informed consent, the health care provider must perform a repeat assessment.

Vacuum-assisted Delivery

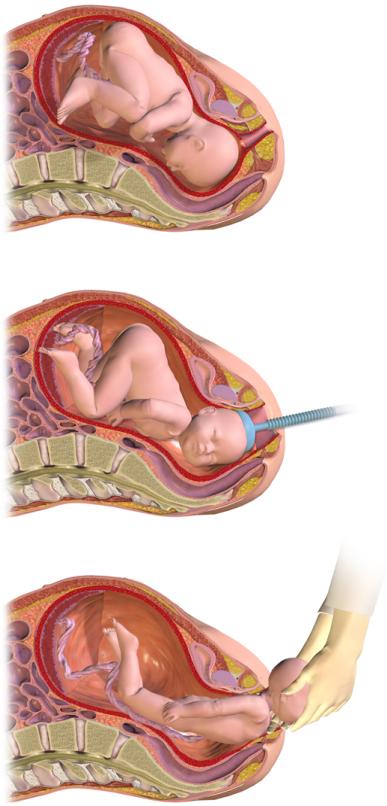

Vacuum Cups

- May be soft or rigid
- May be bell or mushroom or "M" shaped
- Sizes vary by manufacturer
- Any size may be used for late preterm or term fetus that meets criteria for vacuum assisted delivery
- Numerous trials have compared the soft versus rigid cups. A Cochran analysis of data included nine trials of 1375 women and noted the soft cups more frequently failed to achieve vaginal delivery, but caused less scalp injury than rigid cups, but no difference in terms of maternal injury [33].

Soft Vacuum Cups

- The soft cup is more appropriate for an uncomplicated delivery.

Click here to view images and more information on soft cup vacuums.

Rigid Vacuum Cups

- Rigid vacuums are made of metal or a firm plastic, are mushroom-shaped, and vary from 40 to 60 mm in diameter.
- A suction device is attached to the cup via a peripherally located vacuum port.
- This type of cup is to be considered for a more difficult delivery such as OP, a transverse lie, and the more difficult occiput anterior (OA) deliveries [14].
- Vacuum cups can be disposable or reusable.
- This rigid device is less likely to become detached.

Click here to view images comparing soft and rigid vacuum cup.

Soft Vacuum Cups

- The soft cup is more appropriate for an uncomplicated delivery.

Rigid Vacuum Cups

- Rigid vacuums are mad
  vary from 40 to 60 mm i
- A suction device is atta
- This type of cup is to be
  transverse lie, and the r
- Vacuum cups can be di
- This rigid device is less

images comparing
uum cup.

Soft Cup Vacuums:

- Soft cups are more appropriate for an uncomplicated occiput anterior (OA) presentation because less traction is needed.
- Failures with the soft cup are most likely related to detachment, pop-offs [33].
- Features of the soft cup includes:
  - A handle for traction.
  - A combined vacuum pump and handle device or a vacuum port for a vacuum hose attachment.
    - Suction can be generated with an electrical suction device or manually with a hand held device which can be activated by either the provider or an assistant.
  - A fixed guard inside of the vacuum cup for safety.
  - The soft vacuum cups are made of silicone, plastic, polyethylene, or rubber.
  - The shape may be bell or mushroom "M" shaped but are generally bell shaped.
  - Devices come with a traction force indicator to compare personal impression with an objective measurement of the force being used.

Click here to see images of soft cup devices.

A
B
C

REVIEWS IN
OBSTETRICS & GYNECOLOGY™

PMC full text: Rev Obstet Gynecol. 2009 Winter; 2(1): 5–17.

Copyright/License Request permission to reuse

Figure 2

Open in a separate window

Types of vacuum cups. The 2 main types of hand-held disposable vacuum devices are shown: (A) The soft cup, which is pliable and funnel- or bell-shaped. (B) The rigid cup, which is firm and mushroom-shaped (M cup). They can be made of plastic, polyethylene, or silicone. The freely rotating stem of the hand-held device (shown as an arrow) prevents torque (rotation) of the cup and resultant cookie-cutter injuries to the fetal scalp.

Images in this article



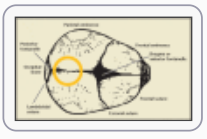
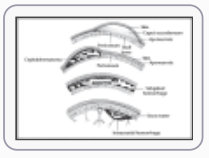

Click on the image to see a larger version.

Rev Obstet Gynecol
Rev Obstet Gynecol
Rev Obstet Gynecol

Contraindiction to Vacuum Use

- Fetal position other than vertex, brow, or face presentation
- Gestation less than 34 weeks
- Extreme prematurity increases the occurrence of intraventricular hemorrhage
- Need for fetal rotation
- Contraindication for a vaginal delivery
- Fetal conditions
- Bleeding disorders including:
  - Hemophilia
  - Alloimmune thrombocytopenia
  - von Willebrand's disease
  - Demineralization disorder
  - Osteogenesis imperfecta
- Fetal scalp sampling or numerous attempts to place a FSE may increase the risk of fetal cephalohematoma or bleeding from the sites.
- Unknown fetal position
- Suspected fetal-pelvic disproportion

Contraindiction to Forceps Use

- Contraindication for a vaginal delivery
- Fetal conditions
- Bleeding disorders including:
  - Hemophilia
  - Alloimmune thrombocytopenia
  - von Willebrand's disease
  - Demineralization disorder
  - Osteogenesis imperfecta
- Fetal scalp sampling or numerous attempts to place a FSE may increase the risk of fetal cephalohematoma or bleeding from the sites.
- Extreme fetal prematurity
- Unknown fetal position
- Suspected fetal-pelvic disproportion

- Forceps may be considered for rotation of the fetal head when in a cephalic presentation or used to assist in the delivery of the after coming head during a breech delivery.
- Forceps are not to be applied if the cervix is not completely dilated or the fetal presenting part is not engaged [11, 34].

Outlet Forceps	• Outlet forceps may be used when the fetal head is visible at the vaginal introitus without separating the labia majora, or the fetal head is on or at the perineum, and the fetal presentation is right or left occiput anterior or posterior position. • Rotation does not exceed 45 degrees [11, 34].
Low Forceps	• Low forceps may be considered if the fetal skull is +2 cm station or 2 cm or more beyond the ischial spines using a scale of up to +5 cm but not on the pelvic floor and rotation of the fetal head is no more than 45 degrees. • Rotation of 45 degrees or less may allow for a left or right occiput anterior to occiput anterior position or left or right occiput posterior to occiput posterior position [11, 34].
Midforceps	• Midforceps are used when the fetal head is engaged but is higher than +2 cm station beyond ischial spines [11, 34]. • Use of midforcep delivery is only appropriate in selected clinical scenarios.

The type and placement of forceps will be determined based on maternal and fetal factors.

Correct placement is important to prevent both maternal and fetal injury.

Click the titles on the right to view additional images.

Types of Forceps

Placement of Forceps 1

Placement of Forceps 2

Types of Forceps

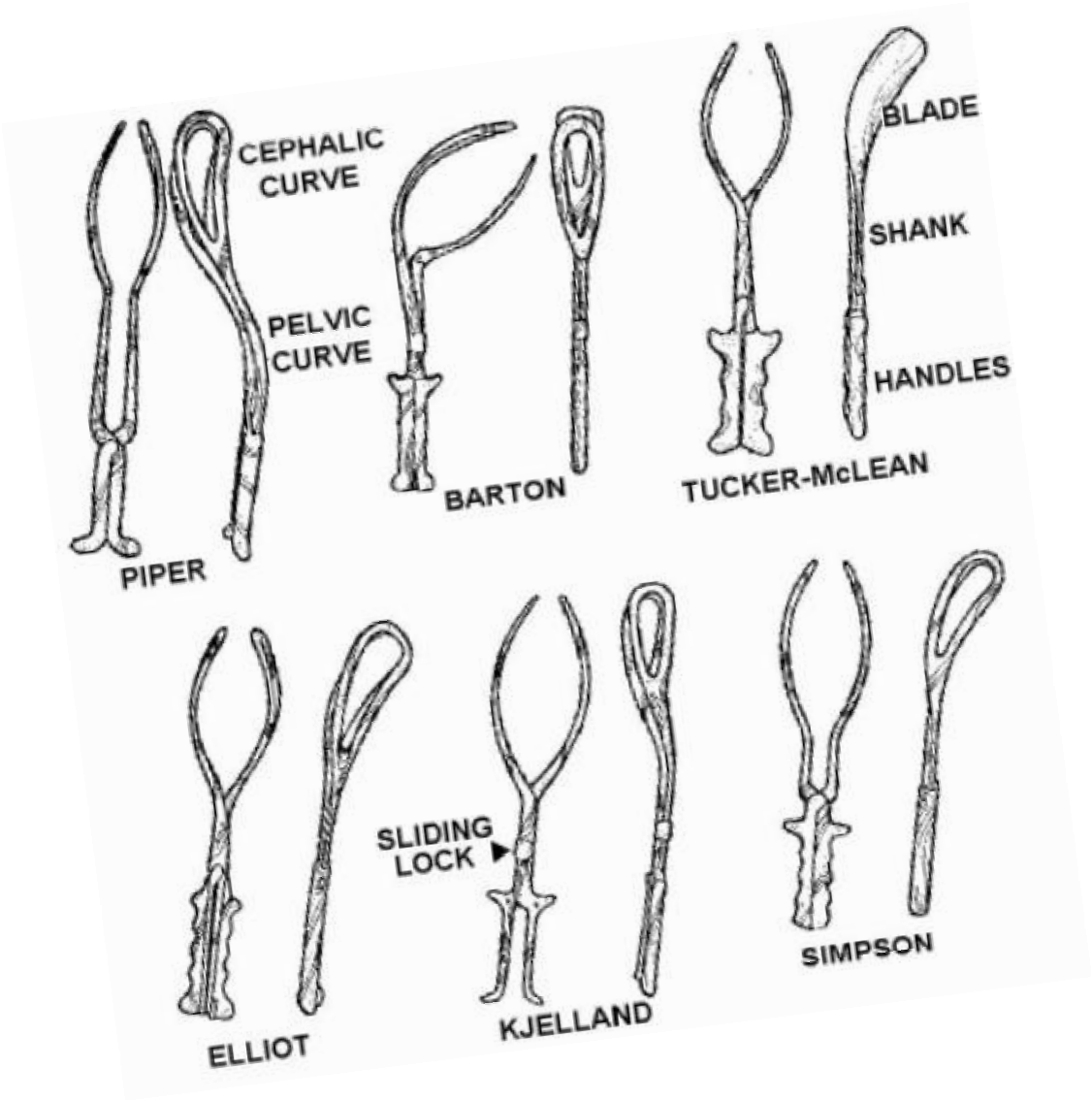

Forceps Assisted Delivery

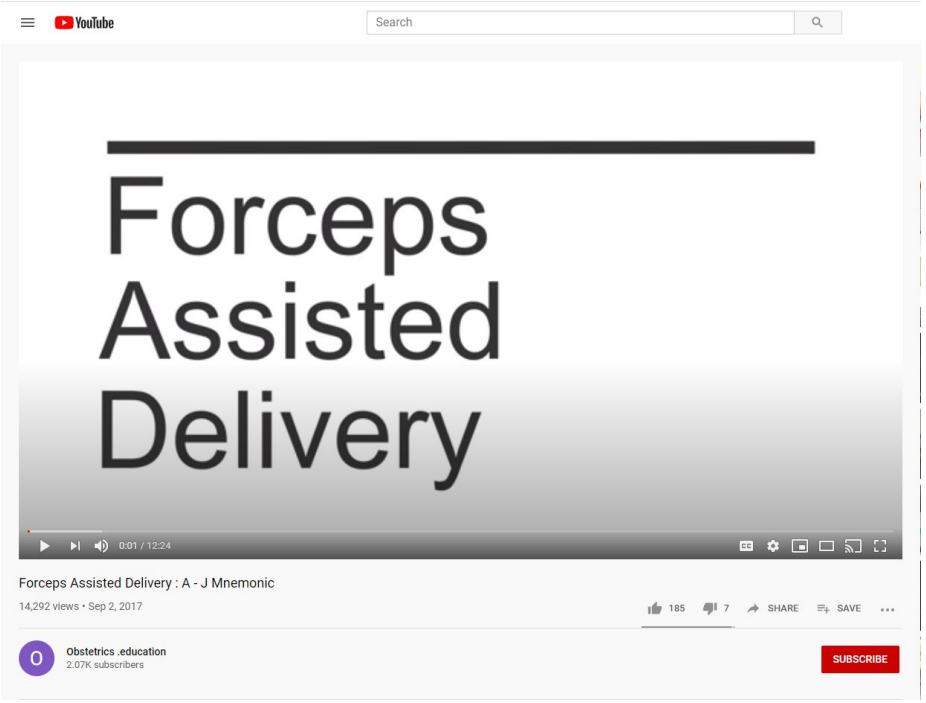

https://www.youtube.com/watch?v=4s-fdy7Ye9E

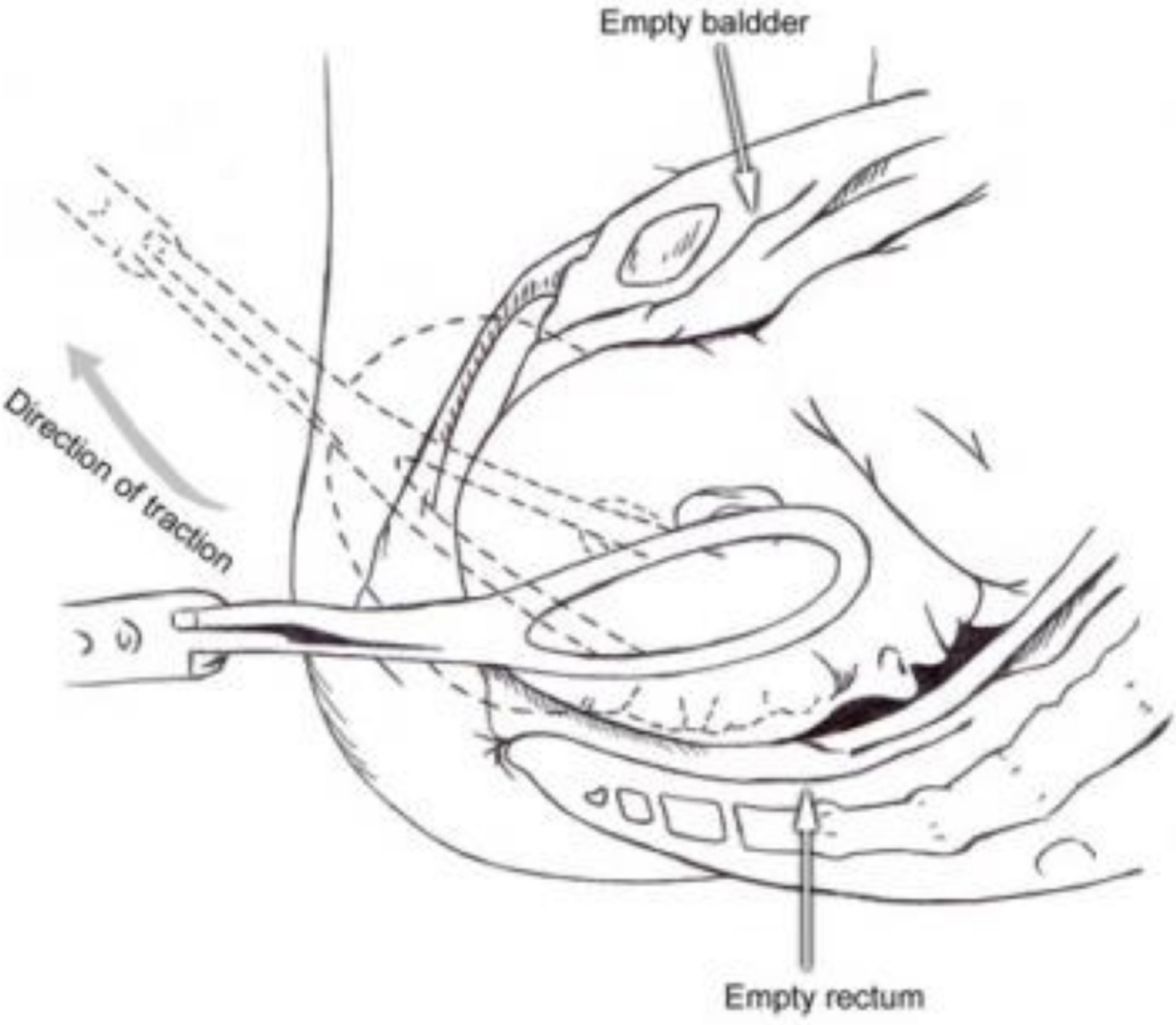
Empty baldder
Direction of traction
Empty rectum

- The type of forceps selected will be based upon:
  - Size and shape of the fetal head
  - Size and shape of the maternal pelvis
  - The indication for forceps to facilitate delivery
  - Provider preference and experience
- To reduce the risk of lacerations to the fetus, confirmation of appropriate application is necessary prior to applying traction.
- To reduce risk of maternal lacerations, the forceps are removed when expulsion of the fetal head is assured but before the widest diameter of the fetal head passes the vaginal introitus.

- Forceps used for traction requires the provider to use steady movement following the birth canal, and limiting any rocking motion [13].
- Traction will occur with maternal pushing efforts and will relax between contractions [13].
- Forceps may be used when rotation of the fetus is needed.
- Rotation of the fetus is associated with higher risk of complications for the fetus and woman when compared to use for traction.
- Progress should be noticed with the first two pulls and delivery by the third or fourth pull [15].
  - Forceps should be abandoned if descent does not occur in this time frame.
  - Some experts suggest abandoning the procedure if delivery has not occurred within 15 to 20 minutes or after three pulls [13].

Typical steps for vacuum extraction

- Some vacuum extractor pressures are elicited by the provider.
- Other vacuum extractors require the provider to hand off the tubing to a nurse and he/she will connect this to a hand held pump.
  - The provider will tell the nurse when to increase the suction pressure.
  - This is initiated at the beginning of a contraction and traction is applied as the contraction builds.
  - Traction is maintained throughout the contraction.
- The nurse will indicate when the suction gauge has reached the appropriate level to assist with the delivery.
- The provider will begin using traction with maternal pushing efforts to facilitate birth.
- The procedure should be abandoned if delivery does not occur within 3 pulls or 15 to 20 minutes [13].

Repeat Assessment

- The woman's bladder should be emptied to prevent injury during instrumentation use. If she cannot empty the bladder on her own a straight catheter may be used.
  - If a catheter is used it is not left in place as this contributes to injury of her urinary tract.
- A digital pelvic exam is performed to assess that the cervix is completely dilated.
- Evaluation that the fetus is engaged in the vertex presentation and is at an appropriate station is absolutely necessary.
  - Criteria to be considered is a large fetus, extreme molding or caput, extension of the fetal head, asynclitic fetal presentation, and maternal pelvic deformities or CPD which can make assessment of this difficult.
  - Ultrasound evaluation may help with this assessment but if not available, palpation of the maternal abdomen should demonstrate no more than one-fifth of the fetal head is palpable if appropriately engaged [13].
- Careful use of vacuum extractor or forceps is an acceptable consideration for a macrosomic fetus by a trained provider [11].
- The labor pattern identifies an adequate contraction pattern and the membranes are ruptured. If there is any uncertainty regarding fetal presentation an intrapartum ultrasound should be performed.
  - Prophylactic antibiotics are not indicated [57].
  - Routine episiotomy are not performed.
- Evaluation that appropriate anesthesia has been provided to the mother.
  - If necessary, a vacuum extraction delivery may be performed without anesthesia.
- Ensure the ability to perform a c/s is available if complications occur.

In review

- ACOG committee opinion discusses the increased incidence of intracranial injury when vacuum, forceps, and c/s occur in combination [11].
- ACOG recommends avoiding another attempt using a different instrument related to potential for fetal and/or maternal injury including but not limited to third and fourth degree perineal lacerations and postpartum hemorrhage [11, 16].

Complications to AVB are dependent on:

- Maternal parity
- Position/placement of the forceps or vacuum
- Fetal station
- Head position at the time of application
- Provider experience

- Maternal complications associated with the use of forceps or vacuum at the time of delivery include:
  - Increase in pain
  - Continued perineal pain for 24 hours following delivery
  - Lower genital tract lacerations including third and fourth degree lacerations
  - Cervical lacerations
  - Vulvar and/or vaginal hematomas
  - Urinary incontinence or retention
  - Anal incontinence
  - Anemia related to blood loss [17-23]
- Rectal injury is greater for AVB when the fetus is in the OP position compared to OA [23].
- Readmission to the hospital is greater due to complications following AVB [17-23].
- Maternal complications in the postpartum period and beyond include [24]:
  - Pelvic floor dysfunction
  - Pelvic organ prolapse
  - Urine and/or fecal incontinence
  - Fistulas

Fetal complications associated with AVB vary with the method used.

- Intracranial hemorrhage increases with operative vaginal delivery [25].
- Rotation or movement of the vacuum cup can cause:
  - Scalp abrasions
  - Lacerations
  - Cephalohematoma
  - Subgaleal hematoma
  - Intracranial hemorrhage
  - Retinal hemorrhage
  - Hyperbilirubinemia
  - Skull fracture [26, 27, 28]

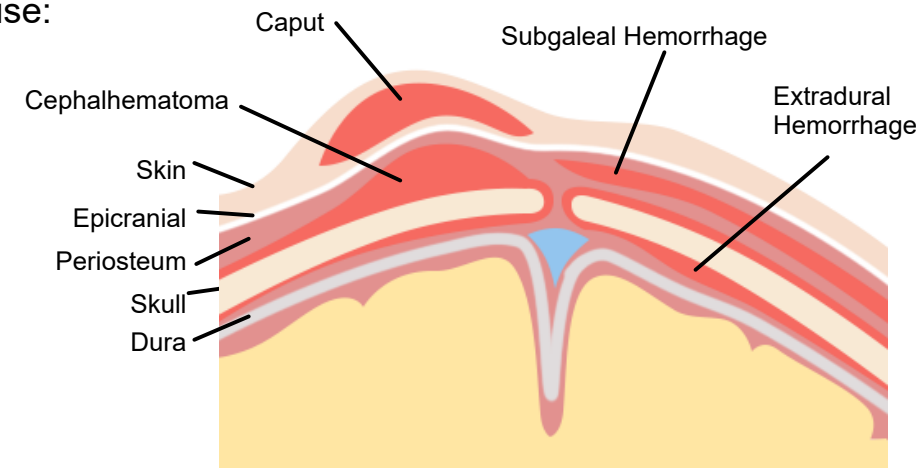

- Shoulder dystocia is more common with vacuum assisted deliveries which are associated with higher occurrence rates of brachial plexus injury [25, 29, 35].
- A prospective study found complications following a vacuum assisted birth presented within the first 10 hours of life; therefore, stressing the importance of communicating the method of delivery to the neonatal care provider [30].

- Fetal complications associated with the use of forceps include
  - Injury to the skin causing lacerations
  - Forceps markings or bruising
  - External ocular injury/trauma
  - Intracranial hemorrhage
  - Subgaleal hematomas
  - Hyperbilirubinemia
  - Retinal hemorrhage
  - Nerve injury
  - Skull fracture
  - Death [10, 31, 32, 36]
- Long term effects of vacuum or forceps use on the fetus does not demonstrate a difference in child development [24].

MATERNAL911®

Fetal Complications

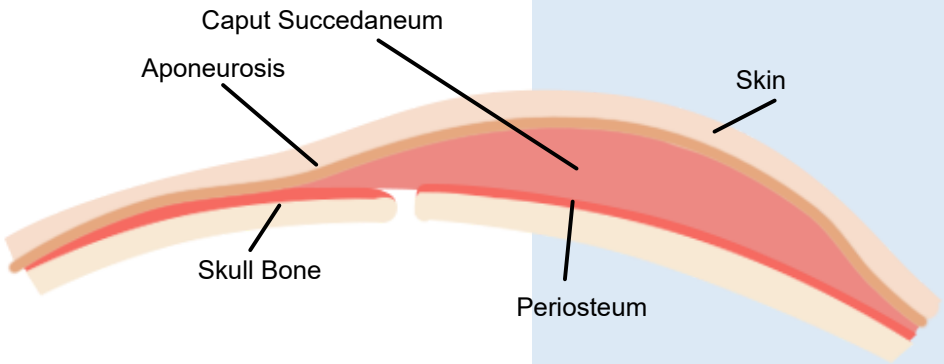

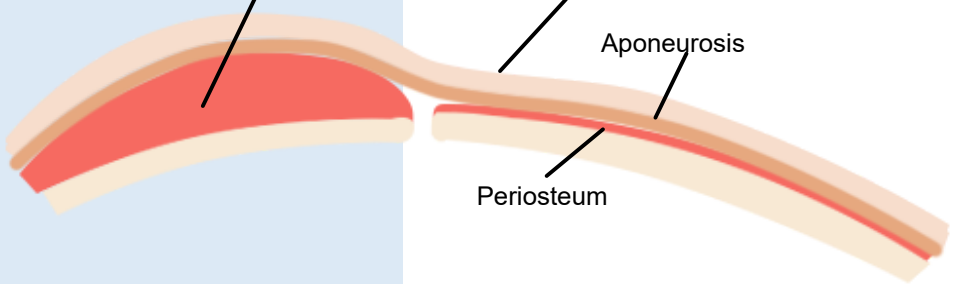

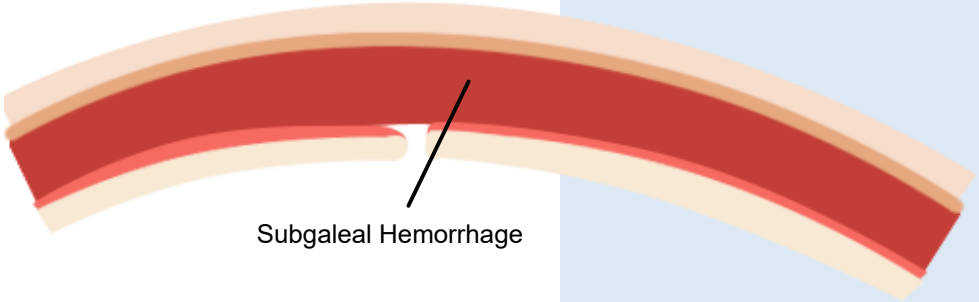

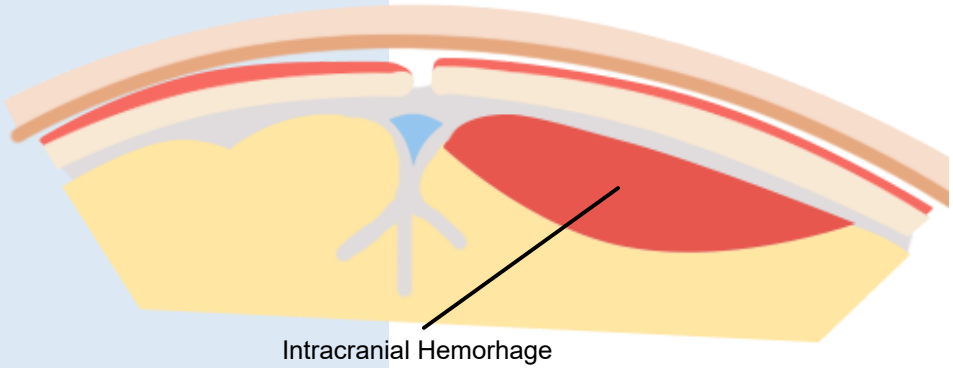

The provider must be trained and skilled in the use of the vacuum or forceps prior to use.

Risks and benefits of AVB need to be evaluated against c/s delivery.

Non-reassuring fetal status with adequate maternal evaluation may be accomplished sooner with AVB than a c/s delivery.

Click each box for more information.

Maternal risks that determine valsalva is not recommended and should be discussed prior to labor and a plan of care developed.

Evaluate for complete cervical dilation, membranes are ruptured, fetal presentation, engagement, station and position are assessed, maternal anesthesia is adequate, fetus is appropriate gestational age for instrument, maternal bladder is empty, and there are no fetal bleeding diathesis or demineralization disorder present prior to initiating an AVB.

Click each box for more information.

Patient safety includes appropriate staff are present during the delivery and for the recovery period for both the mother and fetus.

Vacuum should not be used on a fetus less than 34 weeks gestation.

Vacuum is not used for fetal rotation.

AVB should be abandoned if the provider has difficulty applying the instrument, descent does not proceed with traction, or delivery does not occur in 15-20 minutes or after three pulls with no progress.

MATERNAL911®

Congratulations!

You have successfully completed this module.

Click on the above 'X' to take the post-test for this course.
If you do not attain a passing score after two attempts at the post-test the entire program must be repurchased.

After increasing nearly every year since 1990, the IOL rate for singleton births declined in 2011 and 2012.

Induction of labor, by gestational age: United States, 1990–2012.

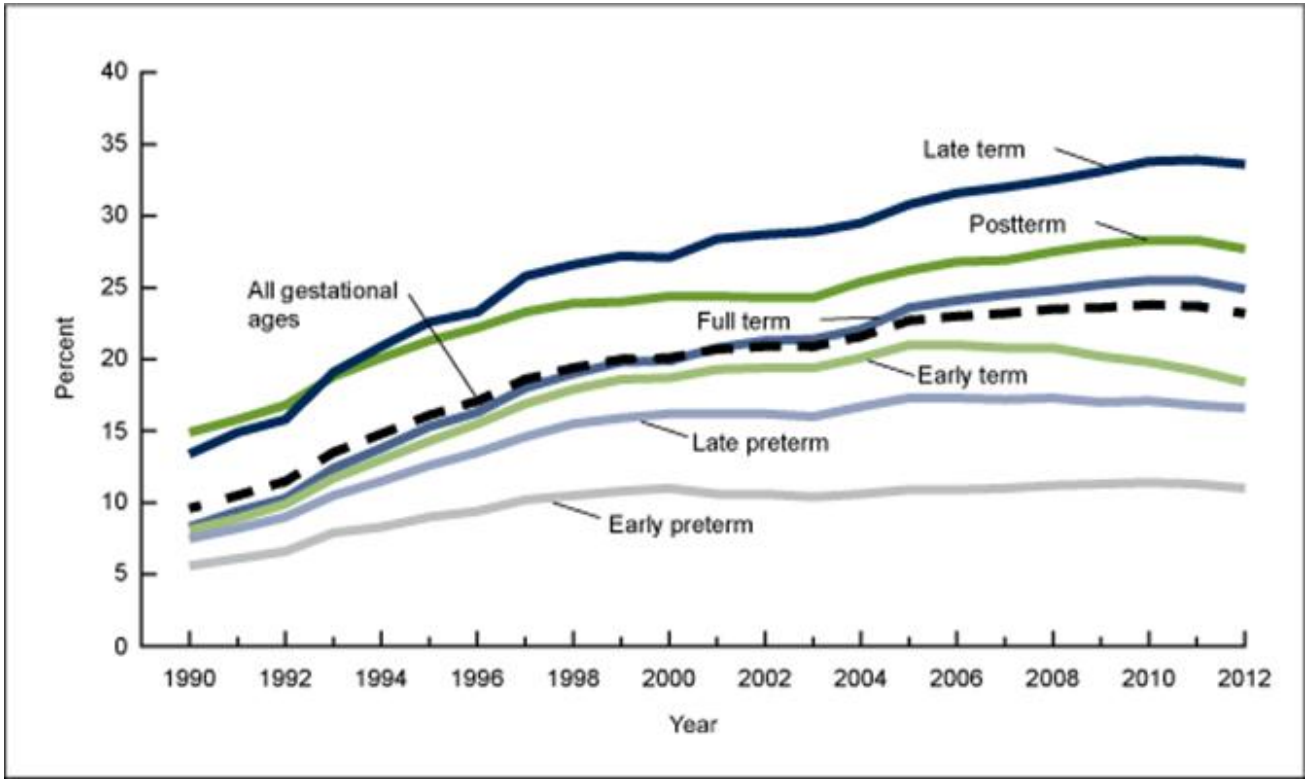

NOTES: Singletons only. Early preterm is less than 34 weeks of gestation; late preterm is 34–36 weeks; early term is 37–38 weeks; full term is 39–40 weeks; late term is 41 weeks; post term is 42 weeks or more.
SOURCE: CDC/NCHS, National Vital Statistics System

Figure 2. Induction of labor at each gestational week 34–38: United States, _2006–2012.

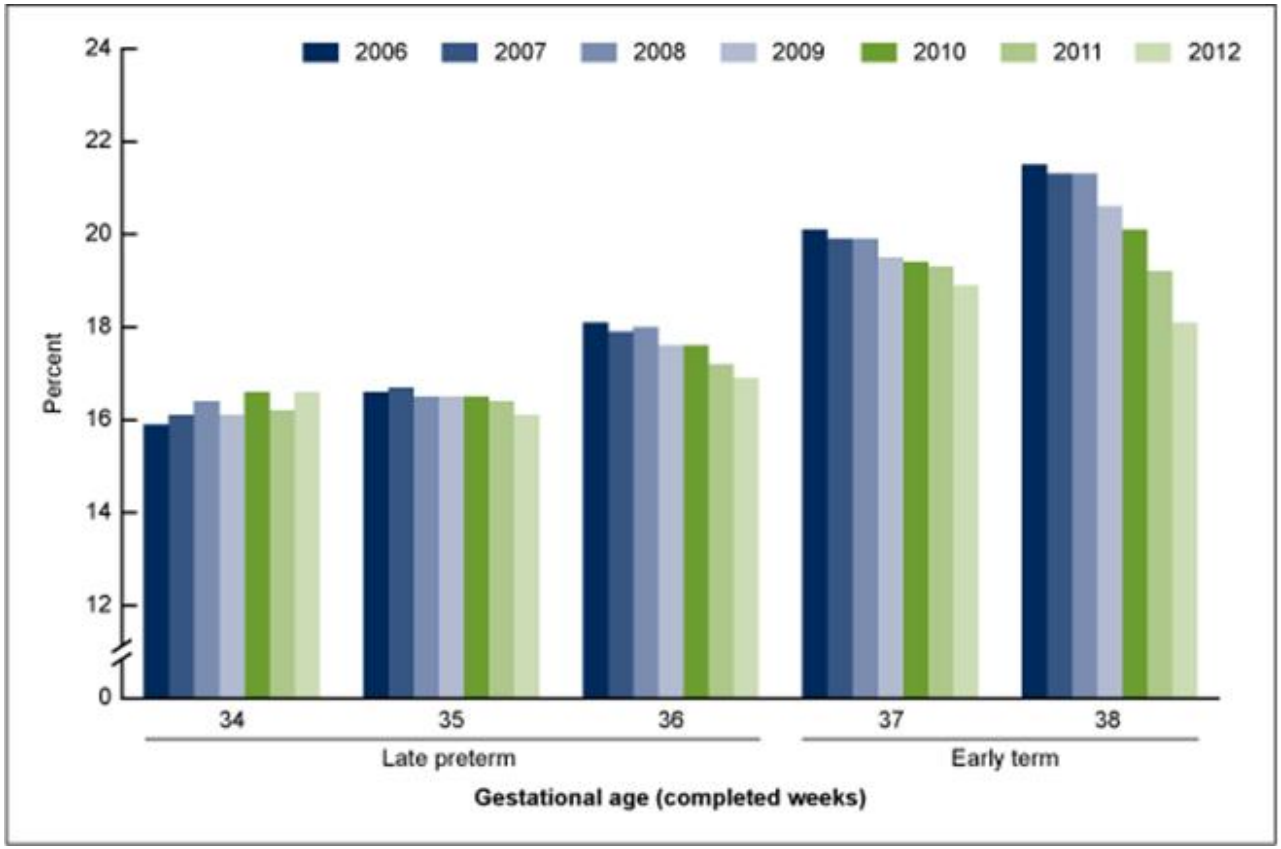

NOTES: Singletons only. Thirty-four, 35, and 36 weeks are late preterm; 37 and 38 weeks are early term.
SOURCE: CDC/NCHS, National Vital Statistics System

1.Merriam AA, Ananth CV, Wright JD, et al. Trends in operative vaginal delivery, 2005-2013: a population-based study. BJOG 2017; 124:1365.

2.Martin JA, Hamilton BE, Osterman MJK, Driscoll AK, Drake P. Births: Final Data for 2017. Natl Vital Stat Rep. 2018;67(8):1.

3.Ameh CA, Weeks AD. The role of instrumental vaginal delivery in low resource settings. BJOG 2009; 116 Suppl 1:22.

4. Clark SL, Belfort MA, Hankins GD, Meyers JA, Houser FM; Variation in the rates of operative delivery in the United States. Am J Obstet Gynecol. 2007;196(6):526.e1.

5. Murphy DJ, Liebling RE, Verity L, Swingler R, Patel R, Early maternal and neonatal morbidity associated with operative delivery in second stage of labour: a cohort study. Lancet. 2001;358(9289):1203.

6. Palatnik A, Grobman WA, Hellendag MG, et al. Predictors of Failed Operative Vaginal Delivery in a Contemporary Obstetric Cohort. Obstet Gynecol 2016; 127:501.

7. Vacca A. Vacuum-assisted delivery. OBG Manag 2004; Suppl:S1.

8. Watts P, Maguire S, Kwok T, Talabani B, Mann M, Wiener J, et al. Newborn retinal hemorrhages: a systematic review. J AAPOS 2013.

9. Gei AF, Belfort MA. Forceps-assisted vaginal delivery. Obstet Gynecol Clin North Am 1999; 26:345.

10.Dupuis O, Silveira R, Dupont C, Mottolese C, Kahn P, Dittmar A, et al. Comparison of "instrument-associated" and "spontaneous" obstetric depressed skull fractures in a cohort of 68 neonates. Am J Obstet Gynecol 2005;192(1):165-70.

11.Committee on Practice Bulletins Obstetrics. ACOG Practice Bulletin No. 154 Summary: Operative Vaginal Delivery. Obstet Gynecol 2015; 126:1118. Reaffirmed 2018.

12.Spong, C.Y., Berghella, V., Wenstrom, K.D, et al. Preventing the first cesarean delivery: summary of a joint Eunice Kennedy Shriver National Institute of Child Health and Human Development, Society for Maternal-Fetal Medicine, and American College of Obstetricians and Gynecologists Workshop. Obstet Gynecol 2012; 120:1181.

13. Edozien, L.C. Towards safe practice in instrumental vaginal delivery. Best Pract Res Clin Obstet Gynaecol, 2007; 21:639.

14. O'Mahony, F., Hofmeyr, G.J., Menon, V. Choice of instruments for assisted vaginal delivery. Cochran Database. Syst Rev 2010; CD005455.

15. Sjostedt, JE. The vacuum extractor and forceps in obstetrics. Acta Obstet Gynecol Scand. 1967; 46 Suppl 10:Suppl.

16. Fong, A., Wu, E., Pan, D. et al. Temporal trends and morbidities of vacuum, forceps, and combined use of both. J Maternal Fetal Neonatal Med, 2014; 27:1886.

17.Liu S, Heaman M, Joseph KS, et al. Risk of maternal postpartum readmission associated with mode of delivery. Obstet Gynecol 2005; 105:836.

18.Meyer S, Schreyer A, De Grandi P, Hohlfeld P. The effects of birth on urinary continence mechanisms and other pelvic-floor characteristics. Obstet Gynecol 1998; 92:613.

19.Meyer S, Hohlfeld P, Achtari C, et al. Birth trauma: short and long term effects of forceps delivery compared with spontaneous delivery on various pelvic floor parameters. BJOG 2000; 107:1360.

20.Fitzpatrick M, Behan M, O'Connell PR, O'Herlihy C. Randomised clinical trial to assess anal sphincter function following forceps or vacuum assisted vaginal delivery. BJOG 2003; 110:424.

21.Pretlove SJ, Thompson PJ, Toozs-Hobson PM, et al. Does the mode of delivery predispose women to anal incontinence in the first year postpartum? A comparative systematic review. BJOG 2008; 115:421.

22.Friedman AM, Ananth CV, Prendergast E, et al. Evaluation of third-degree and fourth-degree laceration rates as quality indicators. Obstet Gynecol 2015; 125:927.

23.Damron DP, Capeless EL. Operative vaginal delivery: a comparison of forceps and vacuum for success rate and risk of rectal sphincter injury. Am J Obstet Gynecol 2004; 191:907.

24.Johanson, R.B., Heycock, E., Carter, J., et al. Maternal and child health after assisted vaginal delivery; five-year follow up of a randomised controlled study comparing forceps and ventouse. Br J Obstet Gynaecol 1999; 106:544.

25. Demissie D, Rhoads GG, Smulian JC, et al. Operative vaginal delivery and neonatal and infant adverse outcomes: population based retrospective analysis. BMJ 2004; 329:24.

26.Towner, D., Castro, M. A., Eby-Wilkens, E., Gilbert, W. M. Effect of mode of delivery in nulliparous women on neonatal intracranial injury. N Engl J Med 1999; 341: 1709.

27.Baskett, T. F., Fanning, C. A., Young, D. C. A prospective observational study of 1000 vacuum assisted deliveries with the Omni Cup device. J Obstet Gynaecol Can 2008; 30:573.

28.Wen, S. W., Liu, S., Kramer, M. S, et al. Comparison of maternal and infant outcomes between vacuum extraction and forceps deliveries. Am J Epidemiol 2001; 153:103.

29.Werner, E. F., Janevic, T. M., Illuzzi, J, et al. Mode of delivery in nulliparous women and neonatal intracranial injury. Obstet Gynecol 2011; 118:1239.

30.Smit-Wu, M. N., Moonen-Delarue, D. M., Benders, M. J., et al. Onset of vacuum-related complaints in neonates. Eur J Pediatr 2006; 165:374.

31.Gei, A. F., Belfort, M. A. Forceps-assisted vaginal delivery. Obstet Gynecol Clin North Am 1999; 26: 345.

32.Towner, D., Castro, M. A., Eby-Wilkens, E., Gilbert, W. M. Effect of mode of delivery in nulliparous women on neonatal intracranial injury. N Engl J Med 1999; 341:1709.

33. Johanson R, Menon V. Soft versus rigid vacuum extractor cups for assisted vaginal delivery. Cochran Database Syst Rev 2000; :CD000446.

34. Hagadom-Freathy AS. Yeomans ER, Hankins GD. Validation of the 1988 ACOG forceps classification system. Obstet Gynecol 1991; 77:356.

35. Caughey AB, Sandberg PL, Zlatnik MG, et al. Forceps compared with vacuum: rates of neonatal and maternal morbidity. Obstet Gynecol 2005; 106:908.

36. Robertson PA, Laros RK Jr, Zhao RL. Neonatal and maternal outcome in low-pelvic and midpelvic operative deliveries. Am J Obstet Gynecol 1990; 162:1436.

37. Harrison MS, Saleem S, Ali S, et al. A Prospective, Population-Based Study of Trends in Operative Vaginal Delivery Compared to Cesarean Delivery Rates in Low- and Middle-Income Countries, 2010-2016. Am J Perinatol 2019; 36:730.

38. Gopalani S, Bennett K, Critchlow C. Factors predictive of failed operative vaginal delivery. Am J Obstet Gynecol. 2004;191(3):896

39. Al-Kadri H, Sabr Y, Al-Saif S, Abulaimoun B, Ba'Aqeel H, Saleh A. Failed individual and sequential instrumental vaginal delivery: contributing risk factors and maternal-neonatal complications. Acta Obstet Gynecol Scand. 2003;82(7):642.

40. Saropala N, Chaturachinda K. Failed instrumental delivery: Ramathibodi Hospital, 1980-1988. Int J Gynaecol Obstet. 1991;36(3):203.

41. Ben-Haroush A, Melamed N, Kaplan B, Yogev Y. Predictors of failed operative vaginal delivery: a single-center experience. Am J Obstet Gynecol. 2007;197(3):308.e1.

42. Olagundoye V, MacKenzie IZ. The impact of a trial of instrumental delivery in theatre on neonatal outcome. BJOG. 2007;114(5):603.

43. Bhide A, Guven M, Prefumo F, Vankalayapati P, Thilaganathan B. Maternal and neonatal outcome after failed ventouse delivery: comparison of forceps versus cesarean section. J Matern Fetal Neonatal Med. 2007;20(7):541

44. Aiken CE, Aiken AR, Brockelsby JC, Scott JG. Factors influencing the likelihood of instrumental delivery success. Obstet Gynecol. 2014;123(4):796

45 Dell DL, Sightler SE, Plauché WC. Soft cup vacuum extraction: a comparison of outlet delivery. Obstet Gynecol 1985; 66:624.

46 Landy HJ, Laughon SK, Bailit JL, et al. Characteristics associated with severe perineal and cervical lacerations during vaginal delivery. Obstet Gynecol 2011; 117:627.

47 Macleod M, Strachan B, Bahl R, et al. A prospective cohort study of maternal and neonatal morbidity in relation to use of episiotomy at operative vaginal delivery. BJOG 2008; 115:1688.

48 Gurol-Urganci I, Cromwell DA, Edozien LC, et al. Third- and fourth-degree perineal tears among primiparous women in England between 2000 and 2012: time trends and risk factors. BJOG 2013; 120:1516.

49. Angioli R, Gómez-Marín O, Cantuaria G, O'sullivan MJ. Severe perineal lacerations during vaginal delivery: the University of Miami experience. Am J Obstet Gynecol 2000; 182:1083.

50. Damron DP, Capeless EL. Operative vaginal delivery: a comparison of forceps and vacuum for success rate and risk of rectal sphincter injury. Am J Obstet Gynecol 2004; 191:907.

51. Wu JM, Williams KS, Hundley AF, et al. Occiput posterior fetal head position increases the risk of anal sphincter injury in vacuum-assisted deliveries. Am J Obstet Gynecol 2005; 193:525.

52. Benavides L, Wu JM, Hundley AF, et al. The impact of occiput posterior fetal head position on the risk of anal sphincter injury in forceps-assisted vaginal deliveries. Am J Obstet Gynecol 2005; 192:1702.

53. Center for Devices and Radiological Health. FDA Public Health Advisory: Need for caution when using vacuum assisted delivery devices. http://www.fda.gov/MedicalDevices/Safety/AlertsandNotices/PublicHealthNotifications/ucm062295.htm

54. Rajasekar D, Hall M. Urinary tract injuries during obstetric intervention. Br J Obstet Gynaecol. 1997;104(6):731.

55. Muraca GM, Sabr Y, Lisonkova S, Skoll A, Brant R, Cundiff GW, Joseph KS. Perinatal and maternal morbidity and mortality after attempted operative vaginal delivery at midpelvic station. CMAJ. 2017;189(22):E764.

56. American College of Obstetricians and Gynecologists, Society for Maternal-Fetal Medicine. Obstetric care consensus no. 1: safe prevention of the primary cesarean delivery. Obstet Gynecol. 2014;123(3):693.

57. Liabsuetrakul T, Choobun T, Peeyananjarassri K, Islam QM. Antibiotic prophylaxis for operative vaginal delivery. Cochrane Database Syst Rev. 2017;8:CD004455. Epub 2017 Aug 5.