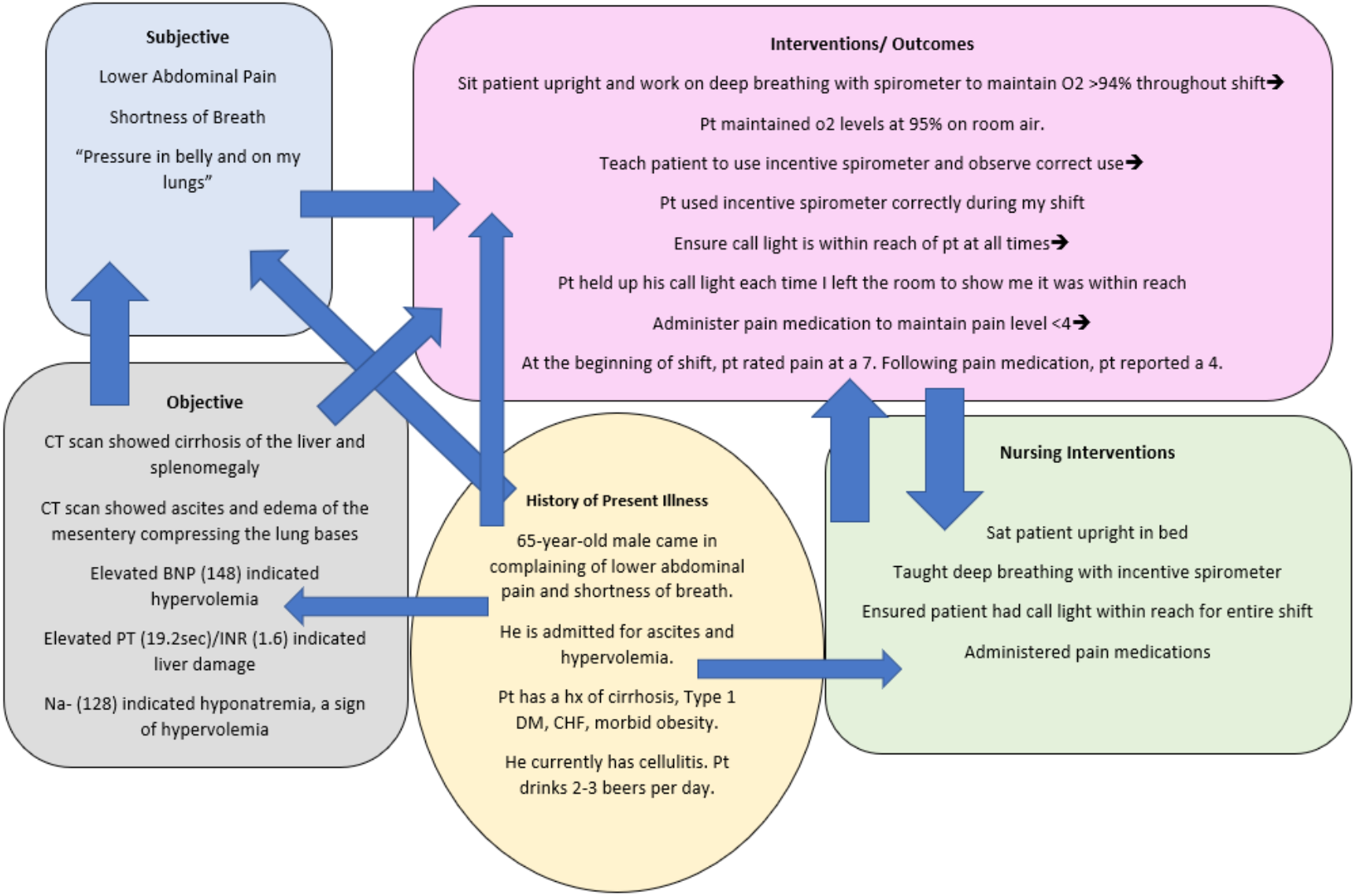
Subjective
Lower Abdominal Pain
Shortness of Breath
"Pressure in belly and on my lungs"
Interventions/ Outcomes
Sit patient upright and work on deep breathing with spirometer to maintain O2 >94% throughout shift➔
Pt maintained o2 levels at 95% on room air.
Teach patient to use incentive spirometer and observe correct use➔
Pt used incentive spirometer correctly during my shift
Ensure call light is within reach of pt at all times➔
Pt held up his call light each time I left the room to show me it was within reach
Administer pain medication to maintain pain level <4➔
At the beginning of shift, pt rated pain at a 7. Following pain medication, pt reported a 4.
Objective
CT scan showed cirrhosis of the liver and splenomegaly
CT scan showed ascites and edema of the mesentery compressing the lung bases
Elevated BNP (148) indicated hypervolemia
Elevated PT (19.2sec)/INR (1.6) indicated liver damage
Na- (128) indicated hyponatremia, a sign of hypervolemia
History of Present Illness
65-year-old male came in complaining of lower abdominal pain and shortness of breath.
He is admitted for ascites and hypervolemia.
Pt has a hx of cirrhosis, Type 1 DM, CHF, morbid obesity.
He currently has cellulitis. Pt drinks 2-3 beers per day.
Nursing Interventions
Sat patient upright in bed
Taught deep breathing with incentive spirometer
Ensured patient had call light within reach for entire shift
Administered pain medications