Hazelyn Hunter

P-atrial contraction
QRS-ventricals close
T-refills

The EKG waveform consists of:

- P Wave: Represents atrial depolarization ← in the atria
- QRS: Represents ventricular depolarization
- T Wave: Represents ventricular repolarization

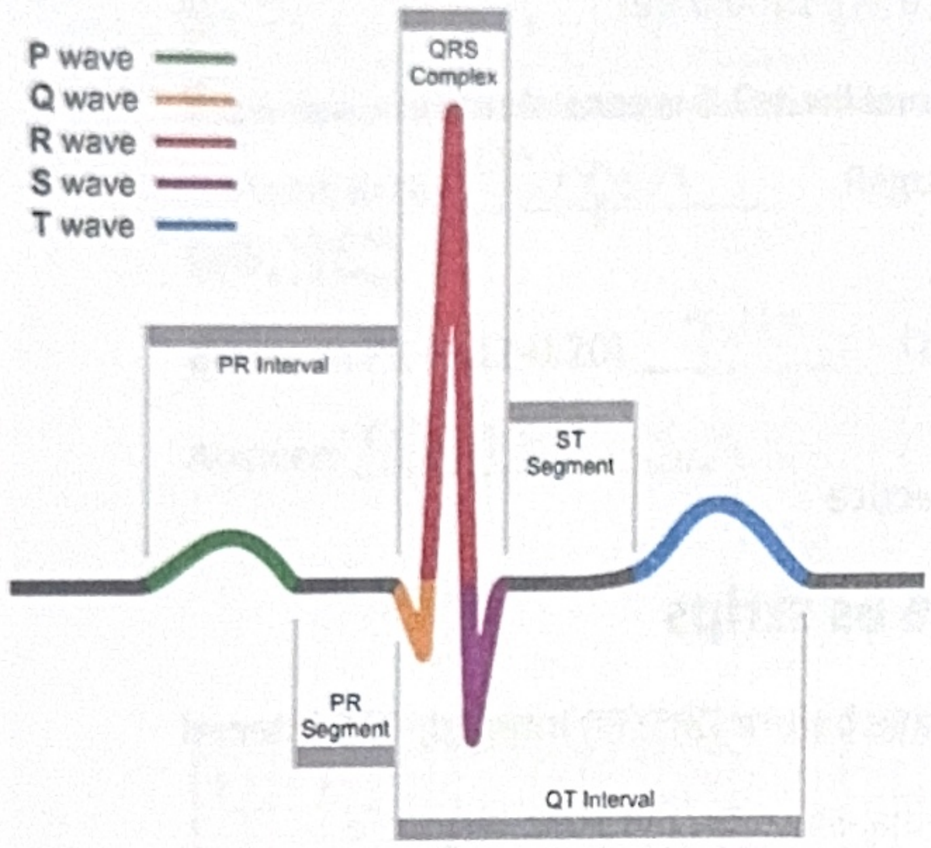

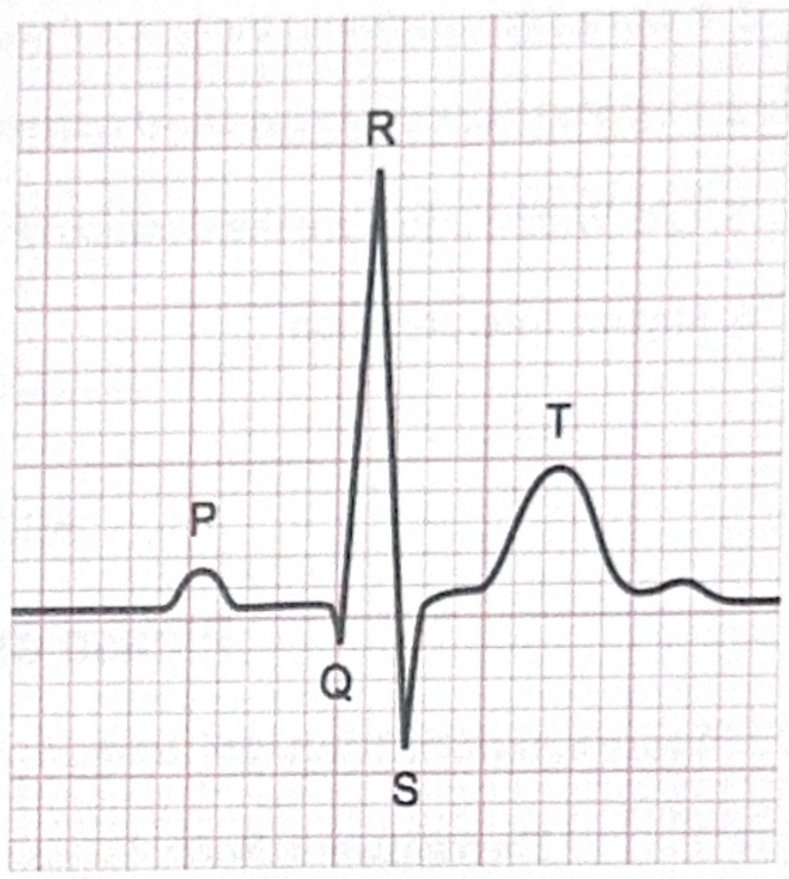

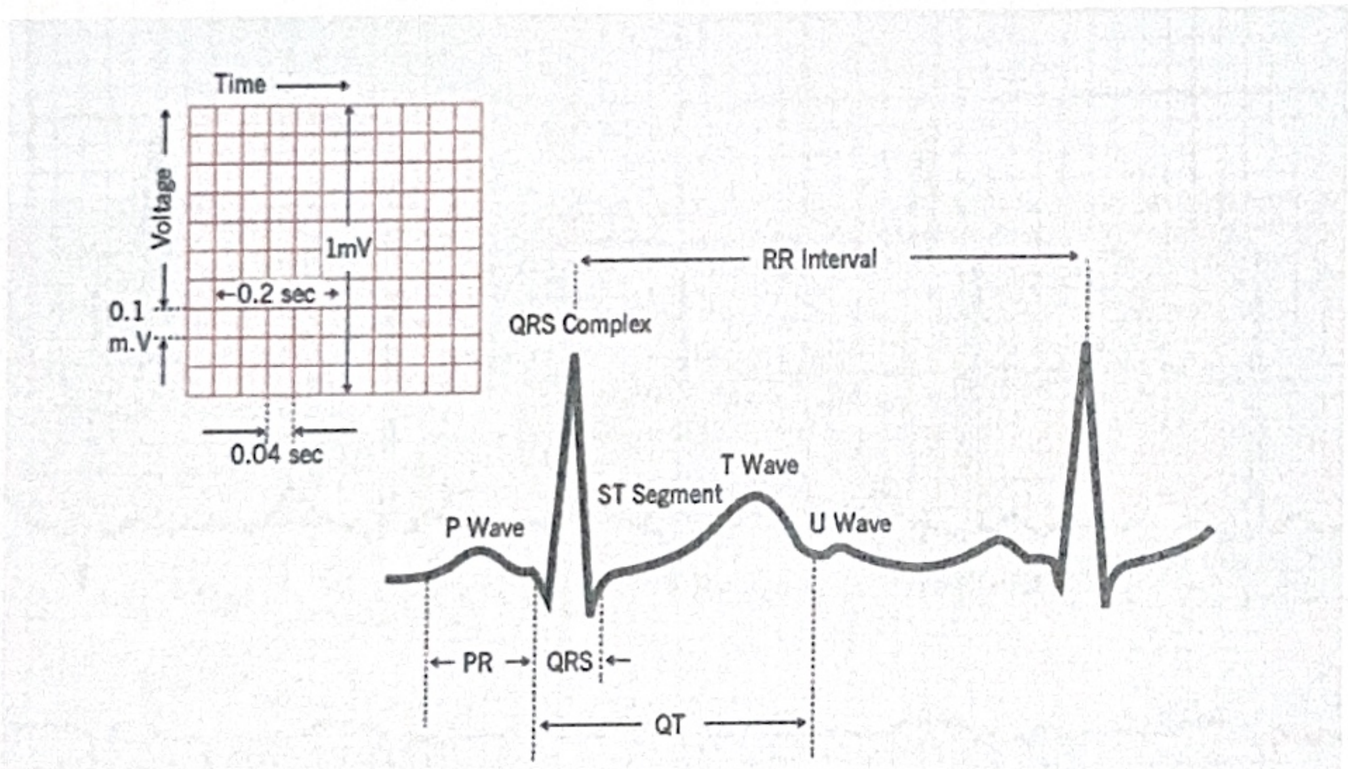

Reproduced with kind permission from F G Yanowitz
© University of Utah, and Intermountain Healthcare

- 1 small square on an ECG trace (at 25 mm/s speed) = 0.04 s
- **PR interval** 0.12–0.20 seconds (3–5 small squares)
- **QRS complex** 0.06–0.12 seconds (1.5–2.5 small squares)- **if Bradycardia could be slightly prolonged at slower rates**

Six Basic Steps for Rhythm Interpretation

1. Rate: (Calculate the heart rate (HR) or note the HR from the monitor)
2. Regularity: (Measure the regularity or rhythm of the R waves)
3. P-wave Examination: Is there one P wave before each QRS? (there should be)
4. P to R Interval: (Measure the P to R interval - Is it within normal limits? It is consistent?)
5. QRS Width: (Measure the duration of the QRS complex)
6. Rhythm Interpretation

N321 Adult Health EKG Practice

Please assume these are 6s strips

Please determine heart rate, irregular or regular rhythm, P wave before QRS, PR interval, QRS interval

Then answer if Normal sinus rhythm, Sinus Bradycardia, Sinus Tachycardia, Asystole

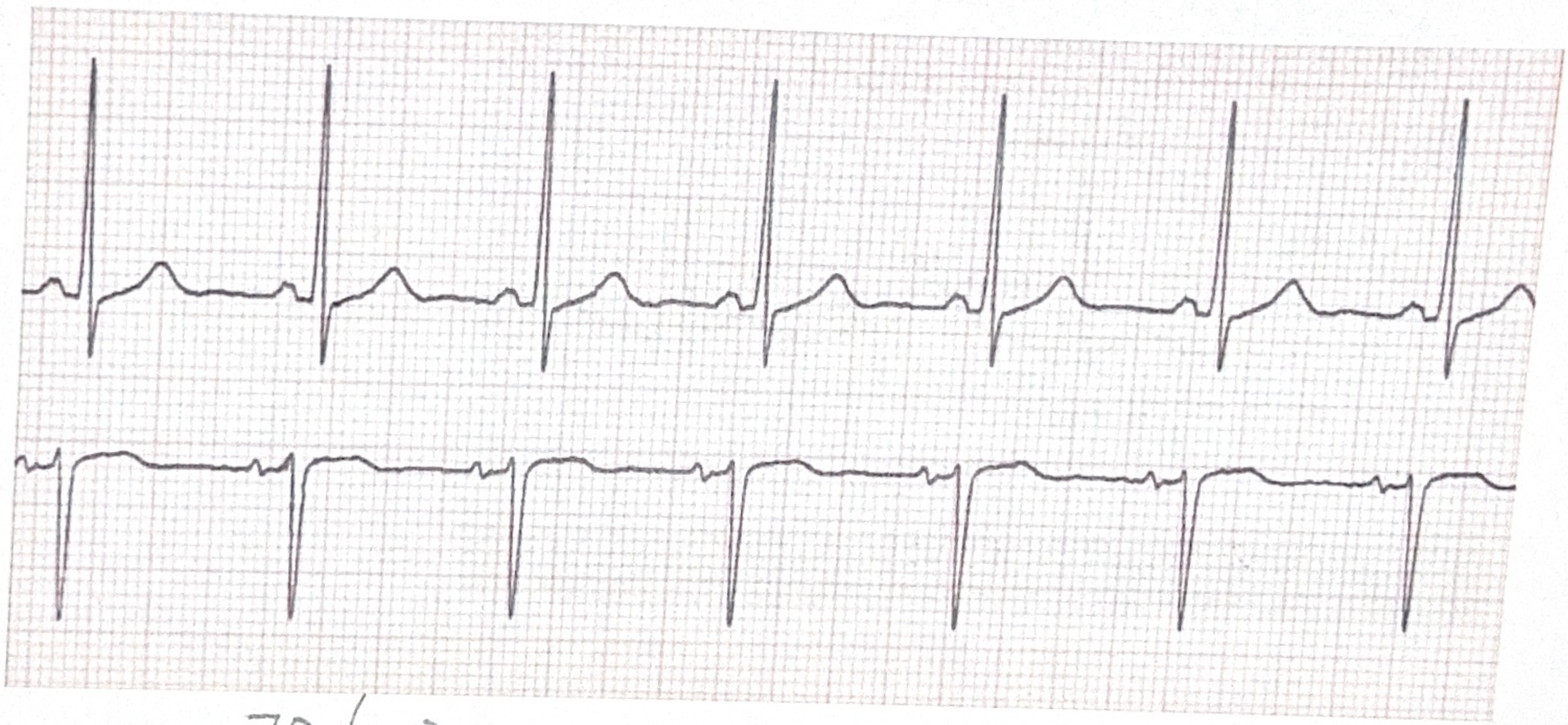

1. Heart Rate 70 (7x10) Regular or irregular regular P wave before each QRS yes

Between PR (0.12-0.20) 0.12 QRS 0.06-0.12 0.08

Answer: normal sinus rhythm

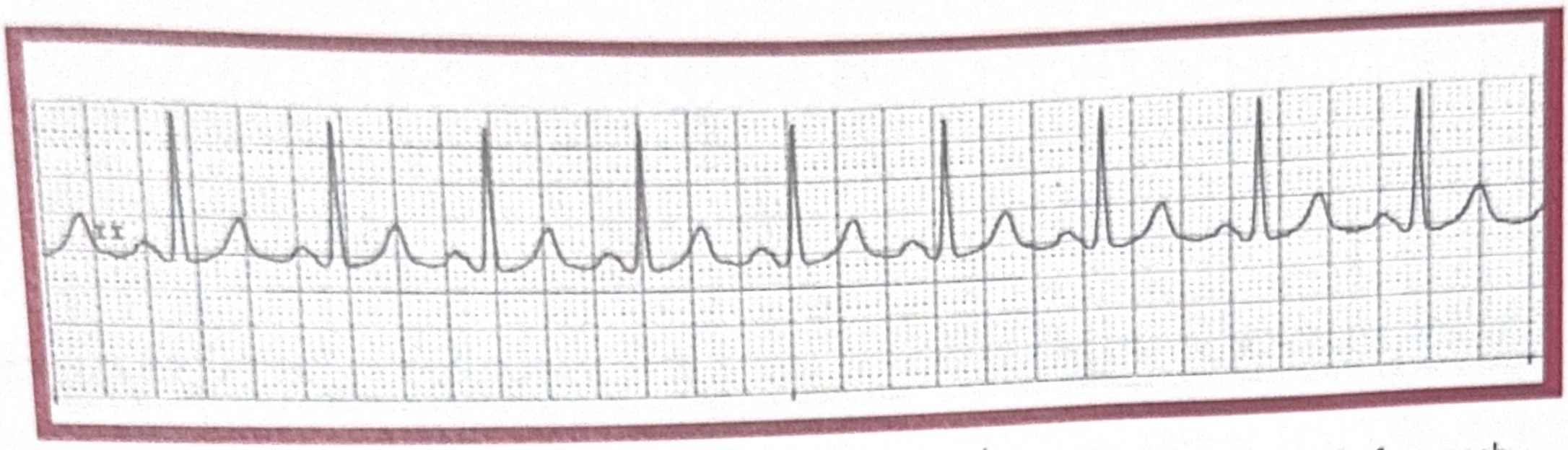

2. Heart Rate 90bpm Regular or irregular regular P wave before each QRS yes

Between PR (0.12-0.20) 0.16 QRS 0.06-0.12 0.08

Answer: normal Sinus

3. Heart Rate 30bpm Regular or irregular regular P wave before each QRS yes

Between PR (0.12-0.20) 0.20 QRS 0.06-0.10 0.08

Answer: Sinus Bradycardia

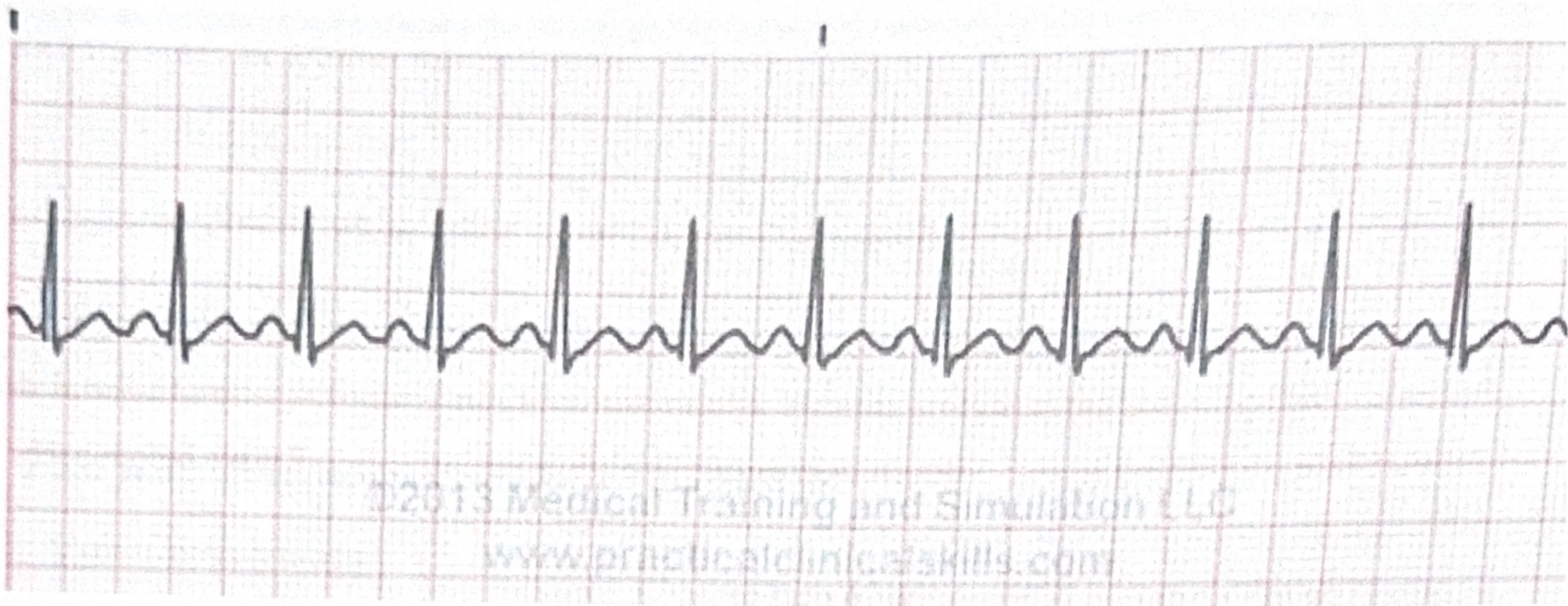

4. Heart Rate 130 bpm Regular or irregular regular P wave before each QRS yes

Between PR (0.12-0.20) 0.16 QRS 0.06-0.12 0.08

Answer: Sinus tachycardia

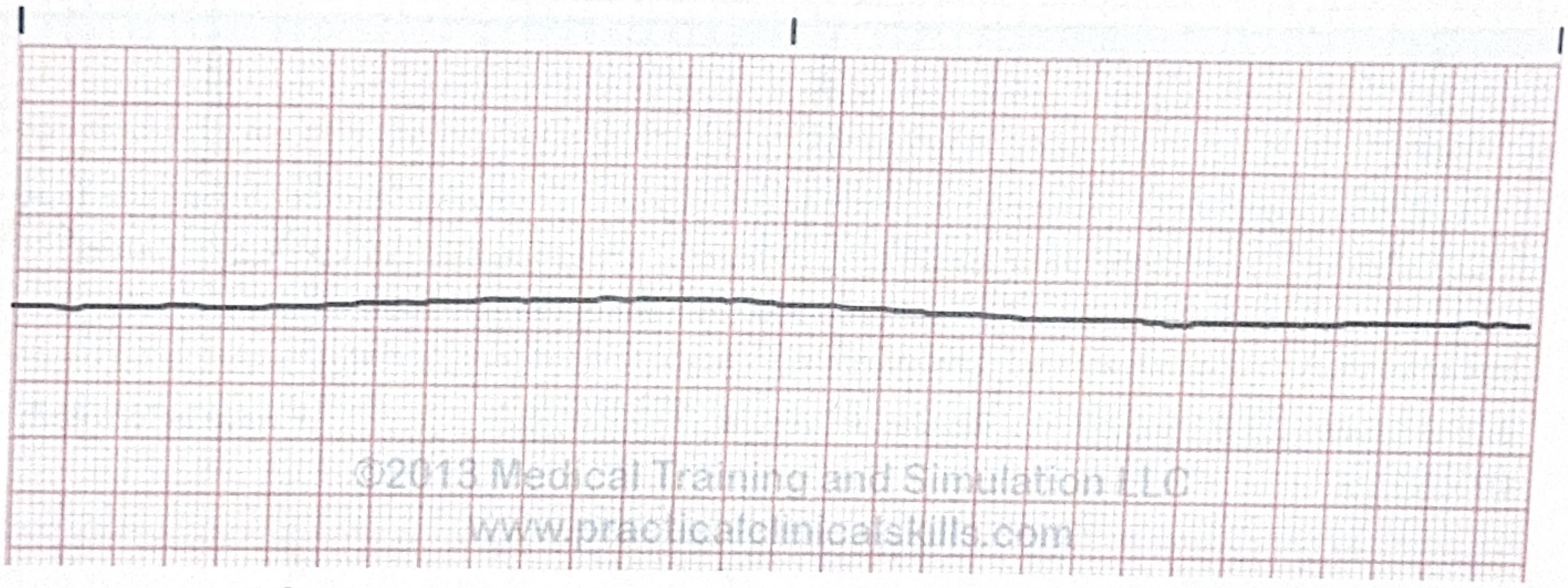

5. Heart Rate 0 Regular or irregular irregular P wave no

Answer: Asytole

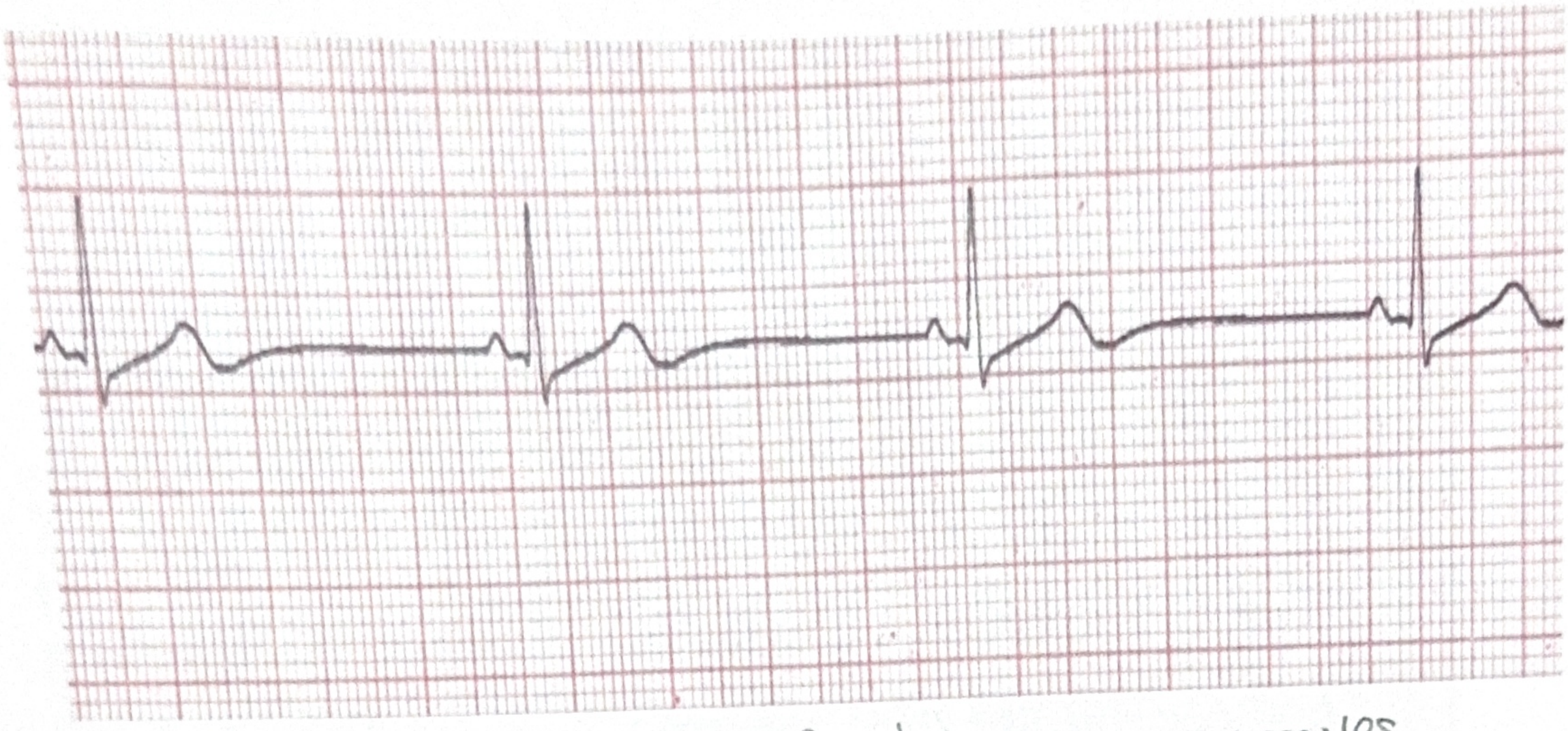

6. Heart Rate 40 bpm Regular or irregular regular P wave before each QRS yes

Between PR (0.12-0.20) 0.16 QRS 0.06-0.12 0.04

Answer: Sinus bradycardia

7. Heart Rate 140 bpm Regular or irregular Regular P wave before each QRS yes

Between PR (0.12-0.20) 0.16 QRS 0.06-0.12 0.04

Answer: Sinus tacycardia

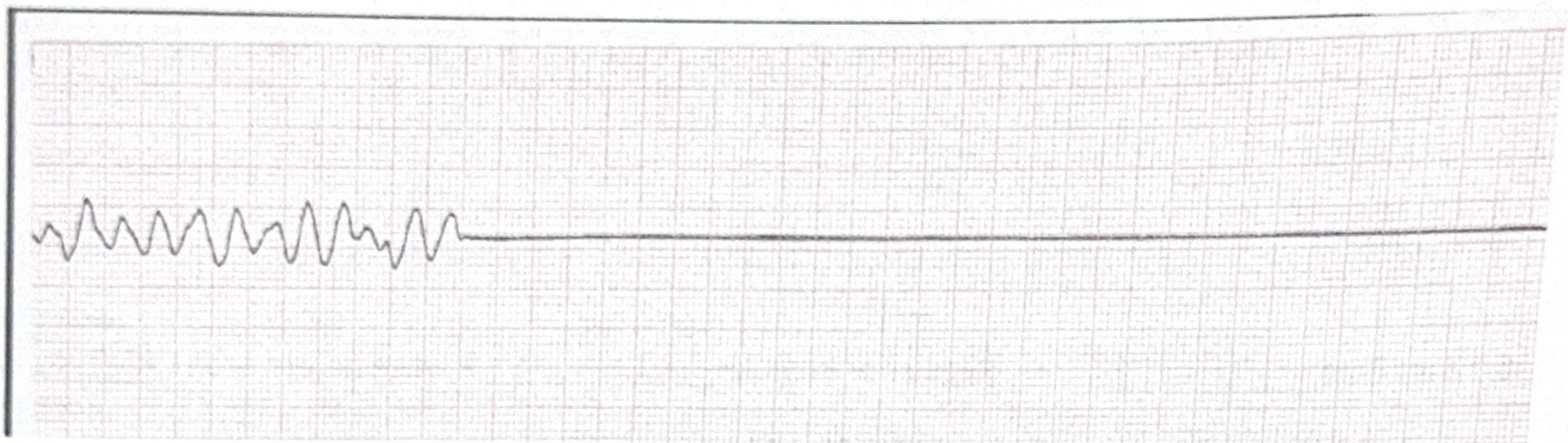

8. Heart Rate ___—___ Regular or irregular ___—___ P wave ___—___

Answer: Asytole

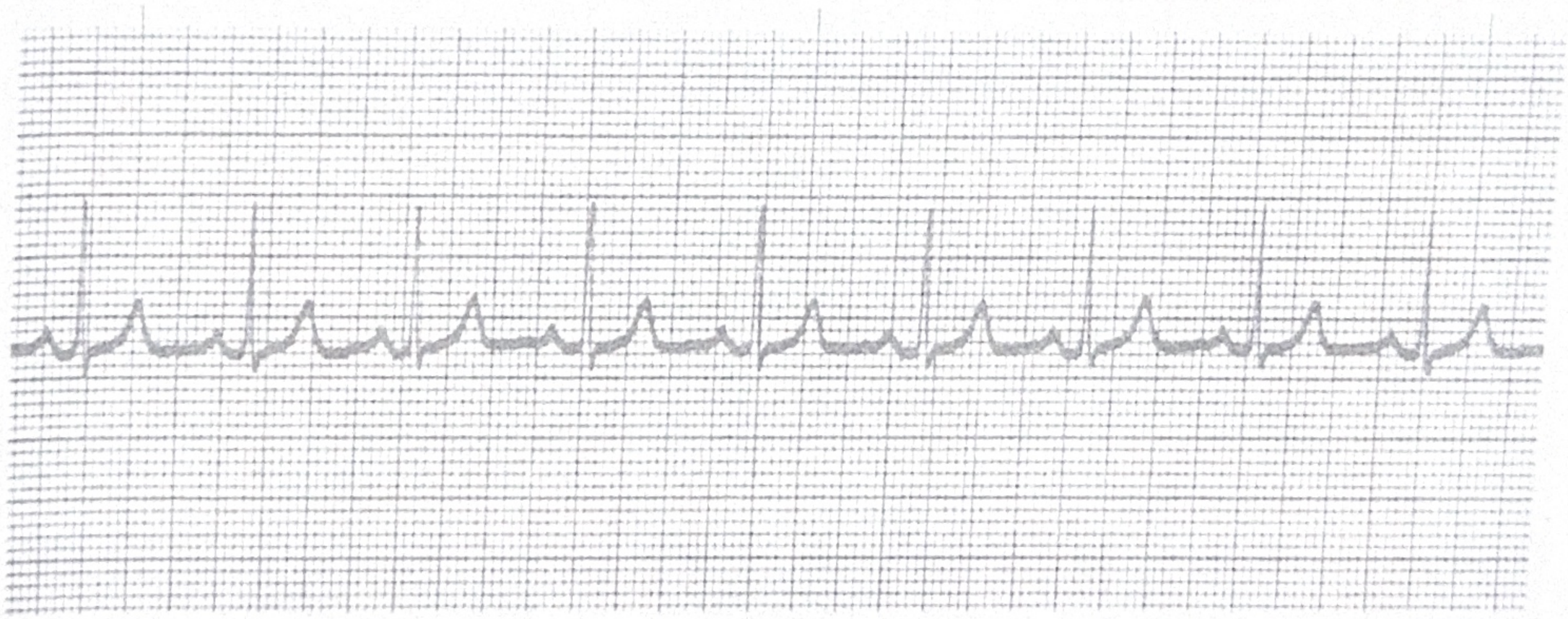

9. Heart Rate ___90___ Regular or irregular ___Regular___ P wave before each QRS ___yes___

Between PR (0.12-0.20) ___0.16___ QRS 0.06-0.12 ___0.04___

Answer: normal Sinus

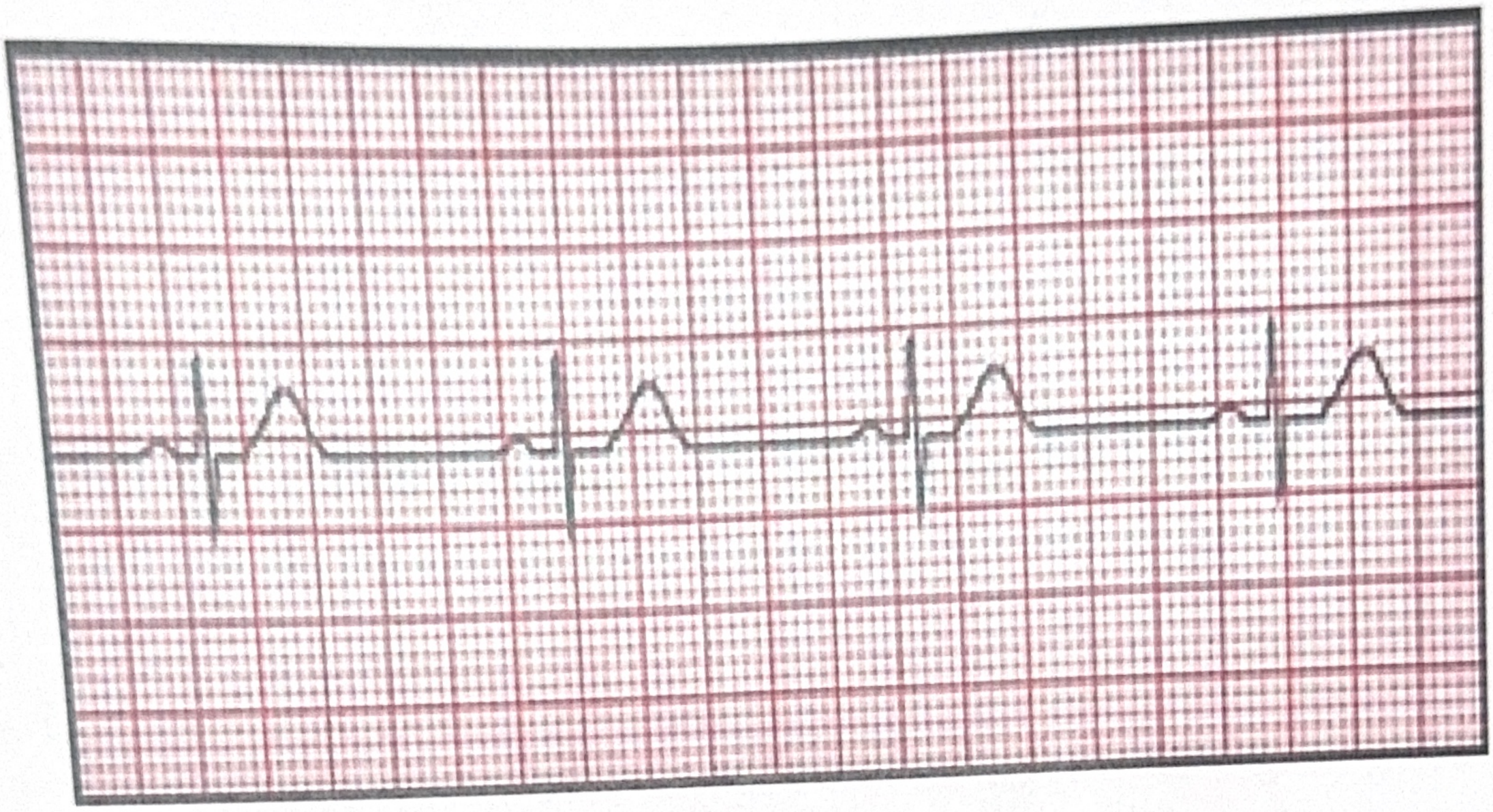

10. Heart Rate 40bpm Regular or irregular Regular P wave before each QRS yes

Between PR (0.12-0.20) 0.20 QRS 0.06-0.12 0.04

Answer: Sinus bradycardia