Group #1

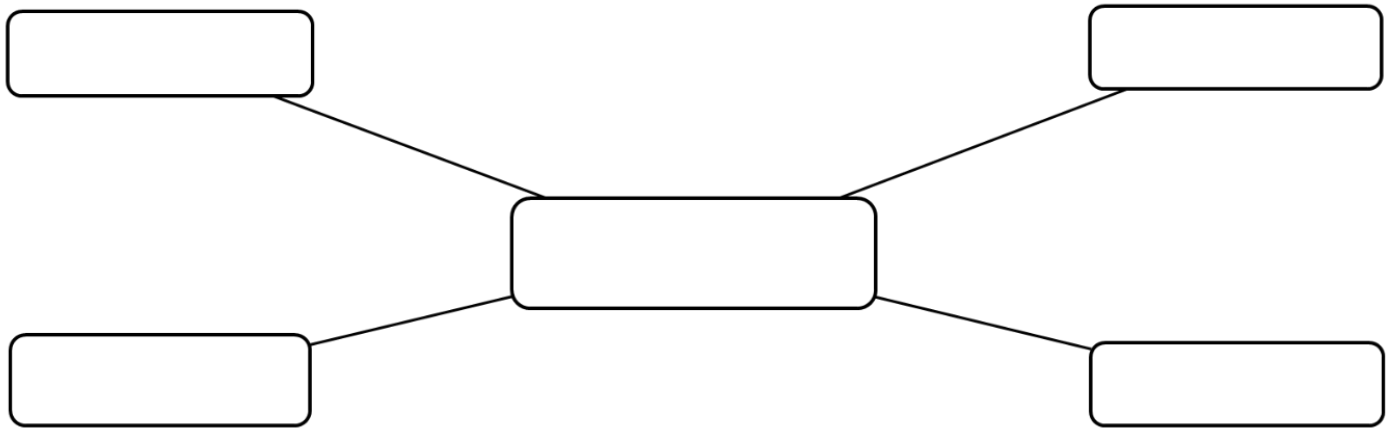

Action to Take:
- Initiate contact precautions
- Begin antibiotic treatment as prescribed
- Start IV
- Place patient on 2L O2

Condition most likely experiencing:
- Osteopenia
- Osteoporosis
- Osteomyelitis
- Osteoarthritis

Parameters to monitor:
- Blood pressure
- Area of necrotic tissue
- Sensation in left foot
- Heart rate

Group #1

- Bob is a 78-year-old Caucasian male with diabetes type 2, a left foot ulcer and dementia who came to the emergency department because he had increased pain in left foot, chills, fever and feeling weaker the past two days.
- His wife noticed an increase in redness and swelling of his chronic left foot ulcer.
- His left great toe is black with an open stage III ulcer 1x1 cm on the top of his left foot. Surrounding tissue is bright red and extends from his left foot to his lower left leg.
- Initial vital signs:
    - T: 101.5 F/38.6 C
    - P: 98
    - R: 22
    - BP: 108/70
    - O2 sat: 94% room air

Instructions:

Use the bowtie figure attached and decide which condition the patient is most likely experiencing.

Then select two of the most important actions to take and two of the most important parameters to monitor.

Group #2

- Bob is a 78-year-old Caucasian male with diabetes type 2, a left foot ulcer and dementia who came to the emergency department because he had increased pain in left foot, chills, fever and feeling weaker the past two days.
- His wife noticed an increase in redness and swelling of his chronic left foot ulcer.
- His left great toe is black with an open stage III ulcer 1x1 cm on the top of his left foot. Surrounding tissue is bright red and extends from his left foot to his lower left leg.
- His left great toe is black with an open stage III ulcer 1x1 cm on the top of his left foot. Surrounding tissue is bright red and extends from his left foot to his lower left leg.
- His initial WBC: 18.5, lactate: 1.8, and creatinine: 1.7. A CT of his left foot confirmed osteomyelitis in the left great toe.
- He is admitted to the med/surg floor and to be started on piperacillin/tazobactam IVPB and vancomycin IVPB.
- He is scheduled to have his left great toe amputated in surgery tomorrow.

Instructions:

Highlight which information would be relevant to the present condition.

Group #3

- Bob has been married for 55 years and is cared for by his wife, Pam, who is a retired nurse. They have no children. His dementia has progressed, and Bob no longer recognizes his wife. He has become more difficult for his wife to manage at home.
- Bob is DNR/DNI. Palliative care was consulted to clarify goals of care and communicated that Bob is at high risk for decline after surgery and may require skilled care after discharge. Pam is stern and communicates that she knows her husband best and insistent that he will come home after surgery no matter what.

Instructions:

Highlight which information from the social history would be relevant to the present condition of osteomyelitis.

Group #4:

- Bob had surgery earlier this morning to remove the left great toe and had no complications.
- His most recent set of vital signs were:
  - T: 99.8 F/37.7 C
  - P: 78 (irreg)
  - R: 20
  - BP 142/86
  - O2 sat 95% 2 liters NC
- The PACU nurse reports that he is awake but is not oriented to person, place, time or location.

Instructions:

Highlight which vital signs would be relevant to the present condition of osteomyelitis post-surgical amputation.