R. B. Turnbull Jr. MD WOC Nursing Education Program

Mini Case Studies: Ostomy

Cleveland Clinic

Student Name & Date: Lisa Katrowski 10/30/2025
Reviewed by: Patricia A. Slachta 11/14/25
Score: 28.5 /40 Lisa, you missed the second part of question 9, missed the point of question 10, & used a pouch that is too small in question 11. As with the wound scenarios, look at each of these where you missed information and add to the question in another color & return through the Dropbox. Also, please use the numbers directly from the catalogs (all are available on line) as you have too many numbers in your product choices.
Score for resubmission : XX-1 resubmit /40 =

This assignment focuses on applying the assessment of an individual with an ostomy to pouching principles. First, basic principles are identified. Then, principles are applied to clinical situations. *Answer the four questions below* and then read the instructions on the next page

To support your actions, include at least three relevant references in addition to the course textbooks. (Use 7th edition APA formatting)

1. Identify the nursing orders for changing a pouching system on a person with no peristomal skin breakdown. **(2 points)** 2
   [1.] Remove the pouch from the ~~stomach~~abdomen, gently pulling back and checking the barrier to see if they have leakage.
   1.[2.] Cleanse skin with warm water and gently dry.
   2.[3.] Inspect peristomal skin.
   3.[4.] Cut the barrier to fit the stoma. Use measuring tools or trace the pattern of the stoma onto plastic to then transfer to the barrier to cut to fit the stoma, making sure that you have ¼ inch around the stoma.
   4.[5.] Apply skin prep to peristomal skin and allow to dry
   5.[6.] Apply the pouching system, be sure to check edges, making sure the appliance is fitting well and not damaging the stoma.
   6.[7.] Press firmly, starting from the center of the barrier by the stoma and working to the outer edge to ensure the appliance has adhered to the skin.
   7.[8.] Empty the pouch when 1/3 full.

2. Identify nursing orders for changing a pouching system on a person with peristomal skin breakdown. **(2 points)** 2
   [1.] Remove the pouch from the ~~stomach~~, gently pulling back and checking the barrier to see if they have leakage.
   1.[2.] Cleanse skin with warm water and gently dry.
   2.[3.] Inspect peristomal skin.
   3.[4.] Identify the cause of the peristomal breakdown.
   4.[5.] If skin has maceration or open areas, clean the area and dry well.
   5.[6.] Apply stoma powder to the area, dust off excess powder, and dab with 3m barrier film to seal in powder and seal open areas.
   6.[7.] If the peristomal plane has a crease, fill this area in with stoma paste or use an Eakin ring to help fill in this area to build a flat plane to attach the pouch to.

7.[8.] Cut the barrier to fit the stoma. Use measuring tools or trace the pattern of the stoma onto plastic to then transfer to the barrier to cut to fit the stoma, making sure that you have ¼ inch around the stoma.
8.[9.] Apply skin prep to peristomal skin and allow to dry
9.[10.] Apply the pouching system, be sure to check edges, making sure the appliance is fitting well and not damaging the stoma.
10.[11.] Press firmly, starting from the center of the barrier by the stoma and working to the outer edge to ensure the appliance has adhered to the skin.
11.[12.] Empty the pouch when 1/3 full.

3. Identify nursing orders for changing a pouching system on a person with peristomal skin breakdown and the presence of satellite lesions. **(2 points)** 1

   1. Cleanse skin with warm water and gently dry.
   2. Inspect peristomal skin.
   3. Identify the cause. Use stoma powder or a fungal powder if necessary.you are giving choices, what does this skin indicate the issue is? Satellite lesions are a sign of a fungal rash. We would need to apply Nystatin powder to the area to help address the issues
   4. Apply Nystatin powder to the area, dust off excess powder, and dab with 3m barrier film to seal in powder and seal open areas.
   5. Cut the barrier to fit the stoma. Use measuring tools or trace the pattern of the stoma onto plastic to then transfer to the barrier to cut to fit the stoma, making sure that you have ¼ inch around the stoma.
   6. Apply skin prep to peristomal skin and allow to dry
   7. Apply the pouching system, be sure to check edges, making sure the appliance is fitting well and not damaging the stoma.
   8. Press firmly, starting from the center of the barrier by the stoma and working to the outer edge to ensure the appliance has adhered to the skin.
   9. Empty the pouch when 1/3 full.

4. Differentiate the standard wear barrier from an extended wear barrier. Identify the type of ostomy or situation where each type of barrier would be indicated, and provide a *specific* example for each. Identify manufacturer name, product name, and manufacturer product number. **(4 points)** 3

   A standard wear ~~pouch~~ barrier is the talking point here example would be a Coloplast Sensure flat standard wear easiclose wide outlet drainable pouch #6215521 1-piece cut-to-fit pouch. This pouch can stay on for 3 to 5 days. This pouch is good for stools that are more formed true~~. The pouches are a little softer and more pliable in use with moderate adhesion. They come in drainable and closed pouch systems~~. Coloplast makes multiple styles of extended wear; some are one-pieces and some are 2-pieces. They currently have a one-piece that is extended wear ~~with a wide outlet, a drainable pouch with a filter, which~~ is Coloplast Sensura xpor one piece extended wear ~~easiclose wide outlet drainable~~ # 6215981. These last longer and stay up to 7 days. They are still flexible and have a strong adhesive and are more resistant to erosion. There is a better product for more liquid stool, high output for ileostomy or urostomy.ok

   The standard wear barrier is designed for solid stool and absorbs moisture at a faster rate than the extended barriers. The longest this should stay on the skin is 5 days.
   Coloplast Sensara flat standard wear #15521
   Extended barriers are made of a different formula and have a stronger adhesion that makes them more resistant to eriosin and extended the time the product can stay on the skin up to 7 days
   Coloplast Sensura One Piece Extended Wear #15981

Coloplast Sensura convex light click barrier extended wear 2 piece pouch barrier #11012 and Sensura click midi drainable pouch with filter #11114

For each of the below ostomy patient case scenarios:

- Use the information provided to identify an ostomy pouching plan.
  - ***Be specific:*** It is important to note a pouching system is a skin barrier wafer and a pouch. A complete answer should include both unless otherwise indicated. **Include the manufacturer, manufacturer product number, and full product name**. Make sure to include accessory products as needed.
  - When providing the rationale: Describe abdominal characteristics, stoma characteristics, and one other reason why you would choose the specific system.
- The first half of the first case study has been completed for you below as an example.
- To support your actions, include at least three relevant references in addition to the course textbooks. (Use 7th edition APA formatting)
-
- **Example + Scenario 1**

55-year-old with a history of colon cancer. Colostomy was created 2 months ago and presents today in the ostomy clinic for assessment and management. Pt is very active and would like to consider a more flexible pouching system. Pt is changing his pouching system every other day because he is fearful of leakage.

Assessment: Stoma is pink, budded, and protrudes above skin level. No erythema on parastomal skin. No reports of leakage.

Identify a one and two-piece pouching system option along with rationale for choice.

Image courtesy of Wound, Ostomy, and Continence Nurses Society™ image library.

One Piece System: *Hollister Premier one-piece drainable pouch flat Flexwear barrier (**#8031)** with clamp closure,*

change every 5-7 days and PRN.

Rationale: *This system is flexible and matches the contours of this patient's abdomen. It is appropriate for budded stomas with an even peristomal plane and is manufactured for wear for multiple days.*

Two Piece option:

Skin Barrier wafer: Hollister 2 piece ostomy system flexwear standard wear flat barrier #~~5014202~~

Pouch: New image lock and roll microseal closure drainable pouch integrated waterpro~~o~~ff af300 filter and belt tabs #~~50~~18112 you have too many numbers on all of your products – check out the catalogs or do a web search – too many numbers. For instance if you search for
what is the product number for a Coloplast Sensura convex light standard wear easiclose wide outlet you get 15606! And that is what the catalog says too

Rationale: This barrier is allows the patient to hear the click when it has snaped into place. It is extended wear allowing it to be worn for more days and more resistant to stoma output and breakdown. It has a tape border to allow the patient to feel more secure with the products and the edge. The pouch chosen will allow It to click in place reduce gas buildup reduce odor and has belt tabs if patient wants to add a belt for extra security. Anostomy belt number #507300

2/2 points

Scenario 2

42-year-old with Laparoscopic colostomy stoma placement on soft, obese abdomen, 1 week post op.

Assessment: Stoma pink, budded, and protruding. Edema and necrosis circumferential at stomal edge. Serosanguineous drainage in pouch. Skin barrier wafer removal notes being cut too small, restricting and causing trauma to the stoma.

Identify a one and two-piece pouching system option along with a rationale for choice. Image courtesy of Wound, Ostomy, and Continence Nurses Society™ image library.
One Piece option: Coloplast SenSura Mio Extended wear one piece easiclose wide drainable pouch flat #6210481 This is still a cut-to-fit, but the diameter is 10 -55mm. **Rationale: This is still a cut-to-fit; if it is post-op week one, the stoma is still swollen and has not yet started to stabilize. The patient's stoma should still decrease in size over time. Patient needs to be reeducated on how to cut the bag or have help in doing this process until they can do it on their own. We could order precut bags, but I feel this is too early since it is only post-op week one. If the patient is unable to learn how to cut properly, it might be our next option.**
Two Piece option: Coloplast Sensura Mio Flex two-piece pouching system **Skin Barrier Wafer:** SenSura Mio Flex extended Wear barrier flat~~y~~ #~~62~~10571 (10-68mm) **Pouch:** SenSura Mio Flex Easiclose wide drainable pouch #~~62~~12283 **Rationale: This is a two-piece system for the patient. It is still a flat barrier since the patient's stoma is budded. The pouch number chosen is a transparent bag-yes good thought; this way, the patient can monitor more closely to make sure that the stoma color is good and spot signs of trouble faster.**
4/4 points

Scenario 3

56-year-old obese individual with ruptured diverticulitis. A red rubber catheter in place as a bridge for the loop ostomy. Stoma is slightly budded and red. Peristomal skin with erythema and partial thickness wound 4-7 o'clock Etiology may be due to trauma from red rubber catheter movement.

Image courtesy of Wound, Ostomy, and Continence Nurses Society™ image library.

Pouching recommendations:

1. Clean peristomal skin well and dry.
2. Apply stoma powder to erythema and open areas. #rrsns92301 Safe and simple ostomy skin barrier powder.
3. Dab in powder with protective skin barrier wipes Coloplast #622041.the barrier wipes 30/box are 120115

[4.] Apply Coloplast Sensura convex light standard wear easiclose wide outlet drainable pouch with filter cut to fit #~~62~~15606.

4.[5.] Making sure to cut to the correct size, start by pressing the barrier from inner to out to get a good seal on the pouch.

Rationale: Need to protect the open area of skin with stoma powder and a barrier protector to allow the area to heal. Since the bridge is rubbing skin and the stoma is not budded more a light convex will help to push the stoma out further and help the bridge from not sitting on the skin and causing irritation. And you are putting the wafer under the bridge?

We could place a small Eakin ring #0423 to place under the bridge to help protect the skin from irritation and rubbing.

2/2 points

Scenario 4

66-year-old obese individual with a loop ileostomy stoma in an abdominal fold. Appliance leakage causing contact dermatitis. Wear time has been less than 8 hours. Irritation is painful.

Image courtesy of Wound, Ostomy, and Continence Nurses Society™ image library.

Pouching Recommendations:

1. Cleanse skin with warm water and gently dry.
2. Inspect peristomal skin and identify the cause of the peristomal breakdown.
3. Apply stoma powder to the area #rrsns92301 Safe and simple ostomy skin barrier powder.
4. Dust off excess powder, and dab with barrier film Coloplast #120115 to seal in powder and seal open areas.
5. The peristomal plane has a crease. Fill this area in with stoma Bravo paste #12050 or Bravo strip #6226555 to help fill in this area to build a flat plane to attach the pouch to.
6. Cut the barrier to fit the stoma. Use measuring tools or trace the pattern of the stoma onto plastic to then transfer to the barrier to cut to fit the stoma, making sure that you have ¼ inch around the stoma.
7. Apply Coloplast Sensura convex light standard wear easiclose wide outlet drainable pouch with filter cut to fit #15606.
8. Apply the pouching system, be sure to check edges, making sure the appliance is fitting well and not damaging the stoma.
9. Press firmly, starting from the center of the barrier by the stoma and working to the outer edge to ensure the appliance has adhered to the skin.
10. Apply a Coloplast Bravo belt #4215, making sure to secure the device and help push the stoma forward.
11. Empty the pouch when 1/3 full.

Rationale: First, we must clean and treat the damaged area. We need to build up the creases on the side of the stoma with Bravo strips to fill in the creases on the stomach. It will help prevent more leakage from the bag, as well as give us a flatter plane to attach the pouch. A light convex pouch helps to push the stoma out so the stool coming out will fall into the bag. A belt will help secure the pouch and also help the convex pouch push the stoma out more.

2/2 points

Scenario 5

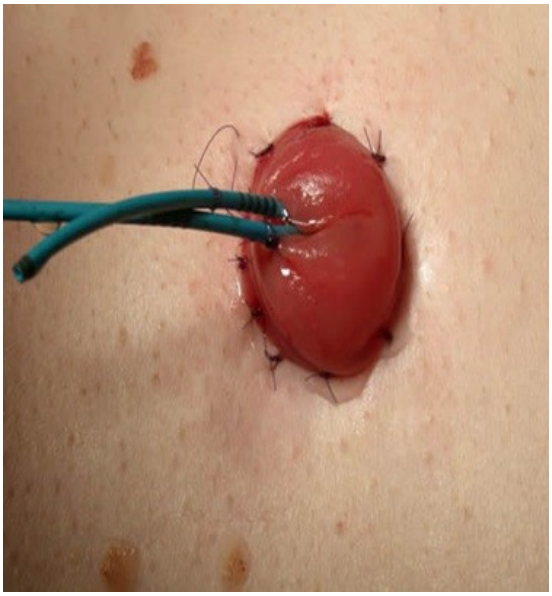

A 76 year old patient is seen on a urology floor for a initial post operative visit. Urostomy noted with 2 stents in place, draining clear/pink tinged urine bilaterally. Surgeon requesting to be able to access stents. Pouching system removed was a one-piece post operative pouch. The patient is not yet ready for education and is currently non-ambulatory.

Image courtesy of SER, 2006

Pouching option: 2-piece Hollister new image high output drainable without filter #5018013 and new image flextend extended wear flat skin barrier #5014603. This is a two-piece system that will allow for easy drainage of the urostomy and still allow easy access to the tubes without taking of the whole bag every time. It is able to be removed and then snapped back into place or a new pouch.

Additional accessories to consider: Since this is a 76-year-old patient, we need to think about the ease of change for them. Will a 2-piece or 1-piece be easier? How is their hand-eye coordination, as well as dexterity in the hands? They could also benefit from maybe a precut bag once the stoma is mature. For this patient, we should also consider a leg bag for the day, and having a large urinary drainage bag for nighttime so they do not have to worry about access to a facility or waking up multiple times a night to empty the pouch.

2/2 point

Scenario 6

46-year-old presents to the ostomy clinic with peristomal redness to periphery. Patient is currently in a one piece system with a 12" pouch. Irritation limited to appliance tape collar region. Satellite lesions present. Stoma is budded and round. States has had their ileostomy for 6 months and has not had any problem until recently after Home Health changed the products. Patient also expresses the pouch is too long with the end of the pouch falling into the groin area Abdominal space is small with short distance from stoma to groin.

Image courtesy of Wound, Ostomy, and Continence Nurses Society™ image library.

Pouching Recommendations: First, we need to find out what supplies the patient was previously using and what products they are using now. We can do a patch test of different products on another area of the patient's skin to see which product they may have sensitivity or an allergy to. True but more complicated than it needs to be. What can you do for this patient before you begin patch testing?

Ask the patient if any other changes have been made, and ask what they are cleaning the area with. Have us talk it step by step to see if we can figure out what the issue is. We can first just try to remove the pouch and clean the area, and apply Nystatin over the fungal rash to help repair the skin. Also, check the pouch during the removal to see if the patient is leaking in any one area and make sure that the abdominal plane is flat.

Next, we need to inspect the skin and find any problems. If the skin has satellite lesions and it appears to be a fungal rash, we need to treat this area with nystatin powder and do the crusting technique on the area.

1. Cleanse skin with warm water and gently dry.
2 Inspect peristomal skin.
[3] Identify the cause. Use stoma powder ~~or a fungal powder if necessary.~~
3[4] Apply powder to the area, dust off excess powder, and dab with 3m barrier film to seal in powder and seal open areas.
4[5] Cut the barrier to fit the stoma. Use measuring tools or trace the pattern of the stoma onto plastic to then transfer to the barrier to cut to fit the stoma, making sure that you have ¼ inch around the stoma.
5[6] Apply the pouching system, be sure to check edges, making sure the appliance is fitting well and not damaging the stoma.

6[7] Press firmly, starting from the center of the barrier by the stoma and working to the outer edge to ensure the appliance has adhered to the skin. 7[8] Empty the pouch when 1/3 full.
Rationale: Testing the product will allow us to be sure what has really cause the skin breakdown issue. I would want to go back to the previous product and use that until we can test and verify if the patient is sensitive or allergic to new product. I would do this seeing the patient had an established routine for 6 months and was not having problems with that product. We need to address the redness the patient has on the abdomen. Nystatin will help heal the fungal rash infection. We still need to give education to the patient on the proper care of the area and make sure that the products they are using to clean the area are appropriate.
Provide an alternative pouching recommendation to address the patient's concern regarding pouch length. Regarding the length of the pouch, after I identify the pouch the patient was using last, we can then order a shorter length of the pouch. We could also measure the area and figure out what will best fit the patient and their current lifestyle. Pouch length varies in size they have 11 ½ inch Coloplast sensure flat standard wear 3 6215521 ,10 ½ inch 2 piece sensura click easy close #6211115 , and even a 8 ½ closed pouch sensura flat standard #6215480. So shorter the better here..just FYI there are shorter pouches too. Coloplast Sensura Mio Flex easiclose Midi #12281 and Sensura mio click barrier #10531
2/3 points

Scenario 7

An 80 year old legally blind patient presents to ostomy clinic due to peristomal hernia causing peristomal skin breakdown. Abdomen is firm. Appliance wear time has decreased since parastomal hernia development. Stoma is flush with skin. Os at 4 o'clock area. Complains of odor. "The odor is really bad when I empty the pouch".

Image courtesy of Wound, Ostomy, and Continence Nurses Society™ image library.

Pouching Recommendations: Coloplast Sensura Mio Extended wear maxi drainable pouch convex flip #6218305. This product has a curved, star-shaped barrier to help conform to the bulges in the area. This will help push out the stoma and have the drainage be directed into the bag.

Rationale: We need to get a good seal and push the stoma out.

Odor Management Strategies: We can go over the patient's diet and food preferences to see if the patient needs education on the types of food that can cause odor.good! We can order from Coloplast Bravo lubricating deodorant #6212060. Then educate the patient on how to use the product and apply it in a clean empty bag, rub around to coat the bag inside after application of each bag.

3/3 points

Scenario 8

A pediatric Individual presents to the emergency room with stoma prolapse. Caregiver expresses inability to apply pouching system related to stomal protrusion. Stoma is red and healthy. No peristomal irritation.

Identify one pouching system with rationale for choice along with one consideration with appliance application specific to a prolapsed stoma.

Image courtesy of Wound, Ostomy, and Continence Nurses Society™ image library.

Pouching Recommendations: Sensura mio Extended wear one piece easiclose wide drainable pouch flat #6210481

Rationale: If the stoma has prolapsed and they can no longer fit into a pediatric pouch, we need to apply a larger adult pouch for this patient.

Further Considerations: I would talk with family and see if they feel a 2-piece might be a better option. This way, the barrier could stay on longer, and they can remove or remove the pouch to clean or access, and try to extend the pouch wear time for the patient and protect the skin. What about reducing the prolapse; also making sure they are cutting the hole large enough

Education with the parents is important. Make sure the bag is cut to the right size and modify it if needed to fit the stoma into the larger pouch. To help with the prolapsed stoma, the baby can be placed on the back with a cold cloth and light pressure to see if the stoma will retract. You can also try sprinkling sugar onto the stoma. (Wound, Ostomy and Continence Nurses Society et al., n.d.).

2.5/3 points

Scenario 9

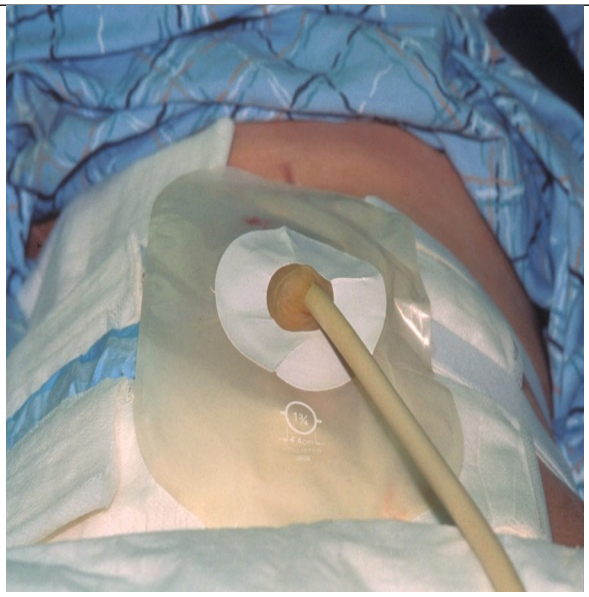

Image courtesy of Judy Mosier, MSN, RN, CWOCN

You are consulted to see a patient with a new colostomy. Upon entering the room, you note there is an indwelling catheter in the stoma. Nursing reports pouch leakage as the hole in the pouch for the tube is cut to fit the stoma resulting in a "big hole" in the front of the pouch. The surgeon's request is to continue to pouch the stoma while pulling the tube through the pouch.

Describe how you will secure the tube while separately pouching the stoma and the tube…

…using a commercial access port:

1. **Take off the old pouch.**
2. **Access the area of the stoma and peristomal skin.**
3. **Clean the area with warm water and dry. If the peristomal skin needs any treatment, such as stoma powder, then apply it at this time.**
4. **Measure the opening for the stoma and cut to fit. The wafer? Measure the stoma**
5.
6. **Mark where the catheter tube is needed to exit the pouch, cut a small opening, and insert a universal catheter access port. (Hollister 9779 universal catheter access port) should be able to just punch through**

7.[6.] **Thread the catheter through the port and attach the pouch.**

8.[7.] **Reenforce where the tube is coming out and apply waterproof tape to this area.**

As you can see above I had some trouble following what you were saying … **See https://www.hollister.com/en/products/ostomy-care-products/ostomy-accessories/urostomy-drain-tube-adapters/universal-catheter-access-port**

1. **Take off the old pouch and wash and dry the skin.**
2. **Insert the blue and white hole punch through the pouch. (Hollister #9979)**
3. **Place the graduated nipple over the blue and white hole punch from the outside and press it**

together until it snaps on.

4. Apply pressure to the ring to ensure a secure seal.
5. Cut the tip and insert the catheter into the graduated nipple from inside the pouch.
6. Make sure the seal is secure. Apply waterproof tape around the catheter to ensure no leakage.
7. Secure the pouch to the skin.

...in the absence of a commercial access port: If you do not have a port, you can still use a baby nipple to thread the catheter in and exit the stoma pouch. You did not answer this question

1. Get a new pouch for the patient.
2. Remove the old pouch and clean and dry the area.
3. Cut a small opening where you would like the catheter to exit.
4. Use a baby nipple and cut a small opening in the top of the nipple.
5. Insert the nipple through the opening in the stoma pouch.
6. You can place water-soluble lube inside the nipple to help the catheter thread through the opening.
7. Secure the pouch to the skin.
8. Use waterproof tape around the pouch and nipple to seal the openings.

.8/2 points one part unanswered & the other a little unclear

Scenario 10

86-year-old obese individual presents to the ostomy clinic with a retracted stoma. States has a soft-formed stool once a day. Pouch changed daily as stool goes under the skin barrier wafer, and at times, no stool goes into the pouch.

It is determined a convex pouching system should be used. A convex skin barrier wafer is not available.

Identify two strategies to create convexity in the absence of a convex skin barrier wafer.

Image courtesy of Wound, Ostomy, and Continence Nurses Society™ image library.

Alternative convexity option #1: Coloplast Sensura mio extended wear Maxi drainable convex deep #6216765 This is a one-piece cut-to-fit.

1. **Prepare the skin and stoma clean and dry area.**
2. **Apply the barrier ring Eakin #0423 to a flat barrier pouch**
3. **Create a curve that you can gently mold or stretch the ring to make a curved shape and fit the area and skin around the stoma.**
4. **You can cut pieces of rings to help build up if needed.**
5. **Apply the system, making sure the convex shape is pressing gently around the stoma to help push the stoma up and out.**

Alternative convexity option #2: Since the patient only has stool once a day, we could try a Coloplast Sensura Mio standard wear closed pouch convex deep. If the patient only has one a day, then it is reasonable to have the closed pouch and change one a day until the proper equipment can be ordered, and see if the deep convex pouching is working for this patient.

1. Another way to create convexity would be to apply an ostomy belt to the stoma bag. This targets pressure and tension on the stoma area, which has helped it protrude. You could do the above steps and also place on an ostomy belt to help create convexity for the patient

0/2 points

You missed the point on this question. THERE ARE NO CONVEX POUCHES AVAILABLE...what can you do to create convexity?

Scenario 11

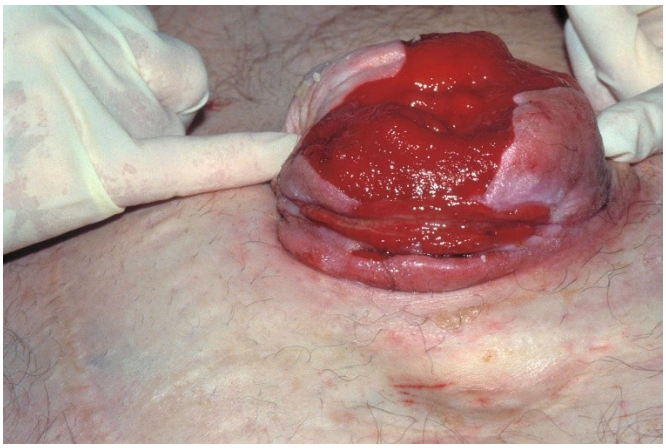

A 70-year-old patient presents to the ED with pouching difficulty. They report using a fistula pouch previously, however, this has become too costly of an option. Their stoma measures *4 1/3"* in diameter and they are at a loss for pouching options. The patient will need pouching long term. Identify one product that is manufactured as an ostomy product to accommodate a stoma of 4" or greater in size.

Image courtesy of Dr. James Wu

Pouching option: Hollister High Output drainable one piece pouch cutting surface max 110mm #80110

No this is only 4 1/3" so there is NO room between wafer & stoma. There are things out there....

Coloplast #19011 Sensura 1 piece post op pouch fit 10mmto 115mm

Coloplast #19021 Sensura One piece ostomy pouch drainable

0/2 points

References: *(3 points)***1 point** good references, formatting issues....don't forget in Word these are double spaced w hanging indent

Brunette, G. (2017). Novel Pouching Techniques for the Neonate With Fecal Ostomies. *Journal of Wound, Ostomy, and Continence Nursing*, *44*(6), 589–594. https://doi.org/10.1097/WON.0000000000000384

Rolfsen, T., Vestergaard, M., Hansen, M. F., Boisen, E. B., & Dambæk, M. R. (2024). Body Fit With a Pouching System With Concave Contour for People With an Outward Peristomal Body Profile: Effects on Leakage,

Wear Time, and Quality of Life: A Randomized Controlled Cross-Over Trial. *Journal of Wound, Ostomy, and Continence Nursing*, *51*(4), 303–311. https://doi.org/10.1097/WON.0000000000001088

Wound, Ostomy and Continence Nurses Society, Bookout, K., D'Italia, J., Dudley, J., Hafeman, C., Harrison, B., McLane, K., Rogers, V., & Shelley, A. (n.d.). PEDIATRIC OSTOMY CARE BEST PRACTICE FOR CLINICIANS. https://cdn.ymaws.com/member.wocn.org/resource/resmgr/document_library/PEDIATRIC_OSTOMY_CARE-_BEST_.pdf

Zamarripa, C., Craig, A., Mathews, C., Small, L., & Folk, A. (2025). A retrospective Chart Review of Ostomy Pouching Systems in New Ileostomy Patients: A sub-analysis. *Nursing Reports*, *15*(6), Article 206. https://doi.org/10.3390/nursrep15060206