R. B. Turnbull Jr. MD WOC Nursing Education Program

Mini Case Scenarios: Wounds

Student Name __Lisa Katrowsk_____ Date: _10/28/2025_____

Reviewed by: _____ Date: _____

Score: /83

For the following wound case scenarios:

1. Identify the type of wound pictured.
2. Apply wound characteristics provided to identify recommendations/nursing orders for this patient & the wound.
3. Include the following in the recommendations/orders
    a. Dressing
        i. Type of dressing
        ii. Brand name(s)
        iii. Secondary dressing if needed
        iv. Dressing change schedule
    b. Other nursing orders pertinent to successful wound healing or prevention *(be specific as to schedule, turning surfaces if applicable, product, etc.)*
    c. Rationale for choices
4. Provide an alternative to your initial dressing choice. This should be a product substitution, not simply a brand name substitution.
5. Answer any additional questions.
6. *No advanced dressings such as NPWT or CAMPs (formerly called cellular tissue products) unless specifically requested. What would you use if these two dressing types are not available to you?
7. Throughout this assignment you will be applying evidence to treat various wound scenarios. As appropriate, if you use a reference, make sure to cite it correctly.
8. To support your actions, include at least three relevant references in addition to the course textbooks. (Use 7th edition APA formatting)

A case study has been completed for you. Below is an example.

Example Scenario

85-year-old in an extended care facility has a skin tear on her right forearm after a recent fall. The skin tear has been classified as Type ??? as described by the International Skin Tear Advisory Panel (ISTAP).

Image courtesy of Wound, Ostomy and Continence Nurses Society image library.

Wound type: Skin tear, Type 2
(1 point)

Wound Nurse recommendations/orders:

1. Use no rinse, pH balanced bath wipes at bathtime vs. soap, minimize rubbing at bath time, & gently dry fragile skin
2. Apply mesh contact layer (Hollister Adaptic)
3. Moisturize both arms daily with Medline Remedy moisturizing lotion
4. Wrap with roll gauze (Kerlix).
5. Change dressing on every shower day or if wet or soiled
6. Use long sleeve garments or sleeve covers for patient during waking hours

(3 points)

Rationale for choices

1. Bath wipes are pH balanced & soap is usually alkaline & difficult to rinse if person not showering
2. Rubbing creates friction which may cause skin tears
3. Contact layer prevents dressings from sticking to wound
4. Skin moisturizing is a preventive measure for skin tears
5. Roll gauze keeps contact layer in place & patient from touching wound & is non-adhesive
6. Long sleeves protects patient's skin and discourages picking at dressing

(2 points)

Identify 1 alternative primary/secondary dressing from a different dressing category. Write as a nursing order. Non-adhesive foam dressing, 5 layers, (Allevyn) secured with elastic mesh dressing (Medline elastic retention dressing). Change q3d and PRN
(2 point)

Scenario 1

You are asked to assess a new resident admitted with a sacral wound. Patient is 82-year-old and admitted with dementia. Wound on sacrum with 100% yellow slough and brown necrotic tissue at wound edges. No exudate noted. Wound measures approximately 4 cm x 3 cm x 2 cm. Periwound with blanchable erythema.

Image courtesy of Wound, Ostomy and Continence Nurses Society image library.

Wound type: Unstageable Pressure Injury, Stage 3 or Stage 4 It is a full thickness wound. Unable to determine the extent of the tissue damage because it is covered by 100% yellow slough and brown necrotic tissue at the edges.

(1 point)

Wound Nurse recommendations/orders:

1. Cleanse the area with normal saline.
2. Measure the wound and document any new findings, and take a new photo of the wound.
3. Apply Santyl nickel thick or 2mm to the necrotic tissue area and avoid getting excess ointment on healthy skin.
4. Place a 4x4 gauze over the area.
5. Cover with a Mepilex Sacrum border dressing, change every day.
6. Turn and reposition the patient every 2 hours from right to left side, trying to avoid pressure to the sacrum.
7. Order an air loss mattress for the patient because of a pressure injury to the sacrum and help prevent any new injuries.

(3 points)

Rationale for choices: This is a simple solution to help debride the area. The dressing is not too invasive to the patient and is easy to apply. Since this patient has dementia, he is already receiving care and or has help, it will be easy to continue with this dressing to help improve this wound.

1. Use of normal saline might be easier with a dementia patient. I am not sure how easy it is for the person to shower or clean the area.
2. Santyl is an enzymatic debriding agent that will help to break down and remove the dead skin in the wound base.
3. The area needs to be covered and stay moist.
4. This needs to be done at least once a day to be effective
5. Turning and repositioning in bed is important to take the pressure off the sacrum area.
6. Need to be aware and reduce pressure to the sacrum while making sure no new injuries occur. An air loss mattress can help prevent pressure injuries.

(2 points)
Identify 1 alternative primary/secondary dressing from a different dressing category. Write as a nursing order. 1. Clean the area with normal saline 2. Dry the skin 3. Place an alginate dressing Aquacel AG into the wound, cut to fit the area, but do not overfill. 4. Apply Mepilex sacrum border and change every 3 days. **(2 points)**

/8 points

Scenario 2

 The wound care nurse is consulted to see a 54-year-old, post op day 4 after an abdominal surgery. Left heel has non-blanchable purple discoloration. Image courtesy of Judy Mosier, MSN, RN, CWOCN.
Wound type: Deep Tissue Pressure Injury (DTPI). This cannot be staged at this time. We would have to watch and see what this evolves into to stage the injury. This area could stay closed and resolve or evolve, then open, and we could then stage the injury. **(1 point)**
Wound Nurse recommendations/orders: **1. Protect the area and elevate the heels off the bed with pillows, heel offloading devices, or TruVue Heel protectors.** **2. Order a low-air-loss bed.** **3. Assess the area daily and each shift, and monitor the area for progression or if any area opens.** **4. If the area opens, take a new photo and contact the WOC team for new orders** **(3 points)**
Rationale for choices: This is a Deep tissue pressure injury that is not open at this time. Patient just had a major surgery and might not be able to ambulate or move easily on their own at this time. By ordering a low air loss mattress, this will help to lower the risk of another pressure injury. The area that does have a pressure

injury, as well as the other heel, needed to be protected and have offloading to this area as well as other pressure point areas, and be monitored for changes.

(2 points)

Identify 1 alternative primary/secondary dressing from a different dressing category. Write as a nursing order.

1. **Cleanse the area with normal saline or pH-balanced cleanser and dry the area.**
2. **Apply Mepilex heel border foam to both heels. And change every 3 days.**
3. **Pull back the dressing and assess the area every 8 hours.**
4. **Elevate the heel off the bed with pillows, heel offloading devices, or TruVue Heel protectors.**

(2 points)

/8 points

Scenario 3

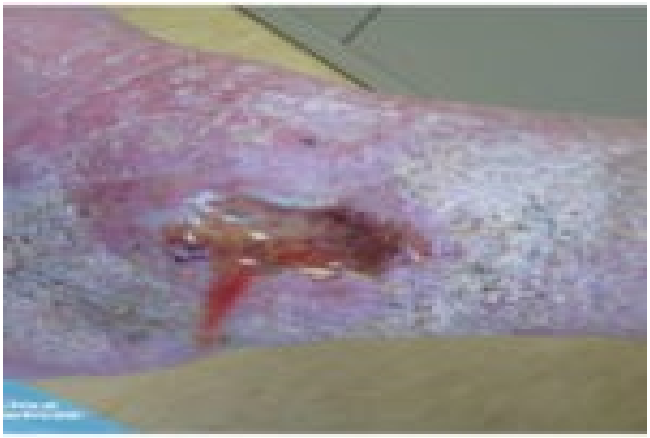

A 70-year-old arrives at the outpatient wound clinic with a nonhealing wound located on gaiter area of right lower extremity. The wound measures approximately 5 cm x 2.5 cm x 0.5 cm. The wound is a shallow, irregular shaped ulcer with moderate amount of exudate. Periwound is macerated. Hemosiderin staining is noted to BLE. Patient has ABI of 0.85 to RLE and 0.90 to LLE

Image courtesy of Wound, Ostomy and Continence Nurses Society image library.

Wound type: Peripheral Artery Disease, Stage 3 Full thickness

(1 point)

Wound Nurse recommendations/orders:

1. Clean wound with normal saline.
2. Measure the wound and document any new findings, and take a new photo of the wound.
3. Apply 3m barrier around the periwound to help protect skin.
4. Apply Hydrocolloid to the wound base
5. Change dressing every 3 days or PRN if saturated or soiled.

(3 points)

Rationale for choices:

1. Need to clean the area.
2. Skin around the wound has maceration 3m barrier will help to protect the skin and give a layer of protection from the moisture.

3. A hydrocolloid dressing will help with the drainage and protect the wound base.
4. Dressing can stay on for a longer period, so it does not need to be changed every day unless saturated or soiled.

(2 points)

Identify 1 alternative primary/secondary dressing from a different dressing category. Write as a nursing order.

1. Clean wound base with normal saline.
2. Apply 3m barrier to the periwound to help protect skin.
3. Apply Allyven foam dressing to the wound every 3 days or PRN if saturated or soiled.

(2 points)

/8 pointsClean

Scenario 4

An 85-year-old is admitted to the hospital with a stage ??? pressure injury on sacrum and is bedridden. Full thickness wound measures approximately 8 cm x 10 cm x 0.4 cm. Wound bed pink with small amount of yellow slough. No structures, no bone noted. Wound has moderate serosanguineous exudate. NPWT is *not* available at this time.

Image courtesy of Judy Mosier, MSN, RN, CWOCN.

Wound type: Pressure injury Stage 3, full thickness

(1 point)

Wound Nurse recommendations/orders:

1. Cleanse the wound with normal saline.
2. Measure the wound and document any findings, and take a new photo of the wound.
3. Apply a 3m barrier film to the surrounding periwound skin to help protect intact skin from the solution.
4. Pack the wound with moist gauze soaked in Dakin solution and lightly pack the wound base.
5. Apply ABD pad and secure with paper tape.
6. Change wound daily and PRN if soiled.
7. Turn and reposition the patient every 2 hours from right to left side, trying to avoid pressure to the sacrum.
8. Order an air loss mattress for the patient because of a pressure injury to the sacrum and help prevent

any new injuries.

(3 points)

Rationale for choices:

1. The wound base needs to be cleaned.
2. The area needs to be assessed, and the wound measurement to see if the area is improving. The nurse needs to see if the area is infected, has an odor, tunnels noted, or any other issues. A photo helps to document the changes in the wound base and allows to have documentation and a record of how the wound is responding to the treatment, is helps and improves the wound.
3. 3m barrier film will help to protect intact skin from the solution and reduce the risk of maceration to intact skin.
4. To help with yellow slough in the base of the wound, Dakin's will help to break down and clean the area and reduce the risk of infection. It can also help to control odor in a wound.
5. The area needs to be lightly packed and covered with ABD dressing and secured.
6. It is important to encourage the patient to be turned and repositioned in bed and to avoid more pressure to this area. A turning schedule as well as an air loss mattress, will help to decrease the risk of damaging the area further and causing a new pressure injury.

(2 points)

What support surface would you recommend (1pt) and why? (1pt)

As stated above, I would recommend an air loss mattress used with this patient. The mattress used at my facility fluctuates and allows the mattress to shift, and pressure is redistributed while the patient is in the bed. The other advantage of the air loss mattress can prevent excessive heat and moisture build-up under the patient, which helps to decrease the possibility of further injuries.

(2 points)

/8 points

Scenario 5

56-year-old alert and oriented male hospitalized for cardiac surgery. During the hospital stay, on day 2 post-op they developed painful open area to sacrum. The patient is incontinent of urine and stool and has not been repositioning in bed due to reported pain.

Image courtesy of Cleveland Clinic.

Wound type: Stage 2

(1 point)

Wound Nurse recommendations/orders:

Reduce the amount of moisture the patient is being exposed to. Placement of a condom catheter and a fecal management system, if appropriate for this patient, to decrease the amount of moisture on the skin. Find a pain medication that works to help facilitate the patient's ability to be turned and repositioned in the bed. Order a low-air-loss mattress to help decrease the pressure being applied to the sacrum and other areas.

1. Clean sacrum with a pH-balanced cleanser.
2. Apply Zinc oxide to the sacrum
3. Assess skin, turn and reposition, and check for incontinence every 2 hours
4. Keep skin dry
5. Continue education to the patient about the effects of using pain medication, the importance of turning and repositioning to decrease the skin breakdown, and good nutritional intake to help increase healing potential.

(3 points)

Rationale for choices: The patient is incontinent currently and is having moisture issues. We need to try and find a solution to control and decrease moisture. If possible, we can try to use a condom catheter for urine to reduce moisture. If the stool is liquid, we can try a rectal pouch or monitor the patient more closely. The patient is having a complaint of pain and refusing to turn. We need to find out why they are having pain and better medication to help with the pain, to allow us to reposition the patient. He would benefit from a low-air-loss mattress to help with offloading the sacrum and other pressure points.

(2 points)

Identify 1 alternative primary/secondary dressing from a different dressing category. Write as a nursing order.

1. Clean the area with a ph balance cleanser.
2. Apply Mepilex dressing to the wound.
3. Change dressing every 3 days or PRN if soiled.
4. Assess the area every 8 hours and keep the skin dry.

(2 points)

/8 points

Scenario 6

The wound care nurse is consulted to the intensive care unit to see a non-verbal 57-year old male respiratory failure patient for a new wound found under the patient's pulse oximeter during routine care. The patient has been admitted to the hospital for 14 days and has no previously documented wounds.

Image courtesy of CCF.

Wound type: Pressure injury, Stage 4

(1 point)

Wound Nurse recommendations/orders:

1. Clean the ear with normal saline. Change dressing every 3 days, but assess under the foam every 8 hours.
2. Apply a foam dressing, Mepitel Lite, to the ear.
3. Monitor patient and check the position of the head to ensure no additional pressure to the area, and the patient is being turned and repositioned every 2 hours.
4. Select a new area for the patient's pulse oximeter. If in an emergency, it is placed on the ear again, assess the area every 2 hours, and reposition the probe.

(3 points)

Rationale for choices:

1. It needs to be cleaned, and the area protected with foam dressing.
2. We need to discourage the use of the pulse oximeter being placed on the patients' ears and the importance of shifting and repositioning the probe more frequently to decrease the risk of injury.

(2 points)

Identify 1 alternative primary/secondary dressing from a different dressing category. Write as a nursing order.

1. Clean the ear with normal saline.
2. Apply Xeroform cut to fit the wound base.
3. Apply 4x4 gauze and apply paper tape to the area.

(2 points)

/8 points

Scenario 7

An 85-year-old presents to acute care with dry black eschar on left posterior heel. Cared for at home by elderly spouse, he has been bedridden for the past 6 months. The wound measures approximately 6 cm x

10cm x 0 cm. Wound edges are dry and periwound has no erythema.

Image courtesy of Wound, Ostomy and Continence Nurses Society image library.

Wound type: Unstageable pressure injury, Unable to tell what stage the injury is because of stable eschar, which could be stage 3 or a stage 4

(1 point)

Wound Nurse recommendations/orders:

1. Leave stable eschar intact.
2. Protect the wound, apply ABD pads, and kerlix.
3. Keep the area dry.
4. Elevate the heel off the bed with pillows, heel offloading devices, or TruVue Heel protectors.
5. Consult the provider to have them assess the area.

(3 points)

Rationale for choices:

The patient is an 85-year-old bedridden patient being taken care of by an elderly spouse. I do not have all of the information needed to see if we should do debridement in this area. I do not know other comorbidities, diagnostic testing for arterial flow, or the nutritional status of this patient to know if they would have good healing potential. At this time, is area is intact without erythema and/or fluctuance. I feel this area should stay intact. The patient caregiver is also an elderly person so to complicate the care of the spouse and add the stress of a new wound, dressing, and give way to may have an infection from an open wound. I would advise not to open at this time unless the provider feels it is necessary or the area will heal.

(2 points)

Identify 1 alternative primary/secondary dressing from a different dressing category. Write as a nursing order.

1. Obtain the order and have enzymatic debridement cross-hatching.
2. Cleanse the wound with normal saline and dry it.
3. Apply an enzymatic debridement topical, a collagenase ointment Santyl nickel thick or 2mm to the entire wound surface or eschar area and avoid getting excess ointment on healthy skin.
4. Apply 4x4 gauze, ABD pad, and wrap with kerlix and paper tape to secure.
5. Daily dressing changes.

(2 points)

/8 points

Scenario 8

Wound care nurse is consulted to see a 74-year-old for an abdominal wound several days post-surgery for ischemic bowel. Wound measures approximately 10 cm x 4 cm x 3 cm with visible sutures. Wound bed dry,

pink with small areas of yellow tissue (less than 10% of wound base). Periwound skin intact. <u>NPWT ordered by physician who has requested WOC nurse input into dressing instructions and pressure settings</u>

Image courtesy of Wound, Ostomy and Continence Nurses Society image library.

Wound type: Stage 3/ surgical incision

(1 point)

Wound Nurse recommendations/orders:

1. Clean the area with Vashe and dry well.
2. Apply 3m barrier film to the surrounding periwound skin.
3. Apply a protective contact layer over sutures with an oil emulsion
4. Apply transparent film like a window pane about a 3mm to 5mm border around the wound.
5. Cut black foam to fit into the wound to fit the wound base. You can place more than one piece into the wound but keep count of the pieces being placed in the wound.
6. Apply a drape with the transparent film over the black foam and make sure that it is completely covered and you have a good seal.
7. Once covered, you need to cut a small opening about a quarter in size to attach the track to the black foam. Think about placement for the patient's movement, and think about the pressure the tube could cause, and avoid this.
8. Attach the drainage tube to the NPWT machine, making sure all tubing is connected, clamps are open, and no kinks in the tubes.
9. Make sure the machine is on and the setting is set to -125mmhg, and no leaks are found.
10. Be sure to fill out the wound packing log and make sure correct protocols are followed.
11. NPWT dressing should be changed on Monday, Wednesday, and Friday.

(3 points)

Rationale for choices:

The NPWT was ordered by the doctor. This is a good way to help promote wound closure and encourage wound healing. The area needs to be cleaned. Placing a contact layer over the sutures helps protect them as well when removing the foam for a change and limiting the risk of sutures being pulled on. Surrounding periwound skin needs protection and to be covered with a border to protect the healthy skin. We need to limit the amount of black foam pieces and know the amount placed to be sure when it is changed again, we remove all objects in the wound base. The drape has to cover all of the black foam and have a good seal for the machine to work. The machine will alarm is there is not a good seal and you have a small leak. When applying a track on a patient, we must think of how they are moving and how we can place this to limit a negative effect on a patient's mobility. It is also important to remember that this is now a tube that a patient could possibly get a pressure injury from, and we need to be vigilant on the placement and repositioning so no harm comes to the patient. The -125mmhg is the standard setting mostly used. We should be monitoring the area and make sure that this pressure is not causing harm or pain to the patient.

(2 points)

Identify 1 alternative primary/secondary dressing from a different dressing category. Write as a nursing order.

1. Clean wound base with Vashe cleanser.
2. Apply a wet-to-dry dressing to the wound.
3. Gauze should be soaked in Vashe cleanser and lightly packed into the wound base.
4. Apply ABD pads and apply paper tape dressing should be changed every day or PRN when soiled.

(2 points)

/8 points

Scenario 9

Wound care nurse consulted to see a 45-year-old male with damaged skin. Patient has been at your facility for 2 weeks with diagnosis of C-Diff. You note some necrotic tissue in the right coccygeal area as well as painful weepy lesions across both buttocks and scrotum.

Image courtesy of Wound, Ostomy and Continence Nurses Society image library.

Wound type: Unstageable wound necrotic tissue

(1 point)

Wound Nurse recommendations/orders:
Monitor patient's urine and bowel movements and decrease moisture in this area. If the patient is able to use alternative ways to keep patient dry. Are they a candidate for a condom catheter or a fecal pouching system? Would this patient benefit from a toileting schedule to try and decrease the moisture on the sacrum?

1. Clean area with pH-balanced cleanser.
2. Apply Santyl nickel thick or 2mm to the necrotic tissue area and avoid getting excess ointment on healthy skin.
3. Place a 4x4 gauze over the area.
4. Cover with a Mepilex Sacrum border dressing, change every day.
5. Apply zinc oxide to other areas of the sacrum.
6. Turn and reposition the patient every 2 hours from right to left side, trying to avoid pressure to the sacrum and check moisture in that area.
7. Order an air loss mattress for the patient because of a pressure injury to the sacrum and help prevent any new injuries.

(3 points)

Rationale for choices:
We need to treat the wounds to the sacrum, but we have to look at this patient and how we can limit the amount of moisture they have against the skin. Need to investigate why we have so much skin damage and how we can prevent more moisture and protect the area. Does this patient need more assistance to make it to the bathroom or need a toilet schedule to help keep the patient on track and dry.

(2 points)

Identify 1 alternative primary/secondary dressing from a different dressing category. Write as a nursing

order.

1. Clean area with a pH-balanced skin cleanser.
2. Apply Medi honey to the necrotic area.
3. Apply gauze and Mepilex border sacrum.
4. Apply zinc oxide to the surrounding area.

(2 points)

/8 points

Scenario 10

A 75-year-old is admitted to acute care setting from home with pneumonia. They have a history of Raynaud Disease and Diabetes Mellitus. Has been seen at an outpatient wound clinic but is uncertain what the treatment plan is and you have no access to those medical records.
Open wound on dorsum of foot with exposed tendon. Measures approximately 8 cm x 12 cm x 0.2 cm. Wound bed 60% pink tissue and 40% yellow/black, brown tissue. Scant amount of tan drainage. Periwound intact with epibole.

Image courtesy of Wound, Ostomy and Continence Nurses Society image library.

Wound type: Stage 4

(1 point)

Wound Nurse recommendations/orders:

1. **Clean wound with normal saline being gentle to the exposed tendon in the wound.**
2. **Apply oil emulsion to the exposed tendon and be sure to cover completely.**
3. **Apply Santyl to the slough in the wound avoiding healthy tissue and apply gauze.**
4. **Place ABD pad and wrap foot with Kerlix and secure with an Ace bandage.**
5. **Change dressing daily.**
6. **Notify provider of any signs of infection.**

(3 points)

Rationale for choices:
The exposed tendon needs to be protected and kept moist. This is why we place a layer to cover the tendon. On the slough and necrotic areas we can apply Santyl to help with debridement this area. I chose to place and Abd pad over top to help not only pad and protect this area but because this area was noted to have drainage. All wounds need to be monitor for chance of infections and provider should be told straight away. Daily dressing will allow use to assess the area help with debridement and make sure the area is staying moist and has not become infected.

(2 points)
Identify 1 alternative primary/secondary dressing from a different dressing category. Write as a nursing order. **1. Clean wound with normal saline being gentle to the exposed tendon in the wound.** **2. Apply oil emulsion to the exposed tendon and be sure to cover completely.** **3. Cut to fit Aquacel Ag to cover area to help with debridement and moisture to the wound base.** **4. Place ABD pad and wrap foot with Kerlix and secure with an Ace bandage.** **5. Change dressing daily.** **6. Notify provider of any signs of infection.** **(2 points)**

/8 points

References (3 points):

Baranoski, S., Ayello, E. A., LaBlanc, K., Beeckman, D., & Sibbald, R. G. (2021). Skin challenging conditions. In S. Baranoski & E. A. Ayello, (2021). Wound care essentials: Practice principles. (5th ed. pp. 333-369) Wolters Kluwer.

Bryant, R. (2024). Skin damage types and treatment. In R. Bryant, & D. P. Nix (Eds.). (2024). Acute & chronic wounds: Interprofessional from novice to expert. (6th ed. 164-191) Elsevier.

Kottner, J., & Dissemond, J. (2025). Incontinence-Associated Dermatitis in Older Adults: A Critical Review of Risk Factors, Prevention and Management: Incontinence-Associated Dermatitis in Older Adults. Drugs & Aging, 42(8), 745–754. https://doi.org/10.1007/s40266-025-01227-z

National Pressure Injury Advisory Panel, European Pressure Ulcer Advisory Panel and Pan Pacific Pressure Injury Alliance. Preventing Heel Pressure Injuries. In: Prevention and Treatment of Pressure Ulcers/Injuries: Clinical Practice Guideline. The International Guideline: Fourth Edition. Emily Haesler (Ed.). 2025. [cited: October,27.2025]. Available from: https://internationalguideline.com.

Thayer, D. & Nix, D. (2022). Incontinence-associated dermatitis. In J.M. Ermer-Seltun, & S. Engberg (Eds.), (2022). Wound, Ostomy and Continence Nurses Society core curriculum: Continence management (2nd ed., pp. 364-381). Wolters Kluwer.