R. B. Turnbull Jr. MD WOC Nursing Education Program

Mini Case Studies: Ostomy

Cleveland Clinic

Student Name & Date:_
Reviewed by:_____
Score: /40

This assignment focuses on applying the assessment of an individual with an ostomy to pouching principles. First, basic principles are identified. Then, principles are applied to clinical situations. *Answer the four questions below* and then read the instructions on the next page

1. Identify the nursing orders for changing a pouching system on a person with no peristomal skin breakdown. **(2 points)**

2. Identify nursing orders for changing a pouching system on a person with peristomal skin breakdown**.** **(2 points)**

3. Identify nursing orders for changing a pouching system on a person with peristomal skin breakdown and the presence of satellite lesions**.** **(2 points)**

4. Differentiate the standard wear barrier from an extended wear barrier. Identify the type of ostomy or situation where each type of barrier would be indicated, and provide a *specific* example for each. Identify manufacturer name, product name, and manufacturer product number. **(4 points)**

For each of the below ostomy patient case scenarios:

- Use the information provided to identify an ostomy pouching plan.
  - ***Be specific:*** It is important to note a pouching system is a skin barrier wafer and a pouch. A complete answer should include both unless otherwise indicated. **Include the manufacturer, manufacturer product number, and full product name**. Make sure to include accessory products as needed.
  - When providing the rationale: Describe abdominal characteristics, stoma characteristics, and one other reason why you would choose the specific system.
- The first half of the first case study has been completed for you below as an example.
- Include at least 3 references *(other than your text book)* used to back your actions at the end of the assignment that assisted you in this assignment. Make sure to use 7th edition APA formatting.
-

Example + Scenario 1

55-year-old with a history of colon cancer. Colostomy was created 2 months ago and presents today in the ostomy clinic for assessment and management. Pt is very active and would like to consider a more flexible pouching system. Pt is changing his pouching system every other day because he is fearful of leakage.

Assessment: Stoma is pink, budded, and protrudes above skin level. No erythema on parastomal skin. No reports of leakage.

Identify a one and two-piece pouching system option along with rationale for choice.

Image courtesy of Wound, Ostomy, and Continence Nurses Society™ image library.

One Piece System: *Hollister Premier one-piece drainable pouch flat Flexwear barrier (**#8031)** with clamp closure, change every 5-7 days and PRN.*

Rationale: *This system is flexible and matches the contours of this patient's abdomen. It is appropriate for budded stomas with an even peristomal plane and is manufactured for wear for multiple days.*

Two Piece option:

Skin Barrier wafer:

Pouch:

Rationale:

/2 points

Scenario 2

42-year-old with Laparoscopic colostomy stoma placement on <u>soft</u>, obese abdomen, 1 week post op.

Assessment: Stoma pink, budded, and protruding. Edema and necrosis circumferential at stomal edge. Serosanguineous drainage in pouch. Skin barrier wafer removal notes being cut too small, restricting and causing trauma to the stoma.

Identify a one and two-piece pouching system option along with rationale for choice.

Image courtesy of Wound, Ostomy, and Continence Nurses Society™ image library.

One Piece option:

Rationale:

Two Piece option:

Skin Barrier Wafer:

Pouch:

Rationale:

/4 points

Scenario 3

56-year-old obese individual with ruptured diverticulitis. A red rubber catheter in place as a bridge for the loop ostomy. Stoma is slightly budded and red. Peristomal skin with erythema and partial thickness wound 4-7 o'clock Etiology may be due to trauma from red rubber catheter movement.

Image courtesy of Wound, Ostomy, and Continence Nurses Society™ image library.

Pouching recommendations:

Rationale:

/2 points

Scenario 4

66-year-old obese individual with a loop ileostomy stoma in an abdominal fold. Appliance leakage causing contact dermatitis. Wear time has been less than 8 hours. Irritation is painful.

Image courtesy of Wound, Ostomy, and Continence Nurses Society™ image library.

Pouching Recommendations:

Rationale:

/2 points

Scenario 5

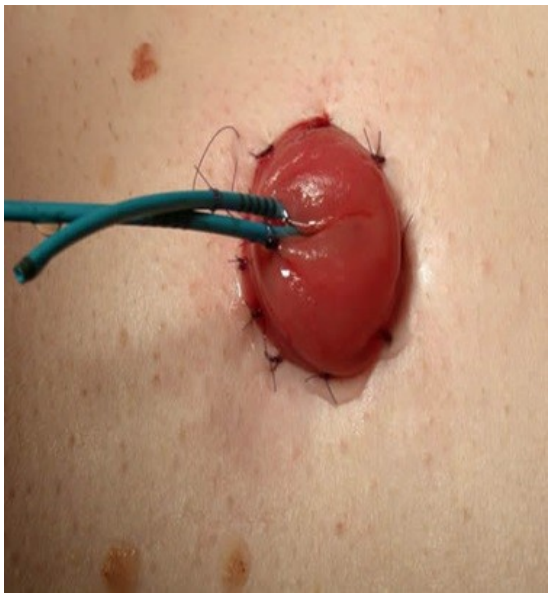

A 76 year old patient is seen on a urology floor for a initial post operative visit. Urostomy noted with 2 stents in place, draining clear/pink tinged urine bilaterally. Surgeon requesting to be able to access stents. Pouching system removed was a one-piece post operative pouch. The patient is not yet ready for education and is currently non-ambulatory.

Image courtesy of SER, 2006

Pouching option:

Additional accessories to consider:

/2 point

Scenario 6

46-year-old presents to the ostomy clinic with peristomal redness to periphery. Patient is currently in a one piece system with a 12” pouch. Irritation limited to appliance tape collar region. Satellite lesions present. Stoma is budded and round. States has had their ileostomy for 6 months and has not had any problem until recently after Home Health changed the products. Patient also expresses the pouch is too long with the end of the pouch falling into the groin area Abdominal space is small with short distance from stoma to groin.

Image courtesy of Wound, Ostomy, and Continence Nurses Society™ image library.

Pouching Recommendations:

Rationale:

Provide an alternative pouching recommendation to address the patient’s concern regarding pouch length.

/3 points

Scenario 7

An 80 year old legally blind patient presents to ostomy clinic due to peristomal hernia causing peristomal skin breakdown. Abdomen is firm. Appliance wear time has decreased since parastomal hernia development. Stoma is flush with skin. Os at 4 o'clock area. Complains of odor. "The odor is really bad when I empty the pouch".

Image courtesy of Wound, Ostomy, and Continence Nurses Society™ image library.

Pouching Recommendations:

Rationale:

Odor Management Strategies:

/3 points

Scenario 8

A pediatric Individual presents to the emergency room with stoma prolapse. Caregiver expresses inability to apply pouching system related to stomal protrusion. Stoma is red and healthy. No peristomal irritation.

Identify one pouching system with rationale for choice along with one consideration with appliance application specific to a prolapsed stoma.

Image courtesy of Wound, Ostomy, and Continence Nurses Society™ image library.

Pouching Recommendations: :

Rationale:

Further Considerations:

/3 points

Scenario 9

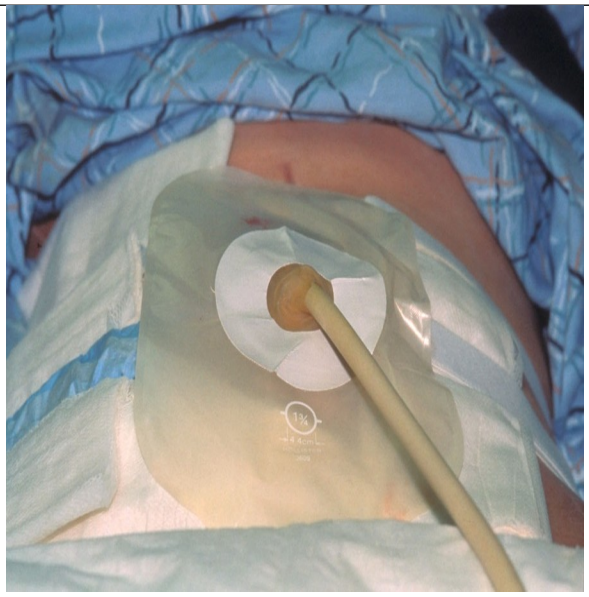

Image courtesy of Judy Mosier, MSN, RN, CWOCN

You are consulted to see a patient with a new colostomy. Upon entering the room, you note there is an indwelling catheter in the stoma. Nursing reports pouch leakage as the hole in the pouch for the tube is cut to fit the stoma resulting in a "big hole" in the front of the pouch. The surgeon's request is to continue to pouch the stoma while pulling the tube through the pouch.

Describe how you will secure the tube while separately pouching the stoma and the tube…

…using a commercial access port:

…in the absence of a commercial access port:

/2 points

Scenario 10

86-year-old obese individual presents to the ostomy clinic with a retracted stoma. States has a soft-formed stool once a day. Pouch changed daily as stool goes under the skin barrier wafer, and at times, no stool goes into the pouch.

It is determined a convex pouching system should be used. A convex skin barrier wafer is not available.

Identify two strategies to create convexity in the absence of a convex skin barrier wafer.

Image courtesy of Wound, Ostomy, and Continence Nurses Society™ image library.

Alternative convexity option #1:

Alternative convexity option #2:

/2 points

Scenario 11

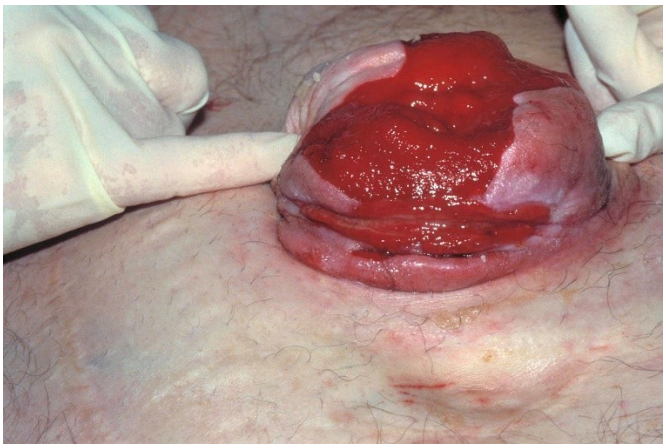

A 70-year-old patient presents to the ED with pouching difficulty. They report using a fistula pouch previously, however, this has become too costly of an option. Their stoma measures *4 1/3"* in diameter and they are at a loss for pouching options. The patient will need pouching long term. Identify one product that is manufactured as an ostomy product to accommodate a stoma of 4" or greater in size.

Image courtesy of Dr. James Wu

Pouching option:

/2 points

Include at least 3 references *(other than your textbook)* used to back your actions above. Make sure to use 7th edition APA formatting. (3 points)