R.B. Turnbull, Jr. MD School of WOC Nursing Education

Ostomy Care Mini Case Studies

Cleveland Clinic

Student Name & Date:_____Doris Elliott_____

Reviewed by_____

Score: /46

This assignment focuses on applying the assessment of an individual with an ostomy to pouching principles. First, basic principles are identified. Then, principles are applied to clinical situations.

Answer the following questions:

1. Identify the nursing orders for changing a pouching system on a person with no peristomal skin breakdown. (2 points)
   Gently remove the appliance using an adhesive remover wipe and one finger to push the skin away from the wafer. Using a soft cloth and water cleanse the peri-stomal skin by gently wiping the area to remove any residue. The skin should look like the rest of the patient's skin with no redness or breakdown. Measure the stoma using a stoma measuring sheet. Using a skin prep wipe gently wipe the peri-stomal skin and allow the product to dry, creating a tacky surface. Apply a barrier ring the skin immediately around the stoma, ensuring not to squeeze the stoma. Cut the wafer to match the sizing determined while measuring. Remove the backing of the one-piece appliance wafer and ensure the peristomal skin plane is flat while applying the appliance, smooth out the edges. Encourage the patient to lay their hand on the appliance for five minutes after application, no excessive pressure needed.

2. Identify nursing orders for changing a pouching system on a person with peristomal skin breakdown. (2 points)
   Gently remove the appliance using an adhesive remover wipe and one finger to push the skin away from the wafer. Using a soft cloth and water cleanse the peri-stomal skin by gently wiping the area to remove any residue. The skin should look like the rest of the patient's skin with no redness or breakdown. If breakdown is noted the crusting technique will be utilized. Measure the stoma using a stoma measuring sheet. Sprinkle the affected peristomal skin with stoma powder, then gently wipe away the excess. Using the skin prep dab the affected skin to lock the powder into place, do not wipe. Repeat the application of stoma powder and skin prep once more to create a new skin barrier. Apply a barrier ring the skin immediately around the stoma, ensuring not to squeeze the stoma. Cut the wafer to match the sizing determined while measuring. Remove the backing of the one-piece appliance wafer and ensure the peristomal skin plane is flat while applying the appliance, smooth out the edges. Encourage the patient to lay their hand on the appliance for five minutes after application, no excessive pressure needed.

3. Identify nursing orders for changing a pouching system on a person with peristomal skin breakdown and the presence of satellite lesions. (2 points)
   Gently remove the appliance using an adhesive remover wipe and one finger to push the skin away from the wafer. Using a soft cloth and water cleanse the peri-stomal skin by gently wiping the area to remove any residue. The skin should look like the rest of the patient's skin with no redness or breakdown. If breakdown is noted the crusting technique will be utilized. Measure the stoma using a stoma measuring sheet. Sprinkle the affected peristomal skin with miconazole antifungal powder, then gently wipe away the excess. Using the skin prep dab the affected skin to lock the powder into place, do not wipe. Repeat the application of antifungal powder and skin prep once more to create a new skin barrier. Apply a barrier ring the skin immediately around the stoma, ensuring not to squeeze the stoma. Cut the wafer to match the sizing determined while measuring. Remove the backing of the one-piece appliance wafer and ensure the peristomal skin plane is flat while applying the appliance, smooth out the edges. Encourage the patient to lay their hand on the appliance for five minutes after application, no excessive pressure needed.

For each of the below ostomy patient case scenarios:

- Use the information provided to identify an ostomy pouching plan.
  - Be specific: It is important to note a pouching system is a skin barrier wafer <u>and</u> a pouch. A complete answer should include both unless otherwise indicated. **Include the manufacturer and full product name**. Product numbers should <u>not</u> be used. <u>Make sure to include accessory products as needed.</u>
  - When providing the rationale: Describe abdominal characteristics, stoma characteristics, and one other reason why you would choose the specific system.
- The first half of the first case study has been completed for you below as an example:

Example + Scenario 1

55-year-old with a history of colon cancer. Colostomy was created 2 months ago and presents today in the ostomy clinic for assessment and management. Pt is very active and would like to consider a more flexible pouching system. Pt is changing his pouching system every other day because he is fearful of leakage.

Assessment: Stoma is pink, budded, and protrudes above skin level. No erythema on parastomal skin. No reports of leakage.

Identify a one and two-piece pouching system option along with rationale for choice.

Image courtesy of Wound, Ostomy, and Continence Nurses Society™ image library.

One Piece System: *Hollister Premier one-piece drainable pouch flat Flexwear barrier with clamp closure, change every 5-7 days and PRN.*

Rationale: *This system is flexible and matches the contours of this patient's abdomen. It is appropriate for budded stomas with an even peristomal plane and is manufactured for wear for multiple days.*

Two Piece option: Hollister New Image Cut-to-fit CeraPlus Skin Barrier with Remois technology is a two piece option that offers an extended wear wafer with ceramide infused into it that conforms to the irregularities of the skin. This will be paired with any New Image drainable pouch with the same size flange.

Rationale: The extended wear barrier offers a stronger adhesive that allows for greater comfort in that the appliance will stay in place. The ceramide infused within the appliance will be more resistant to sweat in those that are very active.

/2 points

Scenario 2

42-year-old with stoma placement on <u>soft</u>, obese abdomen.

Assessment: Stoma pink, budded, and protruding. Edema and necrosis circumferential at stomal edge. Serosanguineous drainage in pouch. Skin barrier wafer removal notes being cut too small, restricting and causing trauma to the stoma.

Identify a one and two-piece pouching system option along with rationale for choice.

Image courtesy of Wound, Ostomy, and Continence Nurses Society™ image library.

One Piece option: Coloplast Sensura Mio 1-piece drainable pouch system comes in a precut option with convexity.

Rationale: The convexity against a soft and obese abdomen will help to provide a better fit that ensures the stoma is protruding during position changes. Having a properly fitted pre-cut option ordered for the patient will ensure that the stoma is no longer constricted by improper sizing.

Two Piece option: Hollister New Image Convex FlexWear Skin barrier comes in a two piece option with convexity and pre-cut sizes available and is paired with any New Image drainable pouch with the same size flange.

Rationale: This two-piece option may be preferred as it allows the patient to discard the pouch when desired without having to change the wafer. The pre-cut size is preferred for this patient to ensure that the stoma is no longer constricted, and edema and necrosis will not continue to occur. The two-piece option will also allow for better visualization of the stoma while applying the wafer and will help with correct placement.

/4 points

Scenario 3

85-year-old presents with flush ileostomy and peristomal irritant dermatitis. Oval stoma with os at 6 o'clock location. Protuberant hernia above further pushes the stoma into a lateral fold.

Pt wears bifocal glasses when applying the pouching system. Due to extreme hip contours, it is difficult to have a hernia belt stay in place.

Image courtesy of Wound, Ostomy, and Continence Nurses Society™ image library.

Pouching recommendations: After cleansing a crusting technique is recommended using skin prep and stoma powder. The Hollister adapt oval convex barrier ring should be stretched to the proper size and applied around the stoma. Additional convexity can be applied using the Coloplast Sensura Mio Convex Flip 2-piece click appliance which comes with a cut-to-fit option. The belt should continue to be utilized and sized to ensure that proper fitting is occurring.

Rationale: The crusting technique will help to heal and prevent the contact dermatitis that has occurred. Layering of the convexity using first a convex oval ring paired with a convex flower shaped wafer will help to push the stoma out significantly while contouring to the bulging shape of the hernia and folds. A two-piece appliance can be cut to size prior to starting the changing process so that it will occur more quickly, but the two piece will allow for the patient to better visualize the stoma and ensure proper placement than a one-piece option. This appliance does come with stoma belt loops so that the patient can continue to try to stoma belt for added security and increased protrusion.

/2 points

Scenario 4

56-year-old obese individual with ruptured diverticulitis. A red rubber catheter in place as a bridge for the loop ostomy. Stoma is slightly budded and red. Peristomal skin with erythema and partial thickness wound 4-7 o'clock Etiology may be due to trauma from red rubber catheter movement.

Image courtesy of Wound, Ostomy, and Continence Nurses Society™ image library.

Pouching recommendations: After cleansing, the peri-stomal skin may be protected using skin prep and duoderm that can be cut to fit over the wound and around the red rubber catheter. A coloplast Sensura Mio one-piece flat appliance can then be applied.

Rationale: Duoderm will help the wound to heal and protect from further trauma, the duoderm can also be cut to size to accommodate proper peri-stoma protection while also fitting around the red rubber catheter until it can be removed. This will further protect the skin as the wafer will need to be cut larger than the stoma to accommodate the red rubber catheter. The appliances come in a cut-to-fit and transparent option that will allow for easy visualization of the stoma during the post-operative period for closer monitoring.

/2 points

Scenario 5

42-year-old arrives in emergency room with complaints of difficulty pouching and peristomal skin irritation. Current pouching system sometimes has less than 4 hours of wear time. Skin is very painful. Assessment finding of ulcerated skin around stoma. Stoma is at skin level on a firm abdomen. Patient acknowledges frequent sweating resulting in the need to change appliance. "It just doesn't seem to stick".

Image courtesy of Wound, Ostomy, and Continence Nurses Society™ image library.

Pouching Recommendations: Cleanse skin gently with a soft cloth and warm water. Apply the crusting technique using stoma powder and skin prep. The Hollister CeraPlus soft convex 1-piece drainable pouch should then be applied. The edges can be reinforced using Hollister Ceraplus barrier extenders.

Rationale: The denuded skin will complicate having a seal further so the crusting technique will help to absorb moisture from both the skin and the sweat. The ceramide appliances will help to decrease trans epidermal water loss, and the soft convexity is appropriate convexity to help to protrude the stoma past the skin on a firm abdomen. The seal is further enhanced by adding the barrier extenders, which will provide added security and extend the wear time to ideally at least every other day.

/2 points

Scenario 6

66-year-old obese individual with stoma in an abdominal fold. Appliance leakage causing contact dermatitis. Wear time has been less than 8 hours. Irritation is painful.

Image courtesy of Wound, Ostomy, and Continence Nurses Society™ image library.

Pouching Recommendations: After cleansing with a soft cloth and warm water the crusting technique should be applied using stoma powder and skin prep. Adapt skin barrier paste should be applied at 3 and 9 o'clock where the abdominal folds are deepest. Apply convatec esteem+ one-piece firm convex drainable pouch

Rationale: The crusting technique will help to heal and prevent further skin breakdown caused by leakage, it is highly absorbent and will help the appliance to stick by creating a new skin barrier. The barrier paste will help to fill in the deep crevices caused by the abdominal folds and will create a flatter surface for the appliance to adhere to. A firm convexity will help to protrude the stoma past the deep crevices and provide support in position changes.

/2 points

Scenario 7

76-year-old presents to the ostomy clinic with peristomal redness to periphery. Irritation limited to appliance tape collar region. Satellite lesions present. Stoma is budded and round. States has had ostomy for 6 months and has not had any problem until recently after Home Health changed the products.

Image courtesy of Wound, Ostomy, and Continence Nurses Society™ image library.

Pouching Recommendations: Review the proper way to remove the appliance by using adhesive remover wipes and gently pushing the skin away from the wafer using a finger. The crusting technique should be utilized using skin prep and an anti-fungal powder prescribed by the provider. Next a coloplast SenSura Mio flat one-piece appliance can be applied.

Rationale: The patient may be suffering from a fungal infection which is evidenced by the presence of satellite lesions, the irritation limited to the appliance tape collar region is also suggestive of possible medical adhesive related skin injury caused by improper removal of the appliance. Proper removal and adding an anti-fungal crusting to the area should help to eliminate the patient's discomfort and allow the area to heal. A flat one-piece appliance should be suitable since the patient's abdomen appears soft and flat with a budding stoma.

/2 points

Scenario 8

Individual presents to the clinic with stoma measuring 3.5 inches. Stoma protrudes above skin level. Uneven peristomal contours with skin folds at 3 and 9 o'clock. Moisture-related skin damage on peristomal skin related to leakage.

Image courtesy of Wound, Ostomy, and Continence Nurses Society™ image library.

Pouching Recommendations: After cleansing with a soft cloth and warm water the patient should apply the crusting technique using skin prep and stoma powder. Coloplast brave strip paste applied to the peri-stoma skin contours at 3 and 9 o'clock. Next the Convatec Esteem Synergy Two-piece cut to fit stomahesive skin barrier with white collar can be applied with the Convatec Esteem Synergy 2-Piece pro ostomy kit 3.5in Stoma appliance.

Rationale: The peristomal skin damage needs to be addressed to prevent further skin break down and heal the damaged skin, the crusting technique will aid in this. The strip paste applied to the areas with peri-stomal skin contours will provide a flatter surface and aid in blocking any leakage into these areas. An extra-large appliance that is available in 3.5 inches will be needed to and the convatec esteem 2-piece pro ostomy kit is available in this size. The stoma protrudes so may not need additional protrusion caused by convexity, but convexity should be considered if the leaking continues with the changes proposed.

/2 points

Scenario 9

Patient presents to ostomy clinic due to peristomal hernia causing peristomal skin breakdown. Abdomen is firm. Appliance wear time has decreased since parastomal hernia development. Stoma is flush with skin. Os between 5 and 6 o'clock area. Complains of odor. "The odor is really bad when I empty the pouch".

Image courtesy of Wound, Ostomy, and Continence Nurses Society™ image library.

Pouching Recommendations: Gently remove the appliance using adhesive remover wipes and pushing the skin away from the appliance. Cleanse with water and a soft cloth. Apply no-sting skin prep wo the peri-stomal area. Apply Coloplast brava protective seal convex skin barrier ring around the stoma to gently protrude the stoma. Next apply the Coloplast SenSura Mio Convex flip 1-piece drainable appliance.

Rationale: While gentle removal is always recommended, extra precaution should be taken to prevent further irritation and skin break down. A no-sting skin prep should be utilized for comfort as some skin preps have alcohol in them and can cause discomfort in areas that are open. A soft convex barrier ring will help to protrude the stoma slightly while being mindful of the underlying hernia. A flip appliance should be used to better contour to the bulging hernia and create an adequate seal with the goal being to replace the appliance every three days.

Odor Management Strategies: m9 odor eliminator drops can be used with each appliance change or after each emptying in order to help to decrease the smell. The patient can also be advised on what foods will likely cause a strong odor so that they can be avoided, such as onions, fish, eggs, garlic, broccoli, asparagus and others.

/3 points

Scenario 10

A pediatric Individual presents to the emergency room with stoma prolapse. Caregiver expresses inability to apply pouching system related to stomal protrusion. Stoma is red and healthy. No peristomal irritation.

Identify one pouching system with rationale for choice along with one consideration with appliance application specific to a prolapsed stoma.

Image courtesy of Wound, Ostomy, and Continence Nurses Society™ image library.

Pouching Recommendations: The sensura mio kids flex two-piece barrier paired with the SenSura Mio Kids Flex filtered ostomy pouch two-piece system is recommended due to the shape of the pediatric belly which is often rounded. This appliance comes in a two-piece option which should be utilized, and the stomal opening of the wafer should have small radial slits cut that will better accommodate the changing shape and size. The patients can be educated on the use of sugar to help to prolapsed stoma size decrease during appliance changes, but that the stoma will protrude again.

Rationale: The SenSura Mio kids barrier is designed for the sensitive skin of the pediatric population and has a star-shaped wafer that will conform better to the pediatric belly that is usually rounded. A two-piece appliance will help to better visualize the stoma and ensure appropriate placement now that it is more complicated by the protruding stoma. Sugar can be applied prior to application in an effort to reduce its size, but the care takers should be educated that this is a temporary fix for appliance changes.

Further Considerations: The stoma should be gently lifted during measurements to attempt at getting the correct size of the appliance opening. If the stoma is larger than the opening a barrier ring should be utilized to protect the skin since the wafer will need to be cut larger. Pediatric stoma guards are available and should be recommended to better protect the stoma of an active child.

/3 points

Scenario 11

A 28-year-old with an ileostomy presents to the clinic for a follow-up evaluation. During the visit, the patient expressed the pouch is too long with the end of the pouch falling into the groin area. Assessment notes stoma red, viable, and protrudes above skin level. Abdominal space is small with short distance from stoma to groin. Current appliance is a one-piece cut to fit skin barrier. Pouch length 12". Name at least two alternative pouching management system options and rationale for each.

Image courtesy of Judy Mosier, MSN, RN, CWOCN

Pouching option #1: Hollister new image two-piece drainable mini ostomy pouch- lock 'n roll microseal closure which is used with the new image two-piece skin barrier.

Rationale: This product has a shortened length of seven inches which should provide greater comfort for the patient and ideally not go into the groin area. Various size openings are available to accommodate different size stomas.

Pouching option #2: Coloplast SenSura Mio Kids 1-piece Drainable pouch.

Rationale: While a pediatric pouch isn't a viable option for most adults, a small pouching field may warrant trying this option if the stoma is smaller than 1 3/8" in size, and the pouch length is slightly smaller than the other option at 6 ¾". These pouches may need to be emptied more frequently but if the preferred products will be based on what matters most to the patient.

/4 points

Scenario 12

You are in your office and take a call from a patient. The patient voices having to change the skin barrier wafer more frequently, itching under the skin barrier, and desire to change manufacturers. The patient agrees to be seen in the clinic.

In preparation for this visit, you go to your resources to help you.

1. **Identify one manufacturer (Hollister, Convatec, Coloplast, NuHope, etc)**
2. **Identify three skin barrier wafers from that manufacturer that differ in composition/ingredients.**
3. **Identify the type of ostomy or situation in which the wafer is appropriate.**

For example: (can not be used)
Manufacturer: B. Braun
1. Skin barrier wafer: Flexima 3S

Composition & Purpose: Made of new generation plastics making it more soft and flexible. Appropriate for any type of ostomy and active individuals

2. Skin barrier wafer: Flexima… etc

Manufacturer:

Skin barrier Wafer 1: Hollister standard wear skin barrier

Composition & Purpose: Standard wear skin barriers are composed of tackifiers and polymers and are appropriate for most ostomies, including pediatric patients. They are both gentle and durable with a moderate level of adhesion and erosion resistance.

Skin barrier Wafer 2: Hollister extended wear skin barrier

Composition & Purpose: Extended wear skin barriers have an increased amount of adhesion and durability when compared to a standard wear barrier and are more suitable for those who have high output ostomies, urostomies since they tend to be more corrosive, or those who sweat a lot.

Skin barrier Wafer 3: Hollister CeraPlus skin barrier

Composition & Purpose: CeraPlus skin barriers is advertised as an extended wear barrier that is made without a tape border or latex, but is infused with Ceramide. The ceramide helps to heal denuded and damaged peri-stomal skin by decreasing trans epidural water loss. This can also help to protect fragile skin that is still intact by protecting the skin's natural moisture barrier.

/6 points

Scenario 13

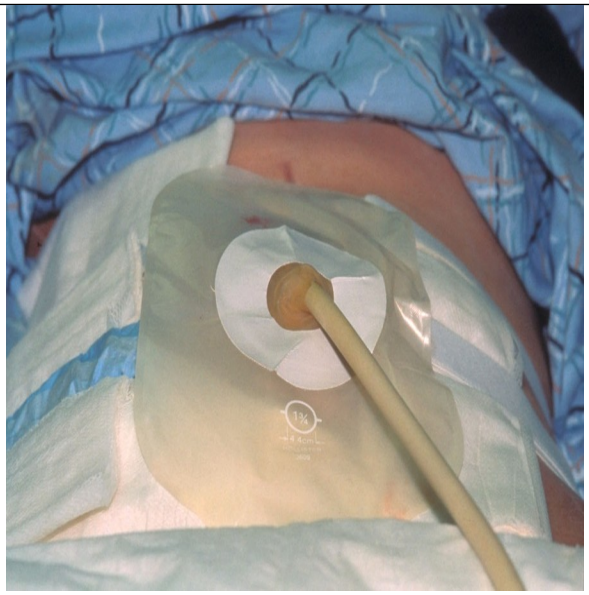

Image courtesy of Judy Mosier, MSN, RN, CWOCN

You are consulted to see a patient with a new colostomy. Upon entering the room, you note there is an indwelling catheter in the stoma. Nursing reports pouch leakage as the hole in the pouch for the tube is cut to fit the stoma resulting in a "big hole" in the front of the pouch. The surgeon's request is to continue to pouch the stoma while pulling the tube through the pouch.

Describe how you will secure the tube while separately pouching the stoma and the tube

…using a commercial access port: A commercial access port provides the necessary supplies such as a hole punching tool and graduated nipple. The appliance first has a hole created using the hole punch assembly (this will be easier with a two-piece appliance or a one-piece with a window). Once the hole punch is in place and punctured, place the graduated nipple over the appliance and snap into place. The hole punch can then be removed. The graduated nipple should be cut slightly smaller than the tubing, as it will stretch slightly to accommodate the tube. The tube should then be threaded through and the appliance secured to the skin.

…in the absence of a commercial access port: If a commercial access port is not available the top of a baby bottle can be modified to supplement. The top should be cut off of the bottle leaving the nipple, cap, and threaded top of the bottle. Place the threaded top of the bottle within the appliance (again this is easier done with a two piece appliance or with an appliance with a window) and cut a small hole in the appliance in the center of the cap. Cut a small hole in the nipple that is slightly smaller than the tubing and place the nipple into the cap. Gently thread the tubing through the hole in the appliance and through the tip of the nipple. Screw the threaded bottle cap together with the nipple and cap on the outside of the appliance and secure the appliance to the skin.

/2 points

Scenario 14

86-year-old obese individual presents to the ostomy clinic with a retracted stoma. States has a soft-formed stool once a day. Pouch changed daily as stool goes under the skin barrier wafer, and at times, no stool goes into the pouch.

It is determined a convex pouching system should be used. A convex skin barrier wafer is not available.

Identify two strategies to create convexity in the absence of a convex skin barrier wafer.

Image courtesy of Wound, Ostomy, and Continence Nurses Society™ image library.

Alternative convexity option #1: A barrier ring can be stacked and molded to mimic the convexity of an appliance and placed around the stoma while gently pushing into the peristomal skin to protrude the stoma. By stacking the barrier ring becomes thicker and easier to mold into a pinched position.

Alternative convexity option #2: Ostomy moldable strips may be placed around the opening of the wafer to created a moldable ridge. The appliance should be cut slightly larger to accommodate adding a layer to the opening, and then the strip molded to the correct size and shape.

/2 points

Scenario 15

The WOC nurse is consulted to manage a wound with a stoma in proximity. The surgeon has consented to pouching the stoma in the same pouch as the wound. It is determined to be the best approach.

Identify one product that can be used to achieve this.

Image courtesy of Judy Mosier, MSN, RN, CWOCN

Pouching option: A Convatec Eakin fistula and wound pouch would be a viable option if the wound and stoma are within close enough proximity. There are various sizes available and if a large enough pouching field is available it is able to be cut to accommodate the size and shape of the stoma and wound while also protecting the peri-skin and containing the fluid. The pouches are also available in drainable options so that they can be emptied as needed.

/1 point

Scenario 16

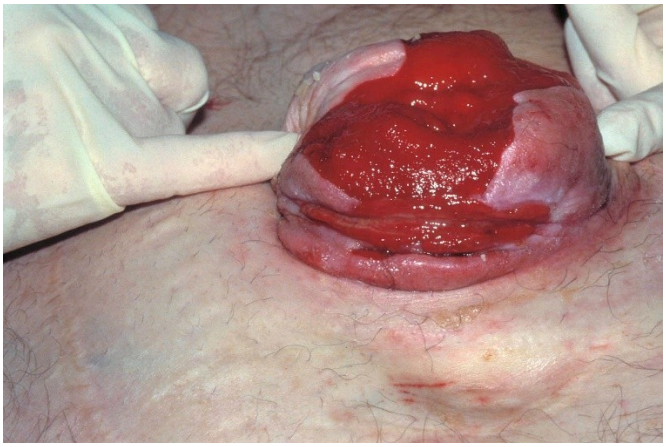

A 70-year-old patient presents to the ED with pouching difficulty. They report using a fistula pouch previously, however, this has become too costly of an option. Their stoma measures 4 1/3” in diameter and they are at a loss for pouching options. The patient will need pouching long term. Identify one product pouching system that is manufactured to accommodate a stoma of 4” or greater in size.

Image courtesy of Dr. James Wu

Pouching option: The Hollister Premier One-Piece high output ostomy pouch is able to accommodate a stoma this large. The wafer is cut-to-size with a limit of 110mm so should be just large enough for this stoma. It has an extended wear barrier, access window, and soft tap drain. Hopefully this product will be more affordable and comfortable for the patient as options are limited for a stoma this large.

/1 point