Cleveland Clinic

Virtual Journal Entry with Plan of Care & Chart Note

Student Name: Miranda Prawdzik Day/Date: 10/22/2024

Setting: Hospital • Ambulatory Care • Home Health Care ☒ Other: _____

WOC nurses function as consultants and develop plans of care for other care givers as a guide to providing care in the WOC nurse's absence. For this assignment, a chart review and assessment information are provided for you. Use this information to write a chart note and to develop a plan of care.

Chart Review/History	*Age/sex:* 45-year-old female *PMH:* anemia, anxiety, fibromyalgia, hypercalcemia, major depressive disorder recurrent with severe psychotic symptoms, and tongue carcinoma. Partial mandibulectomy and chemoradiation last year *CC: R*ecurrent tongue lesion with metastasis to the lung, altered mental status. *Meds:* Currently taking Bumex 2mg BID. Has been taking Tylenol for pain but states it is not helping. *Social hx:* Denies recent smoking, ETOH or illicit drug use. *Labs*: Na 133, K 4.3, Cl 101, BUN 20, Glu 125, WBC 7.0, Hgb 9.7, HCT 30.2 %, PLT 245

Assessment/encounter:
Ostomy nurse consulted for painful G-tube site. Being seen with HHC nurse.
LOC: Patient awake and alert,
Interview with patient who states

- Pain is "10/10"
- Redness and bleeding under her new G-tube bumper for "weeks"
- No dressing placed under g-tube bumper; has a suture in place.
- No tube securement device used.
- Takes liquid Tylenol to manage pain. "Sometimes" uses ordered narcotics to "take the edge off".
- G-Tube replaced last month
- Tube feeding schedule of Isosource 1.5 cal; 4 cans per day.
- Does take some PO food and fluids.
- Weight loss of 25 lbs. in 2 months. Weight 148 lbs. before surgery and 123 lbs. at present
- Followed by dietary and a pain management specialist.

Stoma: not visible
Stoma size: N/A; tube bumper 2.0 x 2.0 in.
Tube bumper: - one suture noted, loose. No effluent drainage noted.
Peri-stomal skin: skin friable and macerated under bumper. Painful. Beyond bumper is dry and intact.
Abdominal plane: Flat
Education

- Develop education below.

The patient is anxious regarding her pain to the area and is worried about needing another tube replacement. She is open to trying new interventions.

What specific interventions would you choose as the Ostomy provider? Make sure to include below, considering both short and long term plans for this patient.

Photo: 12

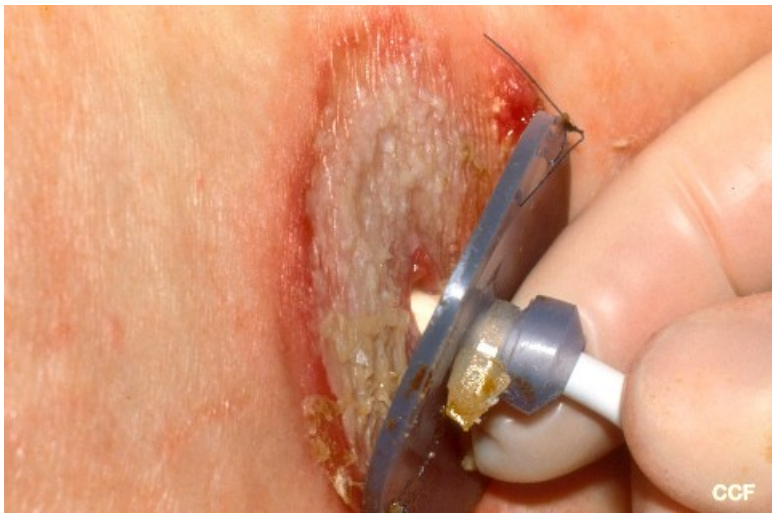

Using critical evaluation of the provided encounter data, identify what could have been done or done differently regarding assessment data collected, treatment recommendations, consults, referrals, tests, and education.

1. Identify what could have been done or done differently regarding assessment data collected, treatment recommendations, consults, referrals, tests, and education.

1. One thing I may have done differently in the data collection/assessment is asking further questions about the G-tube and how it is typically managed at home, both to the patient and the home health care nurse.
    a. How long has she had the G-tube/when was it initially placed, why was it placed, has she experienced this issue before, is the bumper size the normal size she uses, what has she been using on the site or what care has been done with the site prior to consult, when was the irritation first noted, or does she normally use a tube securement device or dressing?
    b. Assessing what routine skin care/G-tube care is performed? Is the skin routinely cleaned and assessed?
2. I would also assess that the GT placement is correct, and balloon is intact and filled (as indicated, if tubing has balloon).
3. I also may have performed/ordered more nutritional lab work (liver and kidney panel, total electrolytes, total protein), as the patient has lost a significant amount of weight in the past two months. Having a new baseline could determine if supplemental tube feeds need to be adjusted.
    a. Consultation to nutritional services should be performed.
4. I would explore the reported weight loss more in depth, determining if it was intentional and if there was a great change in intake or appetite.
    a. Increased weight loss or gain could contribute to tube displacement or incorrect bumper sizing.
5. Consult/referral to pain management services to alter medication course, as current course is not effective.
6. I would have assessed the patient's mental status more and how involved the patient is in daily care, how independent the patient is.
7. I would have performed a more thorough medication reconciliation for the patient, as only two medications are listed for use.

Using the information from the encounter and your critical evaluation develop a plan of care to be executed by other members of the healthcare team in your absence. Statements should be directive and holistic. Write as nursing orders. (For example: *What ostomy pouch change regimen would you recommend)?*

2. WOC Plan of Care (include specific products used)

- Cleanse GT site and tubing daily.
    - Wash peristomal skin and tubing with a mild, non-scented soap and water.
    - Rinse area with water and gently pat completely dry.
    - When crusting noted around opening or site, use a cotton-tipped applicator moistened with water to gently remove.
- Perform wound care/dressing changes daily with skin cleansing, and as needed when dressing soiled or compromised.
    - Remove old dressing, cleanse area as described above.
    - Cut thin foam dressing to size of wound, cut slit in foam dressing from the edge to the middle to allow foam to be applied circumferentially around GT, underneath tube bumper.
        - ****Alternative: with signs of infection (see below) may use antimicrobial foam dressing impregnated with silver, and dressings changed every 5-7 days.*
    - May use paper tape to hold foam in place around the edges as needed.
- Notify WOC team of signs of infection or wound worsening at the GT site.
    - Increased redness, warmth, increased exudate, increased or uncontrolled bleeding, increase in size of wound, malodorous, increased pain, etc.
- Utilize GT securement device as needed if tube easily moves in and out of insertion site.
    - Adhesive tube attachment device
- Referral to GI team to assess for readiness for suture removal on bumper for ease of daily care.
- Assess for correct GT positioning daily.
    - Examine external tubing and measurement at the insertion site is correct (refer to insertion note for depth of insertion).
    - Ensure internal anchor/bumper is against stomach wall by gently pulling up on tubing. Then slide external bumper down (as needed/indicated) to rest lightly against abdominal skin without excess tension or pressure.
- Assess internal bumper/balloon weekly (as indicated).
    - Attach syringe to balloon port and pull back to check water level weekly.
    - Replace water in balloon with correct amount when needed.
- Assess for tube patency prior to each feeding or medication administration.
    - Ensure tubing is free of kinks or obstructions.
    - Flush tube with at least 30ml of tap water before and after tube feedings.
    - Flush tube with at least 15ml of tap water before and after medication administration.
    - Notify primary care provider if tubing becomes clogged and cannot be unclogged at home.
- Refer to nutritional services to reassess tube feeds and nutritional status/needs post weight loss.
- Refer to speech language pathology team for swallow evaluation and oral diet/fluid recommendations.
- Refer to pain management team to reassess current pain medication course and adjust PRN medications.
- Refer to psychology and counseling services to assess if patient is being followed by them, adjust current management plan for increased anxiety.
- Refer to oncology team for continued cancer treatment plan and management.
- Consult to palliative care for symptom management support, comfort support, and continued care planning.

Write a chart note giving careful consideration to the chart review information, how the patient was assessed, the problems, and the rationale behind the plan of care. The WOC nurse consultant/specialist note should begin with why you are seeing the pt; Initial visit for…, follow- up visit for…, evaluation and management of…, etc. Then, describe the visit. Be sure to include any physical assessment, interactions, and specific products used/recommended for use. Write in a manner others will be able to understand and be able to interpret your plan of care.

3. Chart note:

The patient is a 45-year-old female with a past medical history of anxiety, major depressive disorder with recurrent psychotic symptoms, anemia, hypercalcemia, fibromyalgia, and recurrent tongue carcinoma with metastasis to the lung. The last chemoradiation therapy was performed in 2023. Pertinent patient surgical history includes partial mandibulectomy (2023).

The patient presents for initial WOC consultation of painful G-tube insertion site. The patient is seen at home by WOC team with home healthcare nurse also present for assessment. The chief complaint upon assessment is “10/10 pain” at G-tube site with redness and bleeding present under the bumper for “weeks” prior to consult. The patient reports current G-tube was just replaced last month, 9/2024, with an unknown initial G-tube placement procedure date. The patient is currently being followed by home health nursing, nutritional services, and pain management services.

Physical Assessment:

- Patient seen at home with home healthcare nurse present at time of assessment.
- Patient alert, oriented, and follows commands. Patient is communicative with WOC staff and verbalizes readiness to discuss education and treatment options.
- Patient endorses feeling anxious and overwhelmed regarding GT pain, needed site care, and any tube replacement needed.
- Patient reports 10/10 pain at G-tube site. (see current pain management medications below)
- Review of systems deferred.
- GU visual and physical examination performed. Abdominal contour flat, with G-tube in place.
- G-tube with no dressing under bumper, no securement device utilized, and singular, loose suture in place for bumper securement.
- Patient reports redness and frequent bleeding from GT site, underneath bumper.
- Patient receives Isosource 1.5 Cal, 4 cans per day. Patient reports small oral food and fluid intake as well as tube feeds.
- The patient reported a weight loss of 25 lbs. in the last 2 months. Weight 148 lbs. before surgery and current weight of 123 lbs.
- Skin breakdown noted under GT bumper (see below). No other evidence of skin breakdown noted elsewhere, skin is dry and intact.

Gastrostomy Tube

-Stoma not visible.
-GT last replaced 9/2024.
-Tube intact, clamped/capped on assessment.
-Tube bumper size 2.0 in. x 2.0 in.
-Tube bumper with one, loose suture noted.
-No dressing or securement device in place on assessment.
-Peristomal skin friable, macerated, moist circumferentially underneath bumper. Skin red and pale, shiny, with small dried yellow crusting and dried blood noted on and around tubing. Painful.
-No effluent drainage noted at the time of assessment.
-Skin beyond bumper is dry and intact. Abdominal plane flat.
-See media above for further wound/skin appearance.

Social History:

- No reported alcohol or drug use
- No reported smoking
- Current client with home healthcare
- Severe anxiety and major depressive disorder, with recurrent psychotic symptoms

Current Medications:

- Bumex 2mg tablet BID, unknown route
- Tylenol PRN for pain, liquid form, unknown dosage/route/time
- Patient reported ordered narcotic use PRN for pain as well, unknown drug/dosage/route/time
    - Follow-up and further information needed from pain management team.

Most Recent Lab Work/Tests:

- No vitals obtained at this visit.
- No recent testing or scans available for review at time of visit.
- Recent lab work is as follows-
    - Sodium 133, Potassium 4.3, Chloride 101, BUN 20, Glucose 125
    - WBC 7.0, Hemoglobin 9.7, Hematocrit 30.2 %, Platelets 245

- Most current weight 123 lbs.

Reviewed WOC Patient Education:
Importance of daily, quality skin care to the GT site.
Daily wound care, dressing changes to the affected site as ordered.
GT correct placement and securement, routine assessment of placement and bumper.
Correct tube feed and medication administration with a GT.

Recommendations:
Initiate daily skin cleansing and wound care to the affected skin at the GT site. (see care plan for detailed dressing plan)
Utilize device/tubing securement device as needed if tubing becomes easily displaced.
Refer to GI team for suture removal.
Assess for correct GT placement daily and internal balloon securement weekly.

WOC team to follow up routinely and as needed with patient.

You should have a learning goal for each clinical day. What was your goal or reason for choosing this particular mini case study? Were you able to meet this goal? Why or why not?

4. What was your goal in choosing this case?

I chose this virtual scenario because I had little experience with G-tubes during in-person clinical time and wanted to learn and review information about bedside care for a G-tube. I also have little experience with G or J tubes in my current work position, only OG and NGs. So, this clinical situation was helpful in meeting this goal as I was able to review a plan of care for a patient with a G tube, daily management, and how to manage skin care related to the G-tube.

Reviewed by: _____ Date: _____

CRITICAL ELEMENTS	Completed	Missing
Medical record note reflects that of a specialist:		
• Identifies why the patient is being seen		
• Describes the encounter including assessment, interactions, any actions, education provided and responses		
• Includes pertinent PMH, HPI, current medications and labs		
• Identifies specific products utilized/recommended for use		
• Identifies overall recommendations/plan		
Plan of Care Development:		
• POC is focused and holistic		
• WOC nursing concerns and medical conditions, co-morbidities are incorporated		
• Statements direct care of the patient in the absence of the WOC nurse		
• Directives are written as nursing orders		
Thoughts Related to Visit:		
• Critical thinking utilized to reflect on patient encounter		
• Identifies alternatives/what would have done differently		
Learning goal identified		

Cleveland Clinic