R.B. Turnbull, Jr. MD School of WOC Nursing Education

Mini Case Scenarios: Wounds

Student Name: Melinda Grace Taft **Date:** 07/09/2024

Reviewed by: _____ **Date:** _____

Score: /96

For the following wound case scenarios:

1. Identify the type of wound pictured.
2. Apply wound characteristics provided to identify recommendations/nursing orders for this patient & the wound.
3. Include the following in the recommendations/orders
    a. Dressing
        i. Type of dressing
        ii. Brand name(s)
        iii. Secondary dressing if needed
        iv. Dressing change schedule
    b. Other nursing orders pertinent to successful wound healing or prevention
    c. Rationale for choices
4. Provide an alternative to your initial dressing choice. This should be a product substitution, not simply a brand name substitution.
5. Answer any additional questions.

A case study has been completed for you below as an example.

Scenario Example

85-year-old in an extended care facility has a skin tear on her right forearm after a recent fall. The skin tear has been classified as Type ??? as described by the International Skin Tear Advisory Panel (ISTAP).

Image courtesy of Wound, Ostomy and Continence Nurses Society image library.

Wound type: Skin tear, Type 2
(1 point)

Wound Nurse recommendations/orders:

1. Use no rinse, pH balanced bath wipes at bathtime vs. soap, minimize rubbing at bath time, & gently dry fragile skin
2. Apply mesh contact layer (Hollister Adaptic)
3. Moisturize both arms daily with Medline Remedy moisturizing lotion
4. Wrap with roll gauze (Kerlix).
5. Change dressing on every shower day or if wet or soiled
6. Use long sleeve garments or sleeve covers for patient during waking hours

(3 points)

Rationale for choices

1. Bath wipes are pH balanced & soap is usually alkaline & difficult to rinse if person not showering
2. Rubbing creates friction which may cause skin tears
3. Contact layer prevents dressings from sticking to wound
4. Skin moisturizing is a preventive measure for skin tears
5. Roll gauze keeps contact layer in place & patient from touching wound & is non-adhesive
6. Long sleeves protects patient's skin and discourages picking at dressing

(3 points)

1 alternative primary/secondary dressing: Non-adhesive foam dressing, 5 layers, (Allevyn) secured with elastic mesh dressing (Medline elastic retention dressing).
(1 point)

Scenario 1

You are asked to assess a new resident admitted with a sacral wound. Patient is 82-year-old and admitted with dementia. Wound on sacrum with 100% yellow slough and brown necrotic tissue at wound edges. Wound measures approximately 4 cm x 3 cm x 2 cm. Periwound with blanchable erythema.

Image courtesy of Wound, Ostomy and Continence Nurses Society image library.

Wound type: Pressure Injury, Unstageable

(1 point)

Wound Nurse recommendations/orders: Enzymatic debridement using Collagenase SANTYL ointment, petrolatum-impregnated gauze for moisture retention, foam cover dressing

Wound care to the sacrum, daily and PRN if soiled:

Supplies needed: normal saline wipe, 4x4 gauze, sterile cotton-tipped applicator, Collagenase SANTYL ointment, Covidien Vaseline Petrolatum Gauze Strip, Mölnlycke Mepilex Flex Border Dressing (*foam dressing with silicone tape borders*)

1. Cleanse the site with a normal saline wipe, and gently pat dry.
2. Using a sterile cotton-tipped applicator, apply a nickel-thick layer of Collagenase to the wound bed and edges.
3. Place the petrolatum gauze strip over the wound bed.
4. Cover the site with the Mepilex Flex Border Dressing.

Pressure injury prevention

- Turn/Reposition the patient q.2h for pressure redistribution.
- Use foam wedges and Z-Flo fluidized positioners to help redistribute pressure.
- Perform head-to-toe skin checks for signs of pressure at least once per shift, or more often per policy. Promptly notify the clinician/MD if areas concerning for pressure are identified.
- Maintain the head of the bed at 30 degrees.

(3 points)

Rationale for choices:

- Collagenase effectively works to remove non-viable tissue from a wound bed. Specifically, it digests the collagen that adheres slough and eschar to the wound bed.
- Manufacturer guidelines recommend application of a “nickel-thick” layer, around 2 mm, to the wound bed, covered by a moisture-retentive dressing, such as Vaseline-impregnated gauze, for optimal results.
- Manufacturer guidelines recommend reapplication of the ointment every 24 hours, warranting daily

dressing changes. • Antimicrobial products, such as iodine, Vashe (hypochlorous acid), and Dakin's (sodium hypochlorite) are not compatible with collagenase. Therefore, normal saline is appropriate to use for cleansing. • Since the patient has already sustained a pressure injury, measures should be taken to prevent another occurrence. Standard, evidence-based interventions include frequent repositioning [every 2 to 4 hours], use of positioning devices to redistribute pressure, floating the heels, and routinely monitoring the skin for signs of pressure [which should be immediately reported to the MD for intervention]. Keeping the bed in a low position, at around 30 degrees or lower, can prevent the patient from sliding or slumping in bed; this reduces pressure on the sacrococcygeal region. **(3 points)**
1 alternative primary/secondary dressing: Silver-infused hydrogel (ex. Cardinal Health Hydrogel +Ag), composite dressing to cover (ex. McKesson Adhesive Island Dressing). Change daily and PRN if soiled. **(1 point)**

/8 points

Scenario 2

The wound care nurse is consulted to see a 54-year-old, post op day 4 after an abdominal surgery. Left heel has non-blanchable purple discoloration.

Image courtesy of Judy Mosier, MSN, RN, CWOCN.

Wound type: Pressure Injury, Deep Tissue Pressure Injury

(1 point)

Wound Nurse recommendations/orders: Foam heel dressing

Wound care to the left heel, every day and PRN if soiled:
Supplies needed: normal saline wipe, 4x4 gauze, Aquacel Foam Heel Dressing

1. Cleanse the site with normal saline, and pat dry.
2. Cover the heel with the foam dressing.

Closely monitor the site, and promptly notify the clinician/MD if the site evolves:

- the affected area becomes larger
- the affected area opens/presence of skin breakdown
- presence of non-viable tissue and/or anatomic structures

Pressure injury prevention

- Turn/Reposition the patient q.2h for pressure redistribution.
- Use foam wedges and Z-Flo fluidized positioners to help redistribute pressure—maintain Z-Flo positioners underneath both heels
- Perform head-to-toe skin checks for signs of pressure at least once per shift, or more often per unit policy. Promptly notify the clinician/MD if areas concerning for pressure are identified.
- Maintain the head of the bed at 30 degrees.

(3 points)

Rationale for choices:

- A foam dressing can be applied to pad and cushion the affected site. This dressing serves as protection against pressure and further injury to the heel.
- Floating the heels relieves pressure and can help prevent the development of a pressure injury to the

right heel. • Close monitoring is warranted to observe for site evolvement. If the DTI evolves in any way, the clinician/MD should be notified. At this point, a different form of topical therapy may be required to support healing. • Since the patient has already sustained a pressure injury, measures should be taken to prevent another occurrence. **(3 points)**
1 alternative primary/secondary dressing: Hydrocolloid (ex. McKesson Hydrocolloid Dressing THIN). Change every 3 days and PRN if soiled. **(1 point)**

/8 points

Scenario 3

A 70-year-old arrives at the outpatient wound clinic with a nonhealing wound located on gaiter area of right lower extremity. The wound measures approximately 5 cm x 2.5 cm x 0.5 cm. The wound is a shallow, irregular shaped ulcer with moderate amount of exudate. Periwound is macerated. Hemosiderin staining is noted to BLE. Patient has ABI of 0.85 to RLE and 0.90 to LLE

Image courtesy of Wound, Ostomy and Continence Nurses Society image library.

Wound type: Venous Ulcer

(1 point)

Wound Nurse recommendations/orders: Alginate dressing, foam cover dressing

Wound care to the right lower extremity, BID and PRN if soiled/saturated:

Supplies needed: 4x4 gauze, Vashe Wound Solution, 3M Cavilon No-Sting barrier film pad, 3M Tegaderm High Integrity Alginate dressing, Mölnlycke Mepilex Ag Border dressing

1. Apply Vashe-soaked gauze to the wound as a compress for at least 30 seconds. Gently pat dry.
2. Dab a no-sting barrier film pad along the peri-wound skin.
3. Apply a strip of alginate dressing into the wound bed.
4. Cover the site with a Mepilex Ag Border dressing.

- Keep the skin of the right lower extremity moisturized with Vaseline ointment.
- Wrap the right lower extremity in an ACE bandage.
- Elevate the extremity 3 times a day for 30 minutes.

(3 points)

Rationale for choices:

- Based on the patient's ankle-brachial index values, there is poor arterial perfusion to both lower extremities. However, the wound demonstrates characteristics of a venous ulcer: an irregular shape, moderate exudate, hemosiderin staining, and location on the medial malleolus.
- Important aspects of topical care for venous ulcers include exudate management and antimicrobial protection. Biofilm is a contributing factor towards the chronicity of venous ulcers, so utilizing products with antimicrobial properties can play a vital role in healing. Vashe Wound Solution is an antimicrobial, non-cytotoxic cleanser composed of 100% hypochlorous acid. Alginate dressings are highly absorptive and can manage the wound's exudate to support an appropriately moist wound bed. The Mepilex foam dressing is infused with silver, which can offer additional antimicrobial protection.
- Since the peri-wound skin is macerated, a liquid skin barrier should be utilized to protect the skin from further irritation or breakdown.

• In addition, measures should be taken to support venous blood return, namely utilizing compression garments (stockings, wraps, etc.) on the affected extremity, as well as elevation. **(3 points)**
1 alternative primary/secondary dressing: Silver-infused hydrofiber dressing (ex. Aquacel Ag Advantage), covered by a composite dressing (ex. Medline Stratasorb Island Dressing). Change BID and PRN if soiled/saturated. **(1 point)**

/8 points

Scenario 4

An 85-year-old is admitted to the hospital with a stage ??? pressure injury on sacrum and is bedridden. Full thickness wound measures approximately 8 cm x 10 cm x 0.4 cm. Wound bed pink with small amount of yellow slough. No structures, no bone noted. Wound has moderate serosanguineous drainage.

Image courtesy of Judy Mosier, MSN, RN, CWOCN.

Wound type: Pressure Injury, Stage 3

(1 point)

Wound Nurse recommendations/orders: Silver-infused hydrofiber dressing, foam cover dressing

Wound care to the sacrum, daily and PRN if soiled/saturated:
Supplies needed: normal saline, gauze, 3M Cavilon No-Sting barrier film pad, Aquacel Ag Advantage hydrofiber ribbon, Mölnlycke Mepilex Sacral Border Dressing

1. Cleanse the wound with saline-soaked gauze. Thoroughly pat dry.
2. Dab a no-sting barrier film pad along the peri-wound skin.
3. Loosely pack the Aquacel Ag ribbon into the wound bed.
4. Cover the site with the sacral border dressing.

Pressure injury prevention

- Turn/Reposition the patient q.2h for pressure redistribution.
- Use foam wedges and Z-Flo fluidized positioners to help redistribute pressure.
- Perform head-to-toe skin checks for signs of pressure at least once per shift, or more often per unit policy. Promptly notify the clinician/MD if areas concerning for pressure are identified.

(3 points)

Rationale for choices:

- Hydrofiber dressings are highly absorptive and can manage the patient's moderate amount of exudate. They can also promote autolytic debridement of the non-viable tissue. Aquacel Ag is infused with silver, which can provide antimicrobial protection for the wound.
- Due to the moderate amount of drainage, an alcohol-free liquid skin barrier should be applied to the peri-wound skin to prevent maceration.
- The foam sacral border dressing also has high absorptive capacity. The shape of this dressing is designed to completely cover the sacral region, providing protective cushioning.
- Since the patient has already sustained a pressure injury, measures should be taken to prevent another occurrence.

(3 points)

What support surface would you recommend and why? Low air loss

- This mattress can help evenly distribute the patient's weight, resulting in continuous pressure redistribution.
- Utilization of a low air loss mattress is associated with improved healing of pressure injuries.
- It's not stated that the patient has spinal instability (a contraindication for use), so this is a safe option for the patient.
- The mattress is porous. Air is circulated out through the mattress and across the skin for moisture control.

(1 point)

/8 points

Scenario 5

56-year-old hospitalized for cardiac surgery. During the hospital stay, developed a blister related to pressure on right heel. The blister has now ruptured.

Image courtesy of Judy Mosier, MSN, RN, CWOCN.

Wound type: Pressure Injury, Stage 2

(1 point)

Wound Nurse recommendations/orders: Transparent film dressing

Wound care to the right heel, every 3 days and PRN if soiled:

Supplies needed: normal saline wipe, 4x4 gauze, 3M Tegaderm Transparent Film Dressing

1. Cleanse the site with a normal saline wipe, and gently pat dry.
2. Cover the site with a transparent film dressing.

(3 points)

Rationale for choices:

- Transparent film dressings are adherent and help maintain an appropriately moist wound environment for tissue healing. They're appropriate for use with shallow wounds, including stage two pressure injuries. Being transparent, they allow for visualization of the wound bed without having to lift or remove the dressing.
- Transparent film dressings can stay in place for several days, which allows for less frequent dressing changes/disturbance of the site.

(3 points)

- **1 alternative primary/secondary dressing:** Manuka honey dressing (ex. Medihoney gel), foam cover dressing (ex. Mölnlycke Mepilex Lite). Change daily and PRN if soiled.

(1 point)

/8 points

Scenario 6

82-year-old arrives to the acute care setting with a pressure injury on the right ischium. Patient has been cared for at home by spouse and spends many hours per day in a wheelchair.
The wound measures approximately 6 cm x 8cm x 2 cm. Wound bed 80% pink tissue with bone visible. Small amount of tan drainage noted with assessment. Periwound intact.

Image courtesy of Wound, Ostomy and Continence Nurses Society image library.

Wound type: Pressure Injury, Stage 4

(1 point)

Wound Nurse recommendations/orders: Aquacel Ag Advantage Hydrofiber ribbon dressing, foam cover dressing

Wound care to the right ischium, daily and PRN if soiled/saturated:
Supplies needed: Vashe Wound Solution, 4x4 gauze, Aquacel Ag Advantage hydrofiber ribbon dressing, scissors, Mepilex Border Flex foam dressing.

1. Cleanse the wound by applying Vashe-soaked gauze as a compress for at least 30 seconds. Gently pat dry.
2. Loosely pack Aquacel Ag into the wound bed.
3. Cover the site with the Mepilex foam dressing.

Pressure injury prevention

- Turn/Reposition the patient q.2h for pressure redistribution.
- Float the patient's heels.
- Use foam wedges and Z-Flo fluidized positioners to help redistribute pressure.
- Perform head-to-toe skin checks for signs of pressure at least once per shift, or more often per unit policy. Promptly notify the clinician/MD if areas concerning for pressure are identified.
- Limit the amount of time spent in the wheelchair to 2 hours per day. When the patient is sitting in the wheelchair, ensure that a static air seat cushion is in place for pressure offloading. Reposition q.1h while in the wheelchair.

(3 points)

Rationale for choices:

- Hydrofiber dressings are highly absorptive and can maintain an appropriately moist wound bed. Aquacel Ag is infused with silver, which can provide antimicrobial protection for the wound.
- Vashe Wound Solution is a non-cytotoxic cleanser that provides antimicrobial protection.
    - Although the wound is not demonstrating overt signs of infection, infection prevention is an important aspect of care given the exposure of bone within the wound bed.
- Since the patient has already developed a pressure injury, interventions to prevent the development

pressure injuries over other bony prominences should be implemented. • The Mepilex foam dressing will cushion and protect the site. It also is absorptive and can manage wound exudate. • Time spent in the wheelchair should be restricted to reduce pressure to the site of the injury. • Since the patient has already developed a pressure injury, interventions to prevent the development pressure injuries over other bony prominences should be implemented. **(3 points)**
1 alternative primary/secondary dressing: Collagen dressing (ex. Puracol plus Ag), dry gauze to cover, secure with Medline Medipore tape. Change daily and PRN if soiled. **(1 point)**

/8 points

Scenario 7

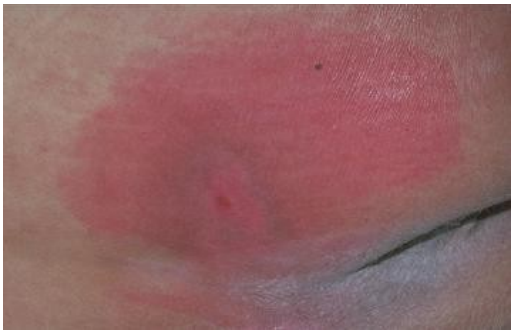

The wound care nurse is consulted to see a 66-year-old who developed non-blanchable erythema on right sacrum after being on bedrest for the past 24 hours.

Image courtesy of Judy Mosier, MSN, RN, CWOCN.

Wound type: Pressure Injury, Stage 1

(1 point)

Wound Nurse recommendations/orders:

Wound care to the right sacrum, daily and PRN if soiled:

1. Cleanse the site with saline-soaked gauze, and gently pat dry.
2. Cover the area with a Mepilex Border Sacrum dressing.

- Closely monitor the site, and promptly notify the clinician/MD if the site evolves
  - the affected area becomes larger
  - skin breakdown
  - blistering (serous or blood-filled)
  - presence of non-viable tissue and/or anatomic structures

Pressure injury prevention

- Turn/Reposition the patient q.2h for pressure redistribution.
- Use foam wedges and Z-Flo fluidized positioners to help redistribute pressure.
- Perform head-to-toe skin checks for signs of pressure at least once per shift, or more often per unit policy. Promptly notify the clinician/MD if areas concerning for pressure are identified.
- Maintain the head of the bed at 30 degrees.

(3 points)

Rationale for choices:

- The foam layers of the Mepilex dressing will provide protective cushioning to the affected area.
- The size and shape of the Mepilex Border Sacrum dressing, specifically, provides complete coverage of the sacral area. This is important in preventing exacerbation/evolution of the right sacral pressure injury, as well as the development of a pressure injury on the left side.
- Since the patient has already developed a pressure injury, interventions to prevent the development pressure injuries over other bony prominences should be implemented.

(3 points)

1 alternative primary/secondary dressing: Hydrocolloid (ex. McKesson Hydrocolloid Dressing THIN). Change

every 3 days and PRN if soiled.

(1 point)

/8 points

Scenario 8

Wound care nurse consulted to see a 56-year-old with a "sore bottom". Patient has been at your facility for 2 weeks with diagnosis of C-Diff. Today you have been consulted for a treatment plan for damaged skin.

Image courtesy of Wound, Ostomy and Continence Nurses Society image library.

Wound type: Incontinence-Associated Dermatitis, with a superimposed fungal infection.
(1 point)

Wound Nurse recommendations/orders:

- Use absorptive briefs for collection of stool.
- Change the brief every 2 to 3 hours, or as needed if observed to be soiled.
- Appropriately manage pain associated with peri-care. Techniques include guided imagery/distraction, deep breathing, and administration of PRN analgesic(s).

Wound care, with every brief change:

- Cleanse with Stryker Sage Comfort Shield Barrier cream cloths (*dimethicone-infused wipes*). Only remove soiled layers of cream.
- Apply a thick layer of Smith & Nephew Antifungal Extra Thick cream

(3 points)

Rationale for choices:

- The location of the skin breakdown to the bilateral buttocks, gluteal fold, perineum, and inner thighs (the minimum affected locations that are visible in the picture), as well as the patient's diagnosis of C-diff, are suggestive of incontinence-associated dermatitis.
- The presence of scattered satellite lesions and bright erythema indicate that a superimposed fungal infection is present related to the increased moisture.
- Important aspects of care include keeping the affected areas clean and dry; initiating antifungal therapy; and protecting the skin from contact with stool.
- Absorptive briefs serve to collect urine/stool and retain moisture off the skin.
- The Smith & Nephew cream is zinc-based and contains 2% miconazole, which can treat the fungal infection and provide barrier protection to the denuded skin.
- The Stryker Sage Comfort wipes allow for gentle cleansing while simultaneously coating the affective skin with dimethicone, a breathable silicone that provides barrier protection.
- Since this presentation of the IAD is quite severe, the patient likely experiences pain and/or discomfort with care. Implementing pain management techniques is warranted.

(3 points)
1 alternative primary/secondary dressing: Cleanse with warm, soapy water (ex. Cetaphil Gentle Skin Cleanser—mild, pH balanced soap); nystatin powder; barrier cream (ex. Triad Hydrophilic Wound Dressing). With every brief change. **(1 point)**

/8 points

Scenario 9

An 85-year-old presents to acute care with dry black eschar on left posterior heel. Cared for at home by elderly spouse, he has been bedridden for the past 6 months. The wound measures approximately 6 cm x 10cm x 0 cm. Wound edges are dry and periwound has no erythema.

Image courtesy of Wound, Ostomy and Continence Nurses Society image library.

Wound type: Pressure Injury, Unstageable (Dry stable eschar)

(1 point)

Wound Nurse recommendations/orders:

- Leave the eschar in place (no debridement)
- Keep the site clean and dry:
  - Cleanse the site and peri-wound skin with a 3M SoluPrep Quarter Dose Antiseptic Swab (chlorhexidine gluconate), daily.
- Maintain the site open to air.
- Offload pressure from both heels using a Mölnlycke Z-Flo Fluidized Positioners.

(3 points)

Rationale for choices:

- Although it's not directly stated in the prompt, it's safe to assume by the wound's presentation that the patient exhibits poor perfusion [to the lower extremities]. Dry, stable eschar that does not demonstrate signs of local infection (ex. peri-wound erythema, induration) should be left in place, especially with patients who have inadequate blood perfusion. Removing this non-viable tissue through any form of debridement would create a relatively large open area and pose the risk of infection. Daily application of chlorhexidine gluconate to the site will keep the site dry and provide antimicrobial protection.

- An important aspect of care for wounds that exhibit dry, stable eschar is pressure redistribution. An easy way to offload pressure to the heel is placing a fluidized positioner beneath the heel. Although only the left heel is affected, a positioning pillow should proactively be maintained underneath the right heel as well. General use of pressure redistribution positioners with this patient can be helpful in preventing the development of pressure injuries on other vulnerable areas, especially when considering the home setting. The patient's elderly spouse, who is the primary caregiver, may not be physically capable of frequently turning/repositioning the patient.

(3 points)
1 alternative primary/secondary dressing: Cleanse the site and peri-wound skin with a 70% isopropyl alcohol swab, daily. **(1 points)**

/8 points

Scenario 10

/8 points

The wound care nurse is consulted to see a 74-year-old patient transferred from a community hospital with an abdominal wound several days post-surgery for ischemic bowel. Wound measures approximately 10 cm x 4 cm x 3 cm with visible sutures. Wound bed dry, pink with small areas of yellow tissue (less than 10% of wound base). Periwound skin intact. WOC team consult for NPWT orders.

Image courtesy of Wound, Ostomy and Continence Nurses Society image library.

Wound type: Full-thickness incision dehiscence

(1 point)

Wound Nurse recommendations/orders:

NPWT Dressing

*VAC should be turned off prior to performing the dressing change.

*Carefully remove the previous dressing using an adhesive releaser spray.

1. Cleanse the wound with saline-soaked gauze. Thoroughly pat dry.
2. Dab the peri-wound skin with a 3M Cavilon No-Sting Barrier pad.
3. Cut a piece of black foam to fit within the wound base. Gently set in place.
4. Cut a large piece of drape and place over the site.
5. Cut a small hole within a wide part of the draped foam dressing.
6. Stick the t.r.a.c pad over the area of exposed black foam.
7. Connect the t.r.a.c pad tubing to the V.A.C. and turn on the V.A.C.
8. Confirm an appropriate seal and the correct settings on the V.A.C.

Negative Pressure Wound Therapy (NPWT):

- Setting: -125 mmHg
- Therapy: Traditional (Black Foam/Granufoam)
- V.A.C: 3M Ulta
- V.A.C Management: Nursing, wound care clinician
- Dressing changes: Twice per week (Monday/Thursday)

- Document the amount of foam pieces applied and removed with each dressing change.
- If the V.A.C. alarms:
  - Confirm that there is a proper seal.
    - If an air leak is noted/heard, first check the connection between the tubing. Alternatively, the certain areas of dressing may need to be reinforced with additional pieces of drape.
- If bright red, flowing blood is noted in the tubing and cannister, **immediately**:
  - Turn the V.A.C. off
  - Hold pressure to the wound.

o Notify MD. **(3 points)**
Rationale for choices: • Manufacturer guidelines state that a wound V.A.C dressing can stay in place for up to 72 hours, allowing for a twice weekly dressing change schedule. Removal and reapplication of these dressings can be painful/uncomfortable for the patient, so less frequent dressing changes is ideal. • NPWT is an advanced treatment that accelerates wound healing. It is indicated in cases of wound/incisional dehiscence. This therapy stimulates tissue granulation, absorbs exudate, and facilitates closure of the wound. • Bleeding is a serious complication of NPWT that warrants immediate attention and report to the MD. The V.A.C cannot differentiate between wound exudate and blood, so the bedside RN should closely monitor the quality of the drainage in the tubing and cannister. In the event of active bleeding, the therapy should be immediately stopped, and pressure should be applied to the site. **(3 points)**
1 alternative primary/secondary dressing: Hydrogel-impregnated gauze packing (ex**.** McKesson Hydrogel Amorphous Wound Dressing), Medline ABD pad to cover. Secure the ABD pad with Medline Medipore tape. Change the dressing daily and PRN if soiled. **(1 point)**

/8 points

Scenario 11

Wound care nurse consulted to see a 45-year-old with a "sore bottom". Patient has been at your facility for 2 weeks with diagnosis of C-Diff. Today you have been consulted for a treatment plan for damaged skin.

Image courtesy of Wound, Ostomy and Continence Nurses Society image library.

Wound type: Incontinence-associated dermatitis
(1 point)

Wound Nurse recommendations/orders: Barrier cream wipes to cleanse, antifungal barrier cream

- Use absorptive briefs for collection of stool.
- Change the brief every 2 to 3 hours, or as needed if observed to be soiled.

Wound care, with every brief change:

1. Cleanse with Stryker Sage Comfort Shield Barrier cream cloths. Only remove soiled layers of cream.
2. Cover with a thick layer of Triad Hydrophilic Wound Dressing.

(3 points)

Rationale for choices:

- Based on the presence of skin irritation and breakdown on the buttocks and the patient's diagnosis of a C. diff infection, the patient likely has incontinence-associated dermatitis. Important aspects of care include management of stool output and minimizing contact of stool with the affected skin through frequent cleansing and use of barrier products.
- Triad is a cream wound dressing that is designed for application on uneven surfaces, such as the buttocks, perineum, and perianal region. It contains zinc oxide, dimethicone, petrolatum, and carboxymethyl cellulose, which can help soothe and repair the denuded skin, as well as protect the skin from contact with stool. The Stryker Sage Comfort wipes allow for gentle cleansing while simultaneously coating the affective skin with dimethicone, a breathable silicone that provides barrier protection.

• Absorptive briefs serve to collect urine/stool and retain moisture off of the skin. **(3 points)**
1 alternative primary/secondary dressing: Cleansing with warm, soapy water; 'crusting' the affected skin with stoma powder (ex. Convatec Stomahesive Protective Powder) and an alcohol-free barrier film (ex. 3M Cavilon No-Sting barrier film pad), application of a zinc-based barrier product (ex. Medline Remedy Phytoplex Z-Guard Paste) **(1 point)**

/8 points

Scenario 12

A 75-year-old is admitted to acute care setting from home with pneumonia. They have a history of Raynaud Disease and Diabetes Mellitus. Has been seen at an outpatient wound clinic but is uncertain what the treatment plan is and you have no access to those medical records.
Open wound on dorsum of foot with exposed tendon. Measures approximately 8 cm x 12 cm x 0.2 cm. Wound bed 60% pink tissue and 40% yellow/black, brown tissue. Scant amount of tan drainage. Periwound intact with epibole.
Image courtesy of Wound, Ostomy and Continence Nurses Society image library.

Wound type: Diabetic Neuropathic Foot Ulcer
(1 point)

Wound Nurse recommendations/orders:

Wound care to the dorsum of the right foot, every three days and PRN if soiled/saturated:
Supplies needed: 4x4 gauze, Vashe Wound Solution, Hydrofera Blue Ready Adhesive Border Dressing, Mölnlycke Mepitel dressing

1. Cleanse the wound by applying Vashe-soaked gauze as a compress for at least 30 seconds. Gently pat dry.
2. Cut and place a piece of Mepitel into the wound bed, completely covering the exposed tendon.
3. Cover the site with the Hydrofera Blue dressing.

(3 points)

Rationale for choices:

- Hydrofera Blue Ready is a foam dressing infused with methylene blue and gentian violet. These ingredients are antimicrobial and can protect the site from infection. In addition, this dressing can flatten epibole, promoting cellular migration. It's highly absorptive of exudate and can thus maintain an appropriately moist wound bed for healing. This dressing can also promote autolytic debridement of the non-viable tissue. This dressing features silicone tape borders for gentle securement on this elderly patient's skin.
- Since there is exposed tendon in the wound bed, a contact layer, such as Mepitel, can be utilized to protect these structures while also allowing exudate to pass through and be absorbed into the foam.

(3 points)

1 alternative primary/secondary dressing: Collagen dressing (Puracol plus Ag), composite dressing to cover (ex. McKesson Adhesive Island Dressing). Change every other day and PRN if soiled.
(1 point)

/8 points