Problems of Ingestion

Tooth decay
- Most common problem affecting teeth.
- *Plaque is primary cause.*
- What is plaque? It is sticky invisible material on teeth- bacteria and sugars
- Cavity formation is the visible clinical evidence of decay

Risk Factors for Plaque and Decay
- diet high in simple sugars (refined)
- poor oral hygiene
- poor health
- familial tendency

Prevention is best treatment – frequent brushing, daily flossing

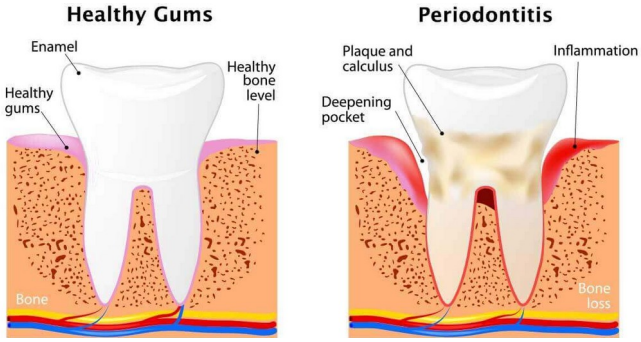

Treatment once decay has occurred
- removal of decayed tooth structures
- replacement with restorative barriers devices
- tooth extraction.

<u>Periodontal disease</u> – inflammation of tissue that supports and surrounds tooth caused by bacterial plaque
- up to 75% of adults have some degree of periodontal disease = other health problems
- most common cause of tooth loss in adults > 50 yrs.

Gingivitis: inflammation of gums causing separation from tooth surface
- pockets form, **collects bacteria**, pus forms
- gums recede, bone destruction
- tooth loosens
- First sign: **Painless bleeding of gums with normal brushing**
- Changes in gum color, edema, easy bleeding
- Prevent with brushing teeth BID and flossing
  - Flossing between teeth is #1 way to disrupt plaque formation.
- Treat with scaling and root planning – peel back gums and scrape below gum line to remove plaque

Nursing responsibility to provide and teach meticulous mouth care.

<u>Halitosis</u> – bad breath
- dental caries
- periodontal disease
- upper GI pathology

<u>Infections of Oral Cavity:</u>
stomatitis- inflammation of mouth
glossitis – inflammation of tongue
parotitis -inflammation of parotid gland

<u>S/Sx:</u>
Sore mouth, decreased appetite, foul breath, excessive salivation

Nursing interventions:

- Remove cause
- Soft bland diet
- Avoid harsh substances
- Topical or systemic antibiotics

Aphthous ulcers (canker sores):small painful ulcers on mouth & lips
Treatment: topical or systemic steroids

Herpes simplex (cold sores, fever blisters)

- *Viral* lesions appear as small vesicles or shallow ulcers on mouth, lips, edge of nose, or gums.
- Treatment: treat symptoms

Vincent's Gingivitis (trench mouth) - acute necrotizing ulcerative gingivitis caused by bacteria

- hourly mouthwashes (peroxide & water)
- antibiotics & analgesics prn

Candidiasis (yeast or thrush) - fungal infection by candida albicans
Causes

- steroid use
- antibiotics
- suppressed immune system (cancer & HIV)

Pearly white, curd-like patches in mouth which reveal raw bleeding surface when rubbed
Nursing Interventions:

- Good oral hygiene
- Bland diet
- Antifungals - Nystatin (mycostatin) suspension or troches or clotrimazole (mycelex) troches
  Teach patients to keep in contact with mouth as long as possible

Acute Sialadenitis-inflammation of salivary glands caused by inactivity of gland
Allows bacteria or virus to enter
Most common in parotid gland
Treatment: prevention

- good oral hygiene to decrease bacteria
- keep patient well hydrated
- stimulate secretions of glands (candy, chewing gum)

Calculi or Sialolithiasis : stones in salivary glands

- most common in submaxillary
- Pain with chewing
- Treat by excision

Salivary Gland Tumors: treatment depends on type and extent

Parotid gland - usually benign
Submaxillary gland - usually malignant
Pain as tumor enlarges
Spread by lymphatic system
Treatment - local excision

Oral Cancer – may occur anywhere in the mouth
Risk Factors: poor oral hygiene, tobacco & alcohol intake, chronic irritation, overexposure to wind/sun, debilitating diseases.
Leukoplakia – premalignant: hard, leathery area, yellowish or grayish white lesion; rough elevated defined borders
Hairy leukoplakia – associated with HIV, rough, hairlike projection
Speckled leukoplakia – white patches interspersed with red
Erythroplakia – velvety red patches, increased risk of malignancy
Diagnosis by biopsy

Cancer of tongue

- **poor prognosis** r/t extensive vascular & lymphatic supply
- metastasizes early to cervical lymph nodes. Usually already metastasis when diagnosed.

Kaposi's sarcoma - HIV infection related

- red, purple or blue lesion on oral mucosa

Treatment for Oral Cancer

Surgery, Radiation (pre or post surgery), Chemotherapy or Combination

- Mandibulectomy: cancer occurring on floor of mouth or near lower jaw
- Glossectomy: removal of tongue, poor prognosis
- Resections of buccal mucosa & floor of mouth

These surgeries affect chewing, swallowing, taste, & speech

- prognosis usually poor due to vascularity of area
- reconstructive surgery sometimes possible
- speech therapy is necessary
- Radical neck dissection - done to relieve pressure on trachea, esophagus, blood vessels & nerves

Complications of RND – high rate of complications

- Airway obstruction
- Hemorrhage
- Aspiration
- Infection
- Pneumothorax
- Skin flap necrosis, nerve damage

Post-op Care with RND

- Emotional support and Pre-op teaching of what to expect post-op is essential
- **Maintain airway** - Positioning to facilitate airway and drainage
- Saliva management – gentle oral suctioning
- Oral hygiene
- Pain management
- Communication
- Nutrition
- Wound Care

Nursing diagnoses for oral cancer
- alteration in body image
- impaired verbal communication
- alteration in nutrition
- altered oral mucosa

GERD - Gastroesophageal Reflux Disease
Syndrome that cause reflux of gastric & duodenal contents into esophagus = irritation & inflammation = esophagitis.

Etiology:
- Increased abdominal pressure (obesity, ascites, pregnancy)
- Incompetent LES
- Smoking
- **Hiatal hernia (**most common cause)

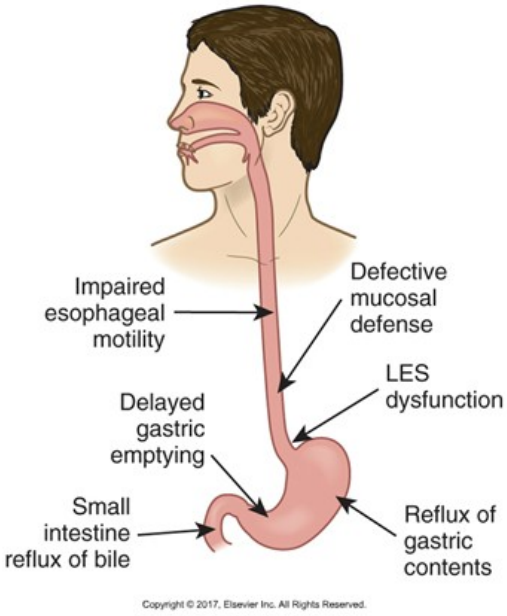

Symptoms of GERD
- Dyspepsia
- Regurgitation
- Eructation & Flatulence
- Bloating
- Dysphagia/Odynophagia
    - Risk for Aspiration!
- Chronic Cough

Medications for Treatment of GERD pg. 899 Table 41-10
- Antacids : Calcium carbonate
- H2R Blockers : Famotidine, Ranitidine
- PPI's : Pantoprazole, Omeprazole

Treatment
Small frequent meals
Don't lie down after eating
Light exercise after meals
Avoid trigger substances
Medications
Surgery

Complications
Esophageal stricture
Barrett's Esophagus (precancerous)
Esophageal erosion
Respiratory complications (aspiration)
Dental Erosion

Nursing interventions
Teaching very important!
Instruct patient to avoid anticholinergic drugs
- delay gastric emptying & increase risk of reflux

Elevate head of bed when sleeping
Remain upright for several hours after eating, avoid tight clothing

Hiatal Hernia
Defect in the diaphragm that permits part of stomach to pass through diaphragmatic opening into chest
2 types:
- sliding -the junction of the stomach and esophagus is above the diaphragm

- part of the stomach slides through the hiatal opening in the diaphragm.
- paraesophageal (rolling hernia) -the fundus or greater curvature of the stomach roll up through the diaphragm
  - forming a pocket alongside the esophagus.

Clinical manifestations -occur when LES becomes incompetent allowing reflux of gastric juices into esophagus
Most common symptom of hiatal hernia – *pyrosis (heartburn) & indigestion*
Regurgitation: return of material from stomach into esophagus or mouth
Symptoms that may indicate complications:

- Dysphagia
- Bleeding
- Severe pain & shock
- Regurgitation & aspiration
- Peptic ulcer

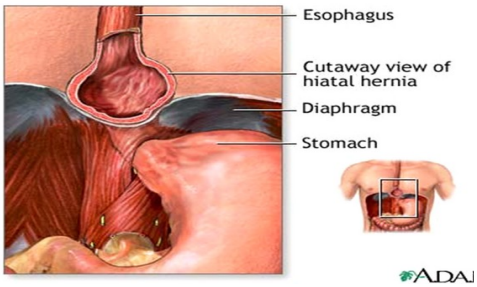

Assessment: Careful history very important
Onset, duration, location, radiation, frequency, nature, severity of pain
Relationship of S/S to ingestion & posture is significant

Treatment: Primary goal is to relieve symptoms & prevent complications

- Conservative therapy first – lifestyle changes, diet modification, medications, weight loss
- Teaching and understanding treatment plan important
- Avoidance of anti-cholinergic drugs that delay gastric emptying and increase risk of reflux
- Elevate head of bed when sleeping
- Avoid straining, tight clothing

If conservative treatment ineffective, surgery is indicated:

- Laparoscopic, trans-abdominal or trans-thoracic
- Gastroplexy - return herniated portion below diaphragm & suture in place
- Fundoplication- fundus of stomach is wrapped around esophagus & sutured to itself
- Reduction- reduces the herniated stomach back into the abd (Anti-reflux)
- Herniotomy- excision of the hernia sac
- Herniorrhaphy- closure of the hiatal defect
- Silicone prosthesis - placed around abdominal portion of esophagus to maintain placement

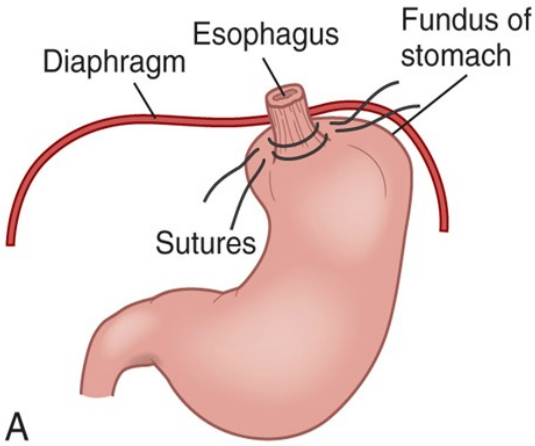

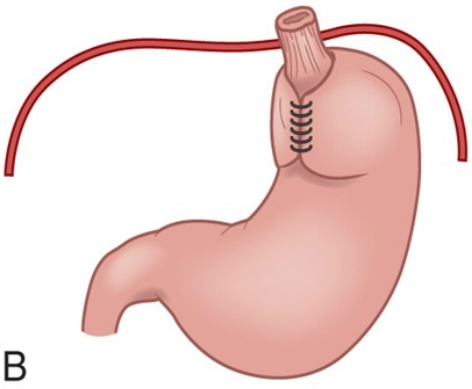

- Treat symptoms

Malignant Neoplasms of the Esophagus - Prognosis is very poor - Metastases in 80% - liver & lung
Risk Factors - Smoking, alcohol, chronic trauma from reflux, achalasia

Clinical Manifestations: Progressive dysphagia , odynophagia, pain, anorexia, weight loss, hoarseness, cough, regurgitation, SOB, increased secretions, pneumonitis
Tumor eventually erodes into other structures
Cause of death: malnutrition, GI hemorrhage, aspiration pneumonia

Treatment: depends on tumor location & extent of involvement
- Surgery, Radiation, Chemotherapy, Laser, Combination of Modalities
- Radiation/chemo pre-op to decrease size of tumor so better surgical result
- Surgical repair is aimed at enabling patient to continue to eat by mouth

Surgical Repairs:
Esophagectomy - remove all or part of esophagus. Replace resected part with dacron graft
Esophagogastrostomy- resection part of esophagus & anastomose to remaining portion to stomach
Esophagoenterostomy - resection of portion of esophagus & replace with segment of colon
When these are not possible, gastrostomy is done for maintenance of nutrition

Nursing interventions
- maintain nutrition
- good oral care
- psychological/emotional support
- palliative, supportive care
- Teaching
- Care of gastrostomy tube
- Resources in community

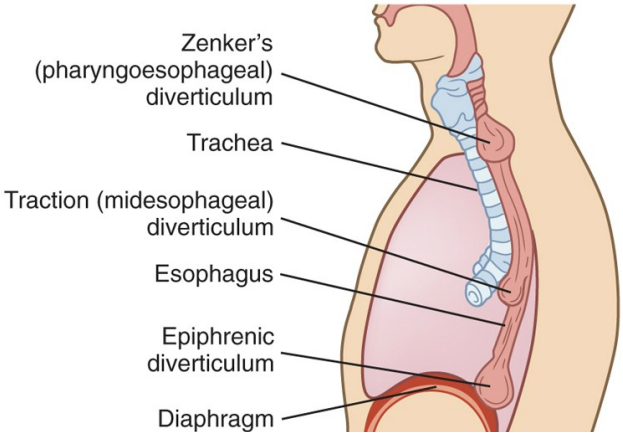

Esophageal Diverticula
Sac-like outpouching of mucosal wall of esophagus
Obstructs passage of food, creates collection of food in pocket/pouch.
Clinical manifestations: dysphagia, regurgitation, halitosis (decomposition of food in pouch), poor nutrition (Weight loss/malnutrition), chronic cough, aspiration
Zenker diverticulum occurs in ppl over 60, and results in a classic presentation of symptoms.
Medical treatment: primary dietary with soft, pureed or liquid foods
Surgical treatment: only if patient is symptomatic

Nursing interventions
nutritional support
mouth care
Monitor for Complications: aspiration, malnutrition, perforation,

Esophageal Trauma & Strictures: inflammatory, traumatic, congenital
Causes: GERD #1, esophagitis, radiation therapy, corrosive burns (due to ingestion of strong acids), continuous severe vomiting

Treatment: remove cause if possible; may need surgical dilation of esophagus or surgical excision & anastomosis

Achalasia - double defect in esophageal functioning

- Aperistalsis: absent peristalsis in lower 2/3 of esophagus (Decreased motility)
- LES pressure increases: impedes flow of liquids & foods into stomach
- Massively dilated esophagus

Clinical manifestations - dysphagia most common, regurgitation
Complications: aspiration pneumonia, airway obstruction, cough/dyspnea
Chest pain: due to pressure on heart vessels
Halitosis from retained foods
Malnutrition/weight loss

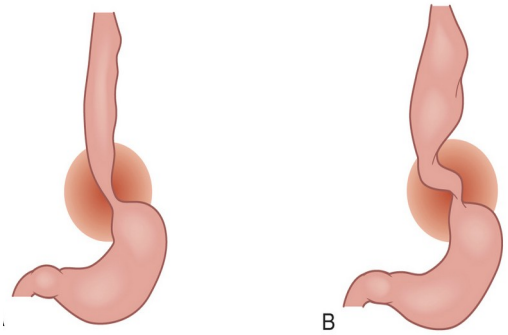

Diagnosis:

- Esophagram
- Barium swallow
- Endoscopy

Treatment: Medical
soft, pureed food
chew well, eat slowly, HOB up
drugs used to decrease LES pressure: calcium channel blockers, nitrates, Botox

Surgical (Endoscopic)
balloon dilatation of esophagus
Esophagomyotomy: cut muscle to open LES sphincter

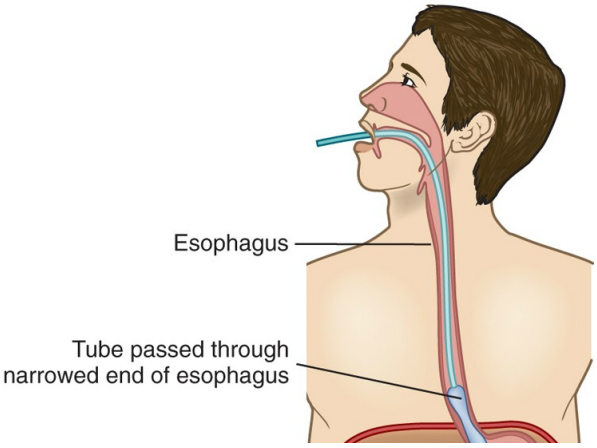

Esophageal Varices
Tortuous dilated blood vessels in the esophagus

- Results from liver damage/portal HTN

Foodborne Illness (Food poisoning -Table 41-24) pg. 820
Caused by intake of contaminated foods
2 manifestations of food poisoning:

- Acute gastroenteritis from bacteria

(N/V, diarrhea, abd cramps, fever, chills)

- Neurological symptoms - from botulism

Staphylococcal – meat, bakery, milk, *skin and respiratory tract of food handlers* (Most common)
Clostridial – meat and poultry dish cooked at low temperatures, re-warmed meat dishes, improperly canned vegetables
Salmonella – improperly cooked poultry, pork, beef, lamb, and eggs
E. coli – contaminated beef. Bloody stools, hemolytic uremic syndrome
Botulism – improperly canned or preserved food, *home preserved vegetables (most common)*, preserved fruits and fish.
Central nervous system symptoms (HA, dizziness, muscle incoordination, weakness, inability to talk or swallow, paralysis, death.

Nursing Care - health teaching to prevent recurrence

- Hand hygiene
- Cleanliness
- Correct food preparation
- Adequate cooking
- Proper refrigeration

Treatment:
correct fluid & electrolytes imbalances
assessment & care for neurologic symptoms