APPLES TO ULCERS:
Tips for staging pressure ulcers

by Patricia Turner, BSN, RN, CWOCN, CWS

How common is it in your facility or in your experience, that despite numerous references, in-services and reviews, some clinicians still struggle with the pressure ulcer staging system? **Are the "fruits" of your labor paying off** in the educational plan for yourself or for your staff?

As adults, our learning styles and patterns tend to be more visual in nature, and adult learning is often solidified by equating concepts to past experiences or ideas that are familiar to us.[1] Malcolm L. Knowles identified six principles of adult learners. Adults learners are internally motivated and self-directed, and they bring life experiences and knowledge to learning. Adult learners are also goal- and relevancy-oriented, as well as practical, and they like to be respected.[1]

Since adults bring life experiences and prior knowledge to learning, it is helpful when educators can provide an opportunity to use that existing foundation of knowledge and apply it to their new learning experiences. This reflective learning can also assist the adult learner to examine existing biases or habits based on life eperiences and "move them toward a new understanding of information presented."[2] This article presents a simple analogy anyone can use to help themselves, or staff, really understand the differences between the stages of pressure ulcers.

Pressure ulcer staging and CMS

Pressure ulcer staging became particularly important with the passing of the Deficit Reduction Act (DRA). Effective October 1, 2008, payment for pressure ulcers and a list of other high-cost, highly preventable conditions would not be covered if they developed during a patient's hospital stay, coining the phrase, hospital-acquired conditions (HAC). Policy set by the Centers for Medicare and Medicaid Services (CMS) states that the physician or other licensed provider must complete a skin assessment when the patient is admitted to the hospital. This skin assessment must document whether the patient does or does not have pressure ulcers or other skin problems. This documentation is referred to as "present on admission," or POA. POA indicates that the problem was present when the patient arrived at the facility.

Clinicians also assess the patient on admission to determine the risk for developing pressure ulcers. Some patients are at greater risk of pressure ulcers than others for a variety of reasons. Over the course of the patient's hospital stay, frequent, often daily, skin inspections should be conducted. Skin inspections should be performed at every shift in critical care areas such as the intensive care unit (ICU). Overall skin assessments should be performed at regular intervals based on the facility's protocols.

The concept of "hospital-acquired" and "present on admission" brought to the forefront the importance of accurate assessment and staging because of the financial implications when pressure ulcers are not accurately staged and assessed on admission. So how can we, as clinicians, help ourselves and our staff get this right?

Identifying pressure ulcers

Let's begin with the definition of a pressure ulcer according to the National Pressure Ulcer Advisory Panel (NPUAP): "A pressure ulcer is localized injury to the skin and/or underlying tissue usually over a bony prominence, as a result of pressure, or pressure in combination with shear. A number of contributing or confounding factors are also associated with pressure ulcers; the significance of these factors is yet to be elucidated."[2]

Pressure ulcers are described using a staging system. The stages are based on identifying and knowing the levels of skin and tissue involved in each wound. By knowing just how deep each layer goes, we can more easily identify the correct stage. We also need to remember that there are some stages of pressure ulcers where the patient's skin is still intact. These pressure ulcers have certain discolorations associated with them. Now, let's equate the concept of "layers" and "colors" to something we come across maybe almost every day … an apple.

The old saying is "An apple a day keeps the doctor away." Well, how about, "An apple a day can help take pressure ulcer staging confusion away." Let's compare that apple to the NPUAP pressure ulcer staging descriptions using the apple images on the chart that follows.[2]

If Pressure Ulcers Were Apples

STAGE I

Intact skin with non-blanchable redness of a localized area usually over a bony prominence. Darkly pigmented skin may not have visible blanching; its color may differ from the surrounding area.

Further description: The area may be painful, firm, soft, warmer or cooler as compared to adjacent tissue. Stage I may be difficult to detect in individuals with dark skin tones. May indicate "at risk" persons (a heralding sign of risk).

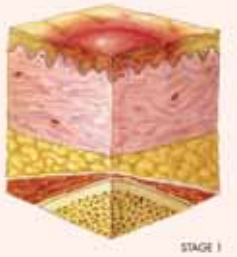

STAGE II

Partial thickness loss of dermis presenting as a shallow open ulcer with a red pink wound bed, without slough. May also present as an intact or open/ruptured serum-filled blister.

Further description: Presents as a shiny or dry shallow ulcer without slough or bruising.* This stage should NOT be used to describe skin tears, tape burns, perineal dermatitis, maceration or excoriation. *Bruising indicates suspected deep tissue injury.

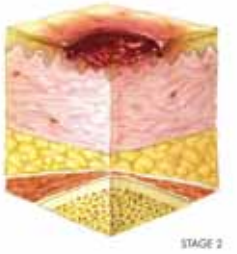

STAGE III

Full thickness tissue loss. Subcutaneous fat may be visible but bone, tendon or muscle are not exposed. Slough may be present but it does not obscure the depth of tissue loss. May include undermining and tunneling.

Further description: The depth of a Stage III pressure ulcer varies by anatomical location. The bridge of the nose, ear, occiput and malleolus do not have subcutaneous tissue, so Stage III ulcers in these areas can be shallow. In contrast, areas of significant adiposity can develop extremely deep Stage III pressure ulcers. Bone/tendon is not visible or directly palpable.

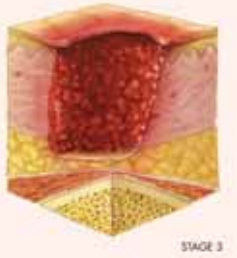

STAGE IV

Full thickness tissue loss with exposed bone, tendon or muscle. Slough or eschar may be present on some parts of the wound bed. Often includes undermining and tunneling.

Further description: The depth of a Stage IV pressure ulcer varies by anatomical location. The bridge of the nose, ear, occiput and malleolus do not have subcutaneous tissue, so these ulcers can be shallow. Stage IV ulcers can extend into muscle and/or supporting structures (e.g., fascia, tendon or joint capsule) making osteomyelitis possible. Exposed bone/tendon is visible or directly palpable.

Suspected Deep Tissue Injury (sDTI)

Purple or maroon localized area of discolored intact skin or blood-filled blister due to damage of underlying soft tissue from pressure and/or shear. The area may be preceded by tissue that is painful, firm, mushy, boggy, warmer or cooler as compared to adjacent tissue.

Further description: Deep tissue injury may be difficult to detect in individuals with dark skin tones. Evolution may include a thin blister over a dark wound bed. The wound may further evolve and become covered by thin eschar. Evolution may be rapid, exposing additional layers of tissue even with optimal treatment.

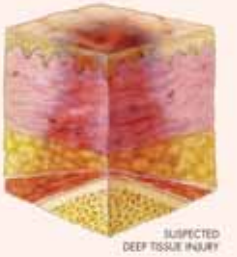

Unstageable

Full thickness tissue loss in which the base of the ulcer is covered by slough (yellow, tan, gray, green or brown) and/or eschar (tan, brown or black) in the wound bed.

Further description: Until enough slough and/or eschar is removed to expose the base of the wound, the true depth, and therefore stage, cannot be determined. Stable (dry, adherent, intact without erythema or fluctuance) eschar on the heels serves as "the body's natural (biological) cover" and should not be removed.

Visit www.medlineuniversity.com and login or create an account. Choose your course and take the test to receive 1 FREE CE credit. Course is approved for continuing education by the Florida Board of Nursing and the California Board of Registered Nursing.

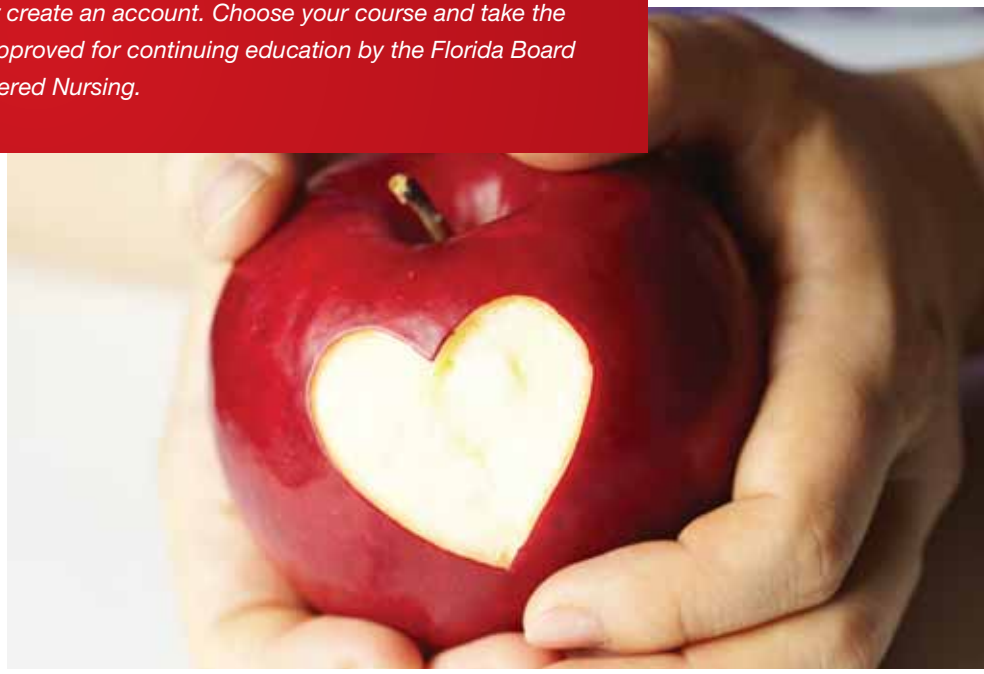

Stage I

Stage I pressure ulcers are identified as "non-blanchable erythema of intact skin." Think of the normal state of a delicious red apple. The red color is something that will not go away. We can't "touch" a red apple and make the color be less vibrant or make the color go away. Just like a Stage I pressure ulcer, we can't take away the redness simply by touching it. It will not blanch because there are already signs of capillary compromise within the layers of the skin.

Stage II

These pressure ulcers are defined as partial thickness loss of the dermis presenting as a shallow open ulcer. The key here is that there is not a lot of depth to these wounds and that it is right at the layer of the dermis, the inner most layer of skin. Think of apple being peeled. Just the layer of outside "skin" is being removed or impacted when we carefully peel an apple. The same superficial layer has been removed or compromised in a Stage II pressure ulcer. These wounds will not have slough, and they will be superficial in nature.

Stage III

Pressure ulcers at this stage are full thickness. They involve the underlying subcutaneous tissue. All layers of skin are missing and the wound has greater depth. Think of what your apple looks like when you take a nice healthy bite out of it... and the skin is gone, you are into the juicy "meat" of the apple. A Stage III pressure ulcer is similar. It's migrated into the subcutaneous tissue and there is usually depth to these wounds.

Stage IV

These pressure ulcers are also full thickness wounds, but the difference from Stage III is that there is underlying structure involved. If you were to bite too far into your apple, you would get to the core…to the inner structure of that apple. This is what happens in a Stage IV pressure ulcer. You are down to the inner structure under that subcutaneous layer.

Suspected Deep Tissue Injury (sDTI)

What if your apple had a purple or dark spot on it. You wouldn't know just how "bad" that apple was underneath that spot. The skin looks intact, but you know that part of that apple is bad and is not good to eat. That's what happens with a suspected deep tissue injury. Just like an apple with a soft discolored spot, a deep tissue injury presents with skin intact, but with a top layer of maroon or purple localized discoloration, letting you know that there is tissue damage underneath even though the skin is intact.

Unstageable

Unstageable pressure ulcers are completely covered with eschar or slough, so that the depth of the base of the wound cannot be visualized. Think of a caramel-covered apple. That thick, tannish brown caramel completely coats the apple. Because of that caramel, we don't really know the state of the apple underneath. Just like an unstageable pressure ulcer, because of the slough or eschar obstructing the base of the wound, we don't know how deep it is, and therefore, we cannot stage it, and we consider it unstageable.

Although this analogy and comparison is relatively easy, hopefully it will clarify in a simple way, some of the confusion that can be associated with the pressure ulcer stages. You may not ever think of an apple the same way again!

Sources

1. Richardson, V. The diverse learning needs of students. In: Billings DM & Halstead JA (eds.) Teaching in Nursing. 2nd ed. St. Louis, MO: Elsevier; 2005.
2. NPUAP Pressure Ulcer Staging Classification 2007. Available at: http://www.npuap.org/resources/educational-and-clinical-resources/npuap-pressure-ulcer-stagescategories/. Accessed August 16, 2013.